

Table
Valve Lesions in 748 Patients With Atrial Fibrillation but Without Prostheses

	No. (%)
No lesion	5 (0.67)
Any grade VS or VR \geq grade II	587 (78.5)
Any grade VS or VR \geq grade III	472 (63.1)
Any grade MS	158 (21.1)
Moderate or severe MS	93 (12.4)

MS, mitral valve stenosis; VR, regurgitation of any valve; VS, stenosis of any valve.

2013, echocardiograms were recorded for 748 patients with atrial fibrillation but without a valve prosthesis, and with a CHADS₂ score of 1 or more. The patients with valve lesions are shown in the Table.

In terms of their valve lesions, 655 patients (87.6%) would correspond to the clinical profile of ARISTOTLE⁴ and ENGAGE AF-TIMI 48 trials.⁵ Between 590 and 655 (78.9% and 87.6%) would correspond to the ROCKET profile.³ It is more difficult to determine how many would correspond to the RE-LY profile² and how many would have NVAf. This would depend on the threshold for NVAf. If NVAf requires “hemodynamically relevant valve disease”, between 161 and 276 patients could be included (21.5%–36.9%). These notable differences highlight the weakness of the term NVAf when selecting patients for treatment with NOACs.

These data cannot be extrapolated to the general population because the patients were referred for echocardiography. Nevertheless, they may be representative of a large proportion of patients with different types of valve lesions and atrial fibrillation.

The authors of the ARISTOTLE trial reported that more than a quarter of the patients in the study had valve lesions that could be considered significant.⁶ In these patients, the benefit of apixaban was similar to that in patients without valve lesions. This finding may dissipate doubts about the risk of using NOACs, or at least apixaban, in patients with valve lesions other than mitral stenosis. In the ROCKET trial, 14% of the patients were considered to have significant valve lesions.

The clinical trials show that NOACs, or at least factor Xa antagonists, can be used in patients with atrial fibrillation who do not have mechanical prostheses^{2–5} or significant mitral valve stenosis,^{3–6} although they may have other valve lesions, whether or not they are significant. This point is essential, as atrial fibrillation is the most frequent sustained arrhythmia, while mitral valve stenosis is becoming less frequent. The term NVAf does not seem appropriate as an umbrella term for patients who may benefit from NOACs. Not only is this term not representative, but it is also not defined in the guidelines and may lead to inappropriate

and uneven clinical management in the indications for anti-coagulation. We are therefore of the opinion that this poorly defined term should not be used in this context.

CONFLICTS OF INTEREST

A. García Lledó has provided scientific advice to Bristol-Myers and Bayer and has given presentations and classes in courses sponsored by Pfizer and Boehringer.

Alberto García-Lledó,^{a,b,*} José-Luis Moya Mur,^c
Javier Balaguer Recena,^{b,d} Eva Díaz Caraballo,^d
Javier García Pérez-Velasco,^a and Azucena Sanz Barrio^{a,b}

^aServicio de Cardiología, Hospital Universitario Príncipe de Asturias, Alcalá de Henares, Madrid, Spain

^bDepartamento de Medicina, Universidad de Alcalá, Alcalá de Henares, Madrid, Spain

^cServicio de Cardiología, Hospital Universitario Ramón y Cajal, Madrid, Spain

^dServicio de Cardiología, Hospital Universitario de Guadalajara, Guadalajara, Spain

* Corresponding author:

E-mail address: alberto.garcia-lledo@uah.es (A. García-Lledó).

Available online 27 June 2014

REFERENCES

1. Camm AJ, Lip GY, De Caterina R, Savelieva I, Atar D, Hohnloser SH, et al. 2012 Focused update of the ESC Guidelines for the management of atrial fibrillation. *Eur Heart J*. 2012;33:2719–47.
2. Connolly SJ, Ezekowitz MD, Yusuf S, Eikelboom J, Oldgren J, Parekh A, et al. Dabigatran versus warfarin in patients with atrial fibrillation. *N Engl J Med*. 2009;361:1139–51.
3. Patel MR, Mahaffey KW, Garg J, Pan G, Singer DE, Hacke W, et al. Rivaroxaban versus warfarin in nonvalvular atrial fibrillation. *N Engl J Med*. 2011;365:883–91.
4. Granger CB, Alexander JH, McMurray JJ, Lopes RD, Hylek EM, Hanna M, et al. Apixaban versus warfarin in patients with atrial fibrillation. *N Engl J Med*. 2011;365:981–92.
5. Giugliano RP, Ruff CT, Braunwald E, Murphy SA, Wiviott SD, Halperin JL, et al. Edoxaban versus warfarin in patients with atrial fibrillation. *N Engl J Med*. 2013;369:2093–104.
6. Avezum A, Lopes RD, Schulte PJ, Lanus F, Hanna M, Pais P, et al. Apixaban versus warfarin in patients with atrial fibrillation and valvular heart disease: findings from the ARISTOTLE study. *Eur Heart J*. 2013;34 Suppl 1:809.

<http://dx.doi.org/10.1016/j.rec.2014.03.009>

Percutaneous Closure of Baffle Leaks in Patients With Atrial Switch Operation for D-Transposition of the Great Arteries



Cierre percutáneo de comunicaciones interauriculares en pacientes con cirugía de switch auricular para la D-transposición de grandes arterias

To the Editor,

The atrial switch procedure (Senning or Mustard technique) was the surgical standard of care for patients with D-transposition of the great arteries during the 1970s and 1980s. This intervention

achieved redirection of systemic venous blood flow to the left ventricle (subpulmonary) and of the pulmonary venous flow to the right ventricle (systemic) by means of an atrial baffle. Interest in this topic is mainly due to the large number of patients currently being followed up after these interventions. The long-term complications of the atrial switch procedure are mainly related to right ventricular dysfunction, atrial bradyarrhythmias and tachyarrhythmias, pulmonary hypertension and baffle problems (leaks and/or obstructions).^{1,2} Baffle leaks have traditionally been surgically treated.^{3,4}

The main aim of our report is to describe the percutaneous approach for the treatment of baffle leaks and its clinical medium-term results in a tertiary hospital. From 2005 to 2012,

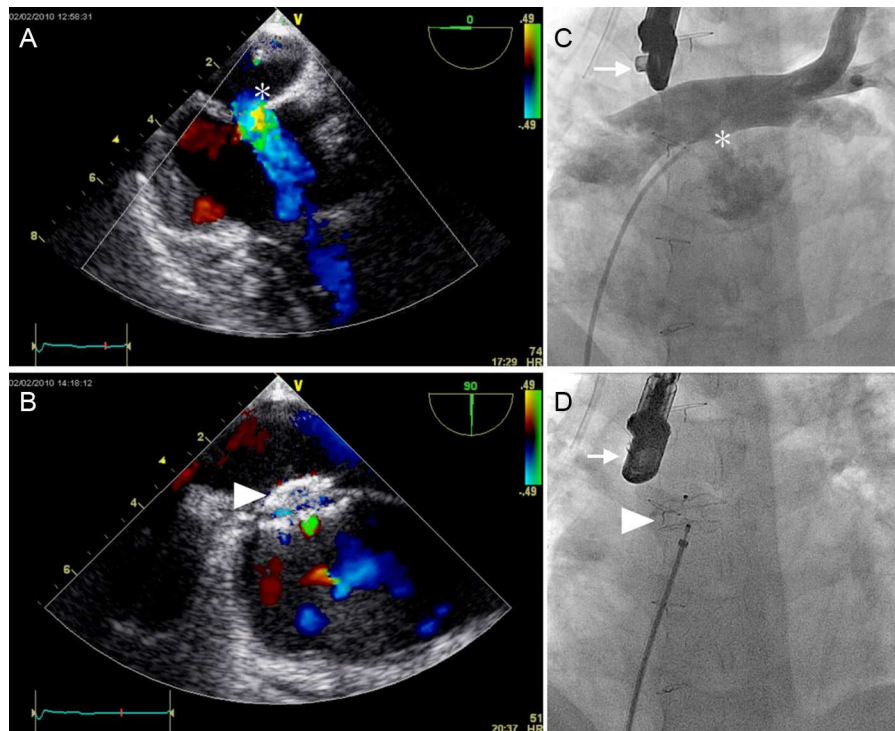


Figure. A: Intraprocedural transesophageal echocardiography with an intense Doppler signal showing a predominantly left-to-right shunt through the baffle leak (asterisk). B: Final result after closure with the occluding device (arrowhead), a minimal intradevice residual shunt is seen. C: Angiographic intraprocedural imaging (arrow, transesophageal echocardiography); posteroanterior angiography showing a pig-tail catheter placed in the pulmonary vein baffle from the inferior vena cava and through the baffle leak (asterisk). Angiography shows an important left-to-right shunt. D: Final placement of the occluding device (arrowhead) (ADO Amplatzer[®]) in the same patient.

percutaneous closure of 9 baffle leaks was indicated in 8 patients. All patients gave informed consent. Our study had *a priori* approval by the ethics committee.

All procedures were performed under general anesthesia, and closure was guided by transesophageal echocardiography and biplane fluoroscopy. Vascular accesses were as follows: femoral vein and artery in 6 patients, femoral artery only in 1 patient, and humeral artery and vein in another patient. All patients were heparinized. Hemodynamic study and angiography were performed. Data of the leak size was obtained with echocardiography and balloon sizing using the “stop-flow technique”, and the size and type of the device used were selected on a case by case basis by evaluating all the measurements.

The Wilcoxon test was used for nonparametric tests of paired samples when analyzing the pre- and postprocedural data, and the statistical analysis was performed in SPSS for Windows v. 13.

The Figure shows the angiographic and echocardiographic findings before and after closure. The Table shows a summary of the baseline data and procedural details. Eight patients underwent catheterization. The patients with pulmonary overcirculation were in New York Heart Association (NYHA) class I-II with a mean QP/QS of 2.9 (range, 1.6-6) and echocardiographic dilation of the subpulmonary ventricle. Cyanotic patients had a mean resting saturation of 84% (range, 73%-92%) with erythrocythemia (mean hemoglobin, 17.8 g/dL [range, 14.4 g/dL-20 g/dL]). The mean age at catheterization was 30 years (range, 22-37). The leaks were mainly located in the connection of the 2 limbs of the venous baffle.

Six of the 8 procedures (75%) were successful. Seven Amplatzer-ASO[®] and 1 Amplatzer-ADO[®] (St Jude Medical, St Paul, Minnesota, USA) were placed in 7 patients.

Failures: In patient 5, it was impossible to achieve a correct position of the device. Complications: Patient 7 had a large baffle leak closed with a 34-mm device after a careful stability check. The 24-hour echocardiographic follow-up showed device migration to the left atria and percutaneous retrieval was successful.

The median follow-up of the patients after the procedure was 43 months (ranging from 12-94 months). All patients who were treated percutaneously were in NYHA class I after the procedure. In the 2 cyanotic patients, desaturation was immediately corrected (mean postprocedural oxygen saturation (Sat O₂) of 97%; range, 96%-98%) and correction of erythrocythemia was also observed (mean postprocedural Hb, 13.3 g/dL). No recurrence of the baffle leak has been seen in the follow-up.

Several case reports and some series have described percutaneous techniques to relieve obstruction of venous baffles and closure of baffle leaks,⁵ the largest being that of Daehnert et al⁶ with 14 patients treated with stents and ASO devices. In contrast with other series, our report shows patients treated because of overcirculation. Aggressive treatment in these patients seems reasonable because they can develop pulmonary hypertension.

The limitations of our report are related to its retrospective design and the lack of control groups.

Percutaneous closure of baffle leaks after an atrial switch procedure for D-transposition of the great arteries is feasible and has a high success rate. It produces immediate clinical improvement, but the anatomy of the leaks makes the procedure complex.

Table
Clinical and Procedural Data (n = 8)

	Patient							
	1	2	3	4	5	6	7	8
Sex	F	F	M	M	M	M	F	M
Age, y	33	37	32	22	29	33	29	23
Previous surgery	Mustard	Mustard	Sening	Sening	Sening	Mustard	Mustard	Sening
Indication	Overcirculation	Cyanosis	Cyanosis	Overcirculation	Overcirculation	Overcirculation	Cyanosis	Overcirculation
Procedure results	Success	Success	Success	Success	Failed	Success	Failed (migration)	Success
NYHA status pre	1	2	3	2	1	2	3	1
NYHA status post	1	1	1	1	1	1	2	1
Baseline Sat O ₂	98	92	86	92	94	98	73	97
Post-Procedure Sat O ₂	98	97	97	96	96	98	96	98
PAP, s/d/m	21/9/15	18/8/13	23/6/14	50/29/36	27/13/17	22/11/16	18/8/11	25/4/11
TEE sizing, mm	15	11	9	10	26	23	34	N/A
Balloon sizing, mm	15	14	9	No	26	24	34	15
QP/QS	2	1.14	0.69	1.6	1.8	6	N/A	3
Device	ASO 13 + ADO II 6	ASO 12	ASO 9	ASO 11	No device	ASO 28	ASO 34	ASO 18
Fluoroscopy time, min	32	29	49	15	12	85	87	58
Fluoroscopy dose, Gy/cm ²	138	128	253	160	1178	1134	5196	3480
Contrast volume, mL	250	240	100	110	385	310	291	300
Procedure time, min	167	125	211	145	395	356	408	356

F, female; M, male; NYHA, New York Heart Association; Sat O₂, arterial oxygen saturation; PAP, pulmonary artery pressure (systolic, diastolic, mean).

Our data suggest that percutaneous closure of baffles is a safe procedure and the medium-term follow-up demonstrates no recurrences of the leaks and good clinical status.

Andreu Porta-Sánchez,^{a,*} Gerard Martí-Aguasca,^b
 Maria Antònia Pijuan-Doménech,^c Laura Dos-Subirà,^c
 Maria-Teresa Subirana-Doménech,^d and Jaume Casaldàliga-Ferrer^c

^a*Servei de Cardiologia, Hospital Universitari de la Vall d'Hebron, Vall d'Hebron Institute of Research (VHIR), Barcelona, Spain*

^b*Servei de Cardiologia, Hospital Universitari de la Vall d'Hebron, Barcelona, Spain*

^c*Unitat de Cardiopaties Congènites de l'Adolescent i de l'Adult (UCCAA), Hospital Universitari de la Vall d'Hebron, Barcelona, Spain*

^d*Unitat de Cardiopaties Congènites de l'Adolescent i de l'Adult (UCCAA), Hospital Universitari de la Santa Creu i Sant Pau, Barcelona, Spain*

* Corresponding author:

E-mail address: anporta@vhebron.net (A. Porta-Sánchez).

Available online 23 June 2014

REFERENCES

1. Gelatt M, Hamilton RM, McCrindle BW, Connelly M, Davis A, Harris L, et al. Arrhythmia and mortality after the mustard procedure: A 30-year single-center experience. *J Am Coll Cardiol.* 1997;29:194-201.
2. Dos L, Teruel L, Ferreira IJ, Rodriguez-Larrea J, Miro L, Girona J, et al. Late outcome of senning and mustard procedures for correction of transposition of the great arteries. *Heart.* 2005;91:652-6.
3. Tobler D, Williams WG, Jegatheeswaran A, Van Arsdell GS, McCrindle BW, Greutmann M, et al. Cardiac outcomes in young adult survivors of the arterial switch operation for transposition of the great arteries. *J Am Coll Cardiol.* 2010;56:58-64.
4. Horer J, Karl E, Theodoratou G, Schreiber C, Cleuziou J, Prodan Z, et al. Incidence and results of reoperations following the Senning operation: 27 years of follow-up in 314 patients at a single center. *Eur J Cardiothorac Surg.* 2008;33:1061-7. discussion 1067-8.
5. Hill KD, Fleming G, Curt Fudge J, Albers EL, Doyle TP, Rhodes JF. Percutaneous interventions in high-risk patients following mustard repair of transposition of the great arteries. *Catheter Cardiovasc Interv.* 2012;80:905-14.
6. Daehnert I, Hennig B, Wiener M, Rotzsch C. Interventions in leaks and obstructions of the interatrial baffle late after mustard and senning correction for transposition of the great arteries. *Catheter Cardiovasc Interv.* 2005;66:400-7.

<http://dx.doi.org/10.1016/j.rec.2014.03.015>

Delayed Positive Response to a Flecainide Test in a Patient With Suspected Brugada Syndrome: a Worrisome Finding



Respuesta positiva diferida al test de flecainida en paciente con sospecha de síndrome de Brugada: un hallazgo preocupante

To the Editor,

Drug challenge tests used to elicit a Brugada electrocardiographic pattern (B-ECG) are fundamental in the diagnosis of this syndrome. Sodium channel blockers used in the treatment of cardiac arrhythmias, mainly ajmaline and flecainide, are the agents most widely employed because of their demonstrated efficacy and safety in unmasking the B-ECG. The results of the test are considered positive if, during infusion of the drug, a nondiagnostic B-ECG (type 2 or 3) becomes a diagnostic B-ECG (type 1 or coved type), which is characterized by ST segment elevation ≥ 2 mm followed by a negative T wave in more than 1 precordial lead (V_1 - V_3). These tests are usually performed in an outpatient setting and, once the electrocardiogram has become normalized, the patient is discharged after a short monitoring period. There is no information in the literature concerning the incidence and implications of late positive responses following an initially negative flecainide test (FT).

We report the case of a 32-year-old man who was asymptomatic and had no family history of sudden cardiac death. He was referred to our hospital to undergo a FT when he was found to have a type 3 B-ECG in a routine electrocardiogram. The results of a physical examination and a battery of analyses were normal. The existence of structural heart disease was ruled out by echocardiography. A baseline electrocardiogram performed prior to the FT revealed no abnormalities. Following flecainide infusion (2 mg/kg body weight for 10 minutes), the patient had a significantly prolonged QRS interval, but met none of the diagnostic criteria for B-ECG (with precordial leads V_1 and V_2 placed both in the fourth and in

the third intercostal space). Although the widening of the QRS complex did not meet the criteria for interrupting the test (QRS $> 130\%$ of baseline value), he was admitted to the hospital for electrocardiographic monitoring until the intraventricular conduction disturbance had been corrected. Two hours after completing the administration of flecainide, we detected coved ST-segment elevation in the right precordial leads, a finding that met the criteria for type 1 B-ECG (Figure). Twenty-four hours later, the electrocardiogram had returned to normal and the patient was discharged home.

This report describes a case of a late positive response to FT after an initial negative result. It was discovered incidentally because the patient underwent a longer than usual period of electrocardiographic monitoring.

Among the antiarrhythmic sodium channel blockers currently available, ajmaline has been found to exhibit the greatest efficacy in unmasking B-ECG. Hong et al¹ evaluated ajmaline in a cohort of 147 carriers of mutations in the *SCN5A* gene. They reported a diagnostic sensitivity and specificity of 80% and 94%, respectively, as well as a positive predictive value of 93% and negative predictive value of 83% for the syndrome. Meregalli et al² analyzed the effect of flecainide in 110 carriers of the same gene; they obtained a sensitivity of 77%, specificity of 80%, positive predictive value of 96%, and negative predictive value of 36%. The 2 drugs were compared in a study by Wolpert et al³ involving 22 probands with a genetic diagnosis of Brugada syndrome; ajmaline had a higher detection capacity (22 of 22) than flecainide (15 of 22) and a more marked ST-segment elevation. The reproducibility of FT has also been controversial. Gasparini et al⁴ found a reproducibility of 100%. However, there are reports of cases in which the test was negative, although the initial response had been positive.⁵

Despite the superiority of ajmaline, the fact that in many countries it is not available has made flecainide the drug of choice in most electrophysiology laboratories. The differences between the 2 drugs have been related to flecainide's greater inhibition of the transient outward potassium current³ (I_{to}). This reduces the ionic imbalance between the positive inward and outward