

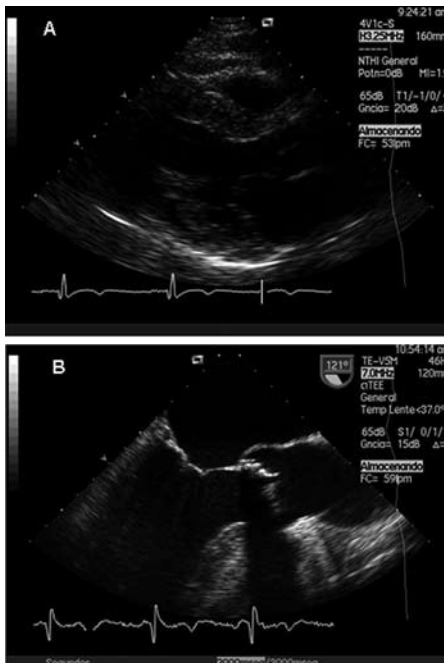Figure 1.

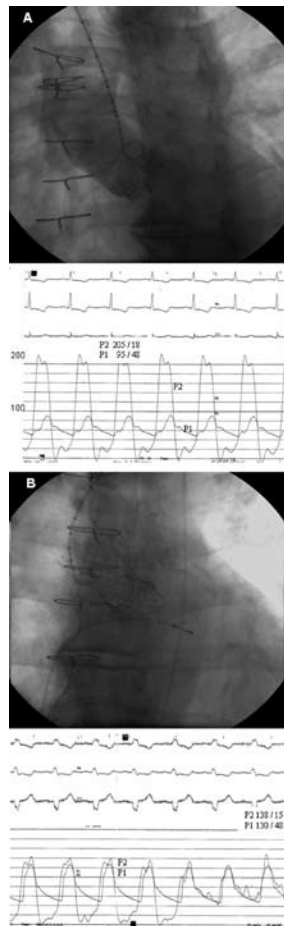


Figure 2.

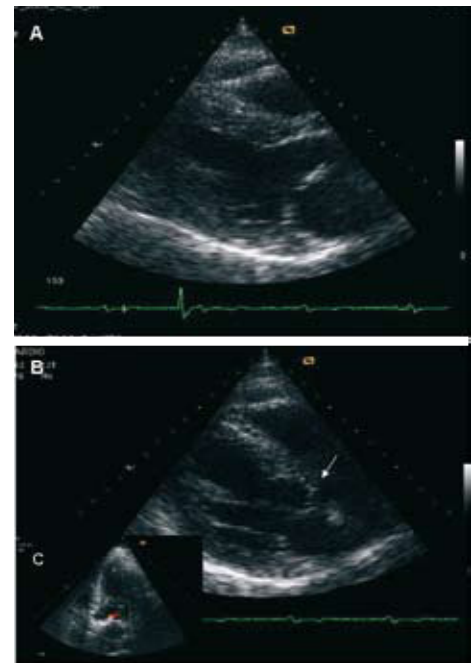


Figure 3.

Percutaneous Aortic CoreValve Prosthesis in a Degenerated Bioprosthesis

A 60-year-old man with hepatic cirrhosis and portal hypertension, who underwent aortic valve replacement (Carpentier-Edwards bioprosthesis) in 2005 to treat aortic stenosis, presented with symptoms of heart failure. Transthoracic and transesophageal echocardiography (Figure 1A and B) and angiography (Figure 2A) showed prosthesis dysfunction due to stenosis: maximum gradient, 110 mm Hg; mean gradient, 75 mm Hg.

Because of the surgical risk of a second thoracotomy, a logistic EuroSCORE of 7.14%, and associated comorbidity, a repeat operation was ruled out, and treatment by percutaneous implantation of a CoreValve aortic prosthesis was decided. The operation was successfully completed using local anesthesia and light sedation. A 29-mm CoreValve aortic prosthesis was implanted without complications through a femoral artery approach. The gradient peak disappeared (Figure 2B) and follow-up echocardiography showed perfect valve functioning (Figure 3A and B) with

minimal regurgitation (Figure 3C). The patient was discharged 6 days after the procedure, with improved symptoms and a reduction of NT-ProBNP concentration from 2561.3 to 187.6 pg/mL. At 8 months of follow-up, the patient was asymptomatic.

We report the first case of successful treatment of severe stenosis of a degenerated aortic bioprosthesis using the percutaneous CoreValve prosthesis. This case illustrates the viability and safety of the procedure. Repeat surgery is associated with high morbidity and mortality rates; hence, percutaneous treatment for prosthesis dysfunction, whether for regurgitation or stenosis, may be a therapeutic alternative for a subgroup of patients.

Antonio J. Muñoz-García, Juan H. Alonso-Briales,
and José M. Hernández-García
Servicio de Cardiología, Hospital Clínico Universitario Virgen de
la Victoria, Málaga, Spain