

On the Metabolism of Prasugrel

Sobre el metabolismo de prasugrel

To the Editor,

We read with interest the editorial by Drs. Freedman and lafrati¹ recently published in *Revista Española de Cardiología*. The editorial mentions that prasugrel is an inhibitor of the P2Y₁₂ receptor, that it is not metabolized in the liver, and that it does not appear to be affected by the variability of isozyme P450. We believe that it might be a good idea here to indicate the pharmacokinetic characteristics of prasugrel.

Prasugrel (CS-747, LY-640315) is a third generation, orally administered thienopyridine that acts as a specific and irreversible antagonist of the 5'-diphosphate (ADP) P2Y₁₂ receptor, and which needs to be metabolized for it to exert its effect.^{2–4} The initial molecule, prasugrel, is rapidly hydrolyzed by intestinal and blood esterases to the metabolite thiolactone (R-95913) (Fig. 1). Thus, prasugrel is not detected in the plasma. Via the action of

cytochrome P450 (CYP), this intermediate metabolite is turned into the active metabolite R-138727, which bonds covalently and irreversibly to receptor P2Y₁₂.^{2,3}

This active metabolite of prasugrel reaches its peak in the plasma after about 30 min and in a manner proportional to the dose given (between 5 mg and 60 mg). When it does not bind to the platelets its half life is about 7 h. It should be remembered that the CYP enzymes involved in the metabolism of clopidogrel and prasugrel are polymorphic, ie, they differ between individuals, which partly accounts for the wide variation seen between patients in their response to clopidogrel.^{3,4}

The metabolism of prasugrel differs from that of clopidogrel in that the metabolism of the latter renders inactive close to 85% of the drug absorbed and two passes through the liver are required (CYP), which influences the variation in individual response.² In contrast, prasugrel is more efficiently converted into its active metabolite via a process of hydrolysis led by carboxyesterases (mainly intestinal), followed by a single pass through the hepatic CYP (3A4, 2B6, 2C9, 2C19) step. This partly explains its greater bioavailability and more efficient antiaggregant effect compared to clopidogrel.⁵

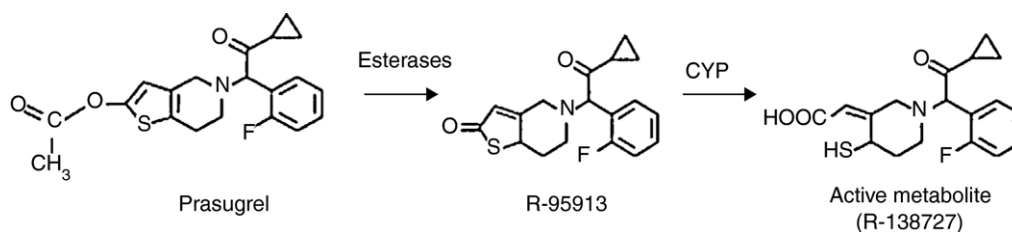


Figure 1. Structural changes required for the activation of prasugrel.

Carlos Felipe Barrera-Ramírez, Luis Ramón Pineda-Pompa, and Carlos E. Guzmán-Rodríguez

División de Cardiología Intervencionista y Hemodinamia, Centro Hospitalario La Concepción, Saltillo, Coahuila, Mexico

* Corresponding author:

E-mail address: carlosfbarrera@yahoo.com (C.F. Barrera-Ramírez).

Available online 16 April 2011

REFERENCES

1. Freedman JE, lafrati HF. Uso de la genética y la transcriptómica en el diagnóstico y tratamiento de la enfermedad coronaria. *Rev Esp Cardiol*. 2010;63:1123–6.

2. Wiviott SD, Antman EM, Braunwald E. Prasugrel Circulation. 2010;122:394–403.

3. Mega JL, Close SL, Wiviott SD, Shen L, Hockett RD, Brandt JT, et al. Cytochrome P450 genetic polymorphisms and the response to prasugrel relationship to pharmacokinetic, pharmacodynamic, and clinical outcomes. *Circulation*. 2009;119:2553–60.

4. Mega JL, Wiviott SD, Sabatine MS. Cytochrome P-450 polymorphisms and response to clopidogrel: reply. *N Engl J Med*. 2009;360:2251.

5. Angiolillo DJ, Ferreiro JL. Inhibición del receptor plaquetario P2Y₁₂ de adenosina difosfato plaquetario: efectos beneficiosos y limitaciones de las estrategias terapéuticas actuales y perspectivas futuras. *Rev Esp Cardiol*. 2010;63:60–76.

doi:10.1016/j.rec.2010.11.019

SEE RELATED ARTICLE:

DOI: [10.1016/S1885-5857\(10\)70225-5](https://doi.org/10.1016/S1885-5857(10)70225-5)

Paravalvular Regurgitations and Percutaneous Prosthetic Aortic Valves

Regurgitaciones paravalvulares y prótesis aórticas percutáneas

To the Editor,

We have read with great interest the study published by León et al.,¹ in which the authors report the reduction in paravalvular regurgitations and in left ventricular hypertrophy, according to echocardiography, one month after percutaneous implantation of

the CoreValve prosthesis in a group of 22 patients. The former effect is attributed to the self-expandability of the prosthesis and the latter to its excellent hemodynamic profile.

We would like to make a few observations on the basis of our own experience. In our center, between April 2008 and December 2010, 144 prostheses were implanted in patients with severe aortic valve disease—mean age, 79.6 ± 6 years; logistic EuroSCORE, 20 ± 14%—who underwent Doppler echocardiography prior to implantation, on the third day and 6 and 12 months postimplantation. After a mean follow-up of 11.6 ± 8 months, we could confirm the excellent hemodynamic profile of the prosthesis, with peak and mean gradients of 15.9 ± 6 mmHg and 8.8 ± 4 mmHg, respectively, as well

as an improvement in the ejection fraction (from $62 \pm 14\%$ to $67 \pm 10\%$; $P = .01$), which was detected in the majority of the patients with dysfunction prior to implantation. There was also an improvement in the functional class and quality of life questionnaires.

However, during follow-up we have not observed a significant reduction in paravalvular regurgitations (moderate in 23.4%, mild or trivial in 39.7% and absent in 36.9% on the third day after implantation versus moderate in 18.9%, mild or trivial in 46.8% and absent in 34.2% in the sixth month), with good agreement ($\kappa = 0.724$).

These data are similar to those published in other series,^{2,3} and we should point out the fact that in no case did the regurgitation affect hemolysis and that, in our series, it was not related to functional class or medium-term mortality. Its presence in trivial or mild cases could be considered to be of no greater clinical importance than the so-called "physiological" regurgitations observed in mechanical prostheses. In contrast, in a recently published multicenter study,⁴ moderate or higher grade regurgitation has been found to be a predictor of mortality between 30 days and 1 year after the procedure.

These paravalvular regurgitations could develop because of a poor choice of the prosthesis size, insufficient expansion of the prosthesis, too low a placement site or perhaps a nonuniform distribution of the valve calcium when, upon expansion of the prosthesis, it remains pressed between the device and the aortic wall. If the late reduction in aortic regurgitation observed in the series of León et al., can be attributed to the adaptability and self-expandability of the prosthesis, it should also be detected in the other series. These differences could be due to the bias associated with the selection of a small cohort or to other mechanisms related to patient characteristics or to postimplantation treatment. The formation of a periprosthetic thrombus or intimal proliferation may have sealed small periprosthetic leaks in the series of León et al., and the difference with respect to other series could lie in the postimplantation treatment. It will be interesting to follow the course of these patients in case a hypothetical leak-sealing intimal proliferation should lead to the development of pannus and an increase in the transprosthetic gradient.

On the other hand, assessment of the changes in left ventricle following implantation in our patients revealed an improvement in the ejection fraction, especially in cases of nonischemic ventricular dysfunction, but there was no evidence of a significant reduction in hypertrophy during follow-up (the interventricular

septal thickness decreased from 13.2 ± 2 mm to 12.4 ± 2 mm, $P = .3$; and that of posterior wall from 12.5 ± 2 mm to 12.2 ± 2 mm, $P = .78$). These findings coincide with those reported by De Jaegere et al.,³ who detected no differences in left ventricular mass or diastolic function 30 days after implantation, and are in accordance with the fact that these are cases of nonphysiological hypertrophy (in contrast to that observed in athletes), secondary to a chronic pressure overload (aortic stenosis, sometimes accompanied by hypertension) with varying degrees of fibrosis and, thus, with slow and limited reversibility. This circumstance, however, does not appear to impede the short-term and medium-term improvement in functional class in these patients.

Isabel Rodríguez-Bailón,* Antonio Muñoz-García,
Juan Alonso-Briaies, and José María Hernández-García

Servicio de Cardiología, Hospital Clínico Universitario Virgen
de la Victoria, Málaga, Spain

*Corresponding author:

E-mail address: irodriguezbaillon@gmail.com (I. Rodríguez-Bailón).

Available online 25 May 2011

REFERENCES

- León C, Suárez de Lezo J, Mesa D, Pan M, Ruiz M, Delgado M, et al. Evolución precoz de fugas en prótesis aórtica percutánea CoreValve: valoración ecocardiográfica. *Rev Esp Cardiol.* 2011;64:67-70.
- Grube E, Schuler G, Buellesfeld L, Gerckens U, Linke A, Wenaweser P, et al. Percutaneous aortic valve replacement for severe aortic stenosis in high-risk patients using the second- and current third-generation self-expanding CoreValve prosthesis: device success and 30-day clinical outcome. *J Am Coll Cardiol.* 2007;50:69-76.
- De Jaegere PP, Piazza N, Galema TW, Otten A, Soliman OI, Van Dalen BM, et al. Early echocardiographic evaluation following percutaneous implantation with the self-expanding CoreValve Revalving System aortic valve bioprosthesis. *Euro-Intervention.* 2008;4:351-7.
- Tamburino C, Capodanno D, Ramondo A, Petronio AS, Ettori F, Santoro G, et al. Incidence and predictors of early and late mortality after transcatheter aortic valve implantation in 663 patients with severe aortic stenosis. *Circulation.* 2011;123:299-308.

doi:10.1016/j.rec.2011.03.005

SEE RELATED ARTICLE:
DOI: 10.1016/j.rec.2010.10.001

Paravalvular Regurgitations and Percutaneous Prosthetic Aortic Valve. Response

Regurgitaciones paravalvulares y prótesis aórticas percutáneas. Respuesta

To the Editor,

We appreciate the interest shown by Rodríguez-Bailón et al. in our article published in *Revista Española de Cardiología*,¹ and we would like to make a few points regarding their comments. Two recently published reviews of several different studies^{2,3} regarding treatment using the CoreValve percutaneous prosthetic aortic valve and one large study⁴ have shown that frequency and/or

severity of paravalvular leaks tend to decrease. To our understanding, the difference in results with those from the Rodríguez-Bailón et al. study is based on methodology, with different criteria used to "quantify" these leaks. Some controversy exists among cardiac sonographers whether or not to evaluate paravalvular and central regurgitations the same, or if these should be classified into 4 or 3 grades as recommended in the most recent guidelines for prosthesis evaluations. On the other hand, the concept of "reducing" the leak also differs between studies, and some define a significant decrease as a reduction by more than 1 degree, but in other studies, as in ours, a decrease is deemed significant when it is at least 1 degree. Lastly, Rodríguez-Bailón et al. observed a decrease in the frequency of moderate regurgitations and an increase in mild regurgitations during the follow-up period, which was interpreted as an absence of changes due to high