

A prolapse of the P2-3 union and ruptured chordae in A2 were confirmed. Two neochordae were implanted, edge-to-edge anastomosis was performed in the posterior commissure, and a complete rigid no. 30 ring was placed, with good results on intraoperative TEE.

Estimates of the incidence of endocarditis in the general population range from 16 to 62 cases per million people per year. Although mitral valve replacement has been proposed for many years as the treatment for mitral endocarditis, mitral valve repair has become increasingly popular, and a recent review confirmed that it leads to good results in patients with endocarditis.⁴

Cases of large, complex mitral endocarditis occasionally present and require a thorough knowledge of the anatomy, mechanisms, and severity of valvular regurgitation.

Our initial experience with RT3DTEE shows it to be particularly useful in patients with complex MR and multiple mechanisms. We found that it improves on the findings obtained with 2DTEE and that it provides the surgeon with information of great importance for appropriate valve repair.

SUPPLEMENTARY MATERIAL



Supplementary material associated with this article can be found in the online version, available at doi:10.1016/j.rec.2011.04.018.

Francisco López-Pardo,* Antonio González-Calle, José López-Haldón, Juan Acosta-Martínez, Diego Rangel-Sousa, and Maria J. Rodríguez-Puras

Área del Corazón, Hospital Universitario Virgen del Rocío, Sevilla, Spain

* Corresponding author:

E-mail address: fjlopezp@telefonica.net (F. López-Pardo).

Available online 2 August 2011

REFERENCES

1. Sugent L, Sheman SK, Weinert L, Shook D, Raman J, Jeevanandam V, et al. Real-time three-dimensional transesophageal echocardiography in valve disease: comparison with surgical findings and evaluation of prosthetic valves. *J Am Soc Echocardiogr.* 2008;21:1347-54.
2. Tsang W, Weinert L, Kronzon I, Lang RM. Ecocardiografía tridimensional en la evaluación de las válvulas protésicas. *Rev Esp Cardiol.* 2011;64:1-7.
3. Hansalia S, Biswas M, Dutta R, Hage FG, Hsiung M, Nanda NC, et al. The value of live/real time three-dimensional transesophageal echocardiography in the assessment of valvular vegetations. *Echocardiography.* 2009;26:1264-73.
4. Feringa HH, Shaw LJ, Poldermans D, Hoeks S, Van der Wall EE, Dion RA, et al. Mitral valve repair and replacement in endocarditis: a systematic review of literature. *Ann Thorac Surg.* 2007;83:564-71.

doi: 10.1016/j.rec.2011.04.018

Outflow Tract Right Ventricular Pacing in Patients With a Persistent Left Superior Vena Cava

Estimulación en el tracto de salida de ventrículo derecho en pacientes con persistencia de vena cava superior izquierda

To the Editor,

Persistent left superior vena cava (LSVC) is a relatively common congenital anomaly, with an estimated prevalence of around 0.5%. In patients with congenital heart disease, the figure reaches almost 5% and in 10% there is no right superior vena cava. There are numerous case reports in the literature and a few small series in which pacemakers or defibrillators have been implanted through the LSVC. All describe specific techniques used to place electrical stimulation leads at a stable site;¹⁻³ some also propose techniques to locate the electrode lead in the right ventricular apex (RVA).⁴ To date, however, there have been few reports on the possibility of or the techniques used to implant leads in the region of the right ventricle outflow tract (RVOT).⁵

We present 2 cases in which the electrode lead was implanted in the RVOT via the LSVC. The first case was a 72-year-old female with a history of obesity and hypertension who was admitted for clinical fatigue of several weeks duration. In the electrocardiogram (ECG) and subsequent ECG monitoring, we documented alternation between an atrioventricular (AV) junctional rhythm at 45 bpm and sinus bradycardia with left anterior hemiblock. Echocardiography was performed and revealed slight concentric left ventricular hypertrophy with preserved systolic function. The electrophysiological study showed an HV interval of 60 ms and a slightly prolonged (600 ms) corrected sinus node recovery time, with significant secondary breaks (2800 ms).

A dual chamber permanent pacemaker was implanted via the left axillary vein. However, the guidewire route led to a suspicion of LSVC persistence which was confirmed by venography. It was

decided to implant the leads through the LSVC. In the first place, a 58 cm active fixation lead (Medtronic CapSure Fix 5076) with a distal electrode was inserted in the RVOT. This was done using a manually preformed stylet with a 180° curve approximately 4 cm from the tip. A 52 cm active fixation lead (Medtronic CapSure Fix 5076) with a distal electrode was then implanted on the upper side of the right atrium (RA), using a manually preformed stylet with a 60° curve approximately 3 cm from the tip. Both showed optimum electrical parameters, so the procedure was completed. No dislocations or changes in the stimulation parameters were observed during follow-up (Figs. 1 and 2).

The next case was an 82-year-old male with a history of hypertension, hyperlipidemia, ischemic heart disease (acute

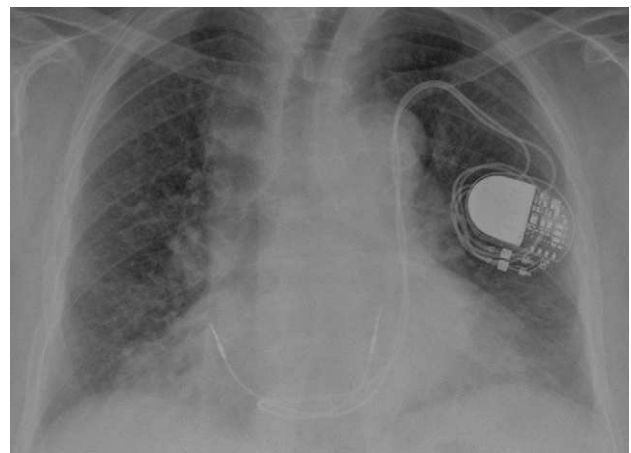


Figure 1. Posteroanterior chest radiograph, with leads inserted through the left superior vena cava. Distal ventricular electrode anchored in the right ventricular outflow tract.

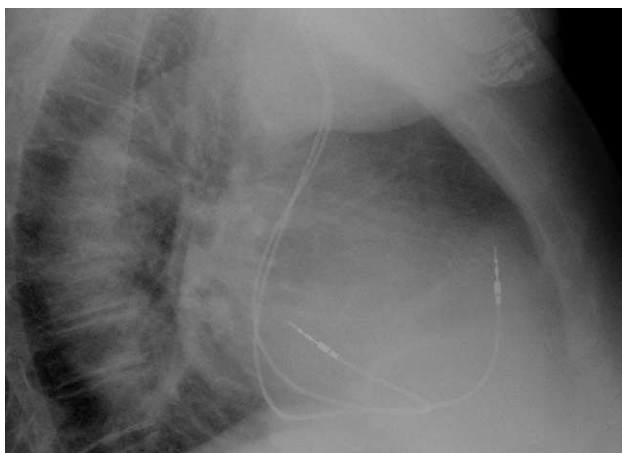


Figure 2. Lateral chest radiograph, with distal ventricular electrode in the right ventricular outflow tract.

inferior myocardial infarction), chronic obstructive pulmonary disease, and multiple myeloma. The patient was admitted for repetitive syncope after the ECG showed sinus rhythm with bifascicular block (RBBB + LAFB). Interrupted episodes of complete paroxysmal AV block were detected during electrocardiographic monitoring on the ward. Echocardiography showed mild left ventricular systolic dysfunction with inferior akinesis.

During implantation of a two-chamber permanent pacemaker via the left axillary vein, we observed LSVC persistence, the characteristics of which were similar to those described in the previous case. Two active fixation leads with distal electrodes were implanted in RA and RVOT, using manually preformed curved stylets identical to those described in case 1.

No dislocations or changes in the stimulation parameters were observed during follow-up.

Persistent LSVC can make implantation of a permanent pacemaker difficult. The fact that the coronary sinus ostium is not aligned with the tricuspid annulus means that the main technical problem consists of inserting the lead in the RV. The RVA has been the site of choice for cardiac stimulation, but reaching it in these cases usually means that the probe electrode forms a big loop in the RA.

Stimulation in the RVOT has been proposed as an alternative to RVA stimulation. In terms of lead stability, it has shown similar long-term results to those achieved with stimulation at the apex,⁶

and has also been shown to produce less dyssynchrony. Ventricular dyssynchrony promotes remodeling and in patients with left ventricular systolic dysfunction may have a deleterious effect on cardiac function. However, to date the benefits of RVOT stimulation have not been demonstrated in a randomized clinical trial. We have proposed a technique to reach this stimulation site in patients with persistent LSVC which only requires a manually preformed stylet. This can be similar to those used in normal conditions to reach the RVA, but without the need to form a loop in the RA.

Javier Jiménez-Díaz,^{a,*} Juan Benezet-Peñaranda,^b
and Arantzazu González Marín^c

^aUnidad de Arritmias, Servicio de Cardiología, Hospital General de Ciudad Real, Ciudad Real, Spain

^bUnidad de Arritmias, Unidad de Cuidados Intensivos, Hospital General de Ciudad Real, Ciudad Real, Spain

^cDepartamento de Cardiología Pediátrica, Servicio de Pediatría, Hospital General de Ciudad Real, Ciudad Real, Spain

*Corresponding author:

E-mail address: javierjimenezdiaz@wanadoo.es (J. Jiménez-Díaz).

Available online 23 July 2011

REFERENCES

1. Biffi M, Boriani G, Frabetti L, Bronzetti G, Branzi A. Left superior vena cava persistence in patients undergoing pacemaker or cardioverter-defibrillator implantation: a 10-year experience. *Chest*. 2001;120:139-44.
2. Biffi M, Bertini M, Ziacchi M, Martignani C, Valzania C, Diemberger I, et al. Clinical implications of left superior vena cava persistence in candidates for pacemaker or cardioverter-defibrillator implantation. *Heart Vessels*. 2009;24:142-6.
3. Feltes Guzmán GI, Vivas Balcones D, Pérez de Isla L, Zamorano Gómez JL. Malposición de catéter de marcapasos durante 9 años. Rol del ecocardiograma. *Rev Esp Cardiol*. 2011;64:250.
4. Hsiao HC, Kong CW, Wang JJ, Chan WL, Wang SP, Chang MS, et al. Right ventricular electrode lead implantation via a persistent left superior vena cava. An improved technique. *Angiology*. 1997;48:919-23.
5. Siliste C, Vinereanu D, Margulescu AD, Cinteza M. Right ventricular outflow tract implantation of an active fixation defibrillation lead through a superior vena cava. *Europace*. 2008;10:1454-5.
6. Coma Samartín R, Sancho-Tello de Carranza MJ, Ruiz Mateas F, Leal del Ojo González J, Fidalgo Andrés ML. Registro Español de Marcapasos. VII Informe Oficial de la Sección de Estimulación Cardíaca de la Sociedad Española de Cardiología (2009). *Rev Esp Cardiol*. 2010;63:1452-67.

doi: 10.1016/j.rec.2011.04.010

Prinzmetal Angina in the Migraine's Aura Resolving With Headache

Angina de Prinzmetal en el aura de la migraña que se resuelve con la cefalea

To the Editor,

We report the case of a 28-year-old woman referred to our hospital for constrictive chest pain with a left hemiparesis. She reported using oral contraceptive but had no cardiovascular risk factors. She had a history of unusual migraine with aura (left hemiparesis) since the age of 17 but had never been medicated and specifically not by ergotamine tartrate or triptan. Clinical examination showed left hemiparesis with a normal blood pressure of 132/76 mmHg. The electrocardiogram (ECG) revealed a sinus rhythm with ST-segment elevation in the inferior leads

with mirror image in the anterior leads suggestive of an acute inferior myocardial infarction (Fig. 1A). Per-critical acute transthoracic echocardiography revealed a mild hypokinesis of the inferior wall. The ascending aorta was normal without obvious criteria for aortic dissection. The neurologic signs led us to perform a computed tomography (Fig. 1B) that ruled out an intracerebral hemorrhage. The patient received treatment for acute coronary syndrome: sublingual nitrates, intravenous acetylsalicylic acid, loading dose of clopidogrel, and curative dose of enoxaparin. She was transferred without delay to the catheterization laboratory for primary percutaneous intervention. On her way to the catheterization laboratory, the chest pain and the hemiparesis disappeared but she complained of an intense headache. The coronary angiography demonstrated smooth coronary arteries with normal blood flow and no obstructive lesion (Fig. 1C). The postangiography ECG was normal (Fig. 1D). The 6-h troponin T rose to 11.6 ng/ml. The migraine headaches were treated by analgesics and her acute