

## Image in cardiology

## Optical Coherence Tomography of Magnesium Bioresorbable Scaffold Restenosis



## Tomografía de coherencia óptica en la reestenosis de armazón bioabsorbible de magnesio

Sergio García-Blas,\* Gema Miñana, and Juan Sanchis

Servicio de Cardiología, Hospital Clínico Universitario de Valencia, INCLIVA, CIBER Cardiovascular, Valencia, Spain

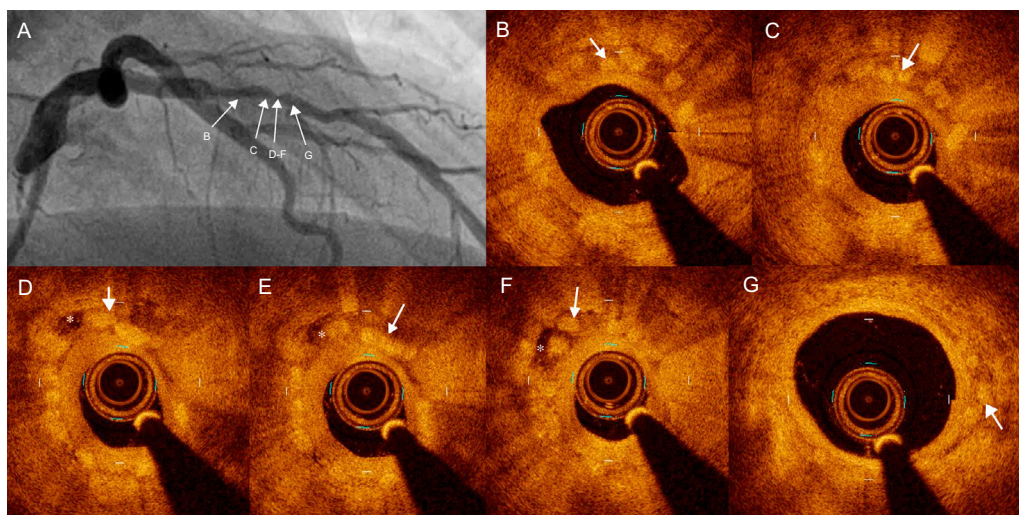


Figure.

A 58 year-old man was referred to cardiac catheterization for progressive effort angina 8 months after implantation of a magnesium bioresorbable scaffold in the mid left anterior descending coronary artery. In the current angiogram, severe focal restenosis was diagnosed (Figure A). Optical coherence tomography imaging showed strut remnants visualized as a “dissolved bright box” with partially visible bright spot and poorly defined contours (Figure B-G arrows) with complete endothelial coverage (Figure B-G, Video of the supplementary material). Focal restenosis consisted of moderate neointimal growth with a homogeneous pattern over an underexpanded scaffold (Figure C-F). Overlapped strut remnants surrounded by hypointense tissue (Figure D-F, asterisk) were evident. The patient was successfully treated by everolimus-eluting stent implantation.

Serial optical coherence tomography findings in the BISOLVE-II trial showed that struts are hardly discernible at 6 months' follow-up. However, the present case still showed struts in the process of resorption all along the scaffold at 8 months. The restenosis mechanism was mainly underexpansion together with neointimal growth. Underexpansion may be explained by focal calcium (Figure D-F, 1 to 3 o'clock); unfortunately, no optical coherence tomography imaging was performed in the first procedure, but predilatation and postdilatation with noncompliant balloon (1:1 balloon:vessel) should have warranted an adequate expansion. Moreover, strut overlap at this area may reflect some degree of late scaffold disruption, which may contribute to restenosis; this is an occasional finding in polymeric bioresorbable scaffold restenosis. Finally, hypointense areas surrounding strut remnants have not been described after magnesium bioresorbable scaffold, but similar “low-signal” images have been observed in first-generation stents and may correlate with chronic inflammation.

## FUNDING

CIBER CV 16/11/00420 FEDER.

## SUPPLEMENTARY MATERIAL



Supplementary material associated with this article can be found in the online version available at <http://dx.doi.org/10.1016/j.rec.2017.11.016>

\* Corresponding author:

E-mail address: [sergiogarciablas@gmail.com](mailto:sergiogarciablas@gmail.com) (S. García-Blas).

Available online 7 December 2017

<https://doi.org/10.1016/j.rec.2017.11.016>

1885-5857/© 2017 Sociedad Española de Cardiología. Published by Elsevier España, S.L.U. All rights reserved.