

## Image in cardiology

## Ongoing Stent Thrombosis: Optical Coherence Tomography Findings

Trombosis de *stent* en curso: hallazgos con tomografía de coherencia óptica

Javier Cuesta, Fernando Rivero, and Fernando Alfonso\*

Servicio de Cardiología, Hospital Universitario de la Princesa, Madrid, Spain

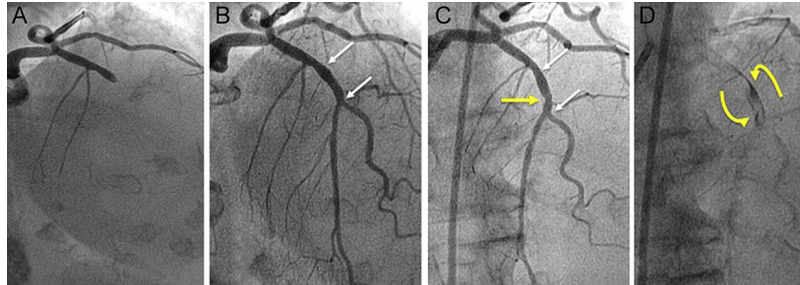


Figure 1.

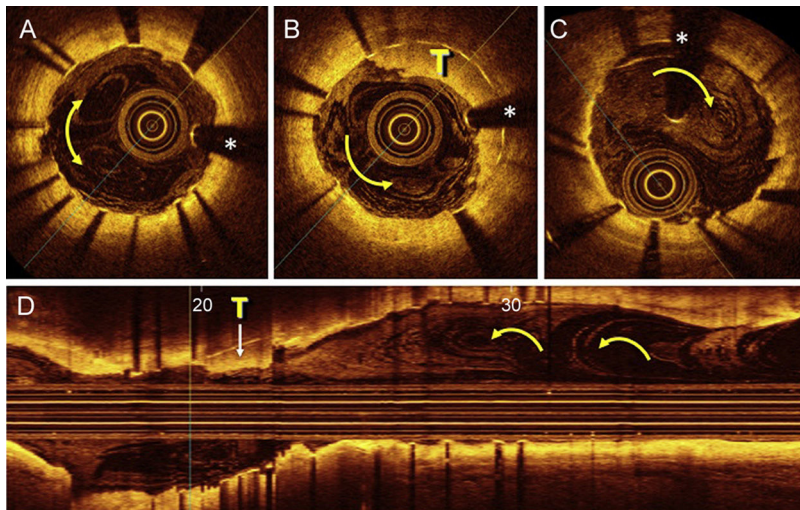


Figure 2.

An 83-year-old woman presented to the emergency department with anterior myocardial infarction; treatment was begun with dual antiplatelet therapy (aspirin and clopidogrel) and anticoagulation therapy. Urgent coronary angiography revealed thrombotic occlusion of the anterior descending artery (Figure 1A) and a severe lesion in the circumflex artery. Thromboaspiration was performed in the anterior descending artery, and a bare-metal stent (3 × 13 mm) was implanted with excellent angiographic results (Figure 1B). Three days later, the patient was asymptomatic and another bare-metal stent was placed in the circumflex artery, after which a small filling defect was observed (Figure 1C, yellow arrow) in the anterior descending artery stent, with contrast retention and slow clearance (Figure 1D). Optical coherence tomography demonstrated adequate stent expansion and good apposition, but revealed a small thrombus in its interior (Figure 2, T). Moreover, there was an interesting flow pattern, with images of “eddy-like” and the appearance of “smoke”, highly indicative of slow, turbulent flow, possibly related to the initial phases of the stent thrombosis (Figure 2, yellow arrows). Clopidogrel was replaced by ticagrelor and the patient remained asymptomatic after 6 months of follow-up.

Stent thrombosis is an uncommon but serious complication. Optical coherence tomography is an excellent diagnostic tool for the detection of coronary thrombosis. There is little information on what occurs during the initial phases of stent thrombosis, before the antegrade flow becomes affected. Our findings indicate slow flow, which could facilitate the formation of a thrombus in the stent. This pattern may represent a novel risk factor for stent thrombosis.

\* Corresponding author:

E-mail address: [falf@hotmail.com](mailto:falf@hotmail.com) (F. Alfonso).

Available online 4 April 2015