

Editorial

Next-generation Transcatheter Aortic Valves. An Opportunity to Expand Therapeutic Indications?



Nueva generación de válvulas percutáneas. ¿Podrían ampliarse las indicaciones de la técnica?

Manuel Pan* and José Suárez de Lezo

Servicio de Cardiología, Hospital Reina Sofía, Universidad de Córdoba (IMIBIC), Córdoba, Spain

Article history:

Available online 3 October 2014

INTRODUCTION

Interventional cardiologists have spent years working on and dreaming about transcatheter aortic valve implantation. In 2007–2008 we were privileged in Spain^{1,2} to use 2 of the most commonly-implanted devices at the time: the Cribier-Edwards aortic valve prosthesis¹ and the CoreValve self-expanding prosthesis.² These devices had successful initial results in high-surgical-risk patients with severe aortic stenosis. However, it soon became apparent that the devices had a number of limitations preventing their use in all patients with severe aortic stenosis. Furthermore, the implantation procedure sometimes led to complications and suboptimal results.^{3,4} After this initial experience, interventional cardiologists have now identified some areas where they would like to see technical improvements⁵:

1. A lower profile device to permit delivery with introducers measuring less than 18 F. A transfemoral approach requires a vessel with a diameter of at least 6 mm (for an 18-F sheath). Femoral complications are fairly common^{6,7} (Figure 1) and are associated with the artery orifice size made during valve access. Also, patients with small femoral vessels or severe ileo-femoral occlusive disease are not candidates for transfemoral valve implantation.
2. A wider range of prosthetic sizes to accommodate all annulus types from 17 mm to 29 mm. This need has gradually been met in recent years. Manufacturers have now introduced new models that cover virtually all aortic annulus sizes. The only exception are the newest prostheses on the market, but it is likely that they will also be available in a full range of sizes before long.
3. Improved prosthetic anchoring to the aortic annulus to reduce periprosthetic regurgitation, which is a key factor in the postimplantation clinical outcome.⁸ Irregular calcification on the native annulus sometimes prevents good apposition

between the valve structure and the periprosthetic tissue, which in turn causes a varying degree of regurgitation, even if the valve is properly positioned (Figure 2). Therefore, next-generation transcatheter aortic valves should be designed to reduce paravalvular leakage.

4. A device that is easy to reposition and completely retrievable if necessary. The valve must be correctly deployed in the aortic annulus. High deployment may cause aortic embolism, while low deployment may cause severe aortic regurgitation. To achieve good results immediately after the procedure, it is essential to select the appropriate site and be able to reposition the valve in an optimum location. Positioning can be challenging in aortas that lie on a very horizontal plane and in tortuous aortas.
5. Specific accessories, such as introducers, guidewires and femoral closure devices, must be available. Transcatheter aortic valve implantation is a new technique and it therefore needs specialized instrumentation. Over the years, smaller-diameter, hydrophilic-coated guidewires have been brought out to improve transfemoral insertion. More recently, dedicated guidewires have been designed to pass the valve into the ventricle using a preshaped tip to reduce the risk of left ventricular perforation.⁹
6. Long-term durability, ensuring that the system lasts for 10 to 15 years. More time is needed to show that transcatheter aortic valve implantation lasts as long as surgical valve replacement.

NEXT-GENERATION TRANSCATHETER AORTIC VALVES

Initial experience with 3 new transcatheter aortic valves has been reviewed in 3 articles in *Revista Española de Cardiología*. The new devices are SAPIEN 3 (Edwards Lifesciences; Irvine, California, USA),¹⁰ Lotus (Boston Scientific; Natick, Massachusetts, United States)¹¹ and DirectFlow (DirectFlow Medical; Santa Rosa, California, United States).¹² These devices have some of the technical improvements mentioned above.

Sapien 3

The design of Sapien 3 differs significantly from earlier models made by the same manufacturer. Its delivery system is available

SEE RELATED ARTICLES:

<http://dx.doi.org/10.1016/j.rec.2014.04.014>, Rev Esp Cardiol. 2014;67:953–4.

<http://dx.doi.org/10.1016/j.rec.2014.06.008>, Rev Esp Cardiol. 2014;67:954–6.

<http://dx.doi.org/10.1016/j.rec.2014.06.011>, Rev Esp Cardiol. 2014;67:956–8.

* Corresponding author: Servicio de Cardiología, Hospital Reina Sofía, Avda. Meléndez Pidal 1, 14001 Córdoba, Spain.

E-mail address: manuelpanalvarez@gmail.com (M. Pan).

<http://dx.doi.org/10.1016/j.rec.2014.07.004>

1885-5857/© 2014 Sociedad Española de Cardiología. Published by Elsevier España, S.L.U. All rights reserved.

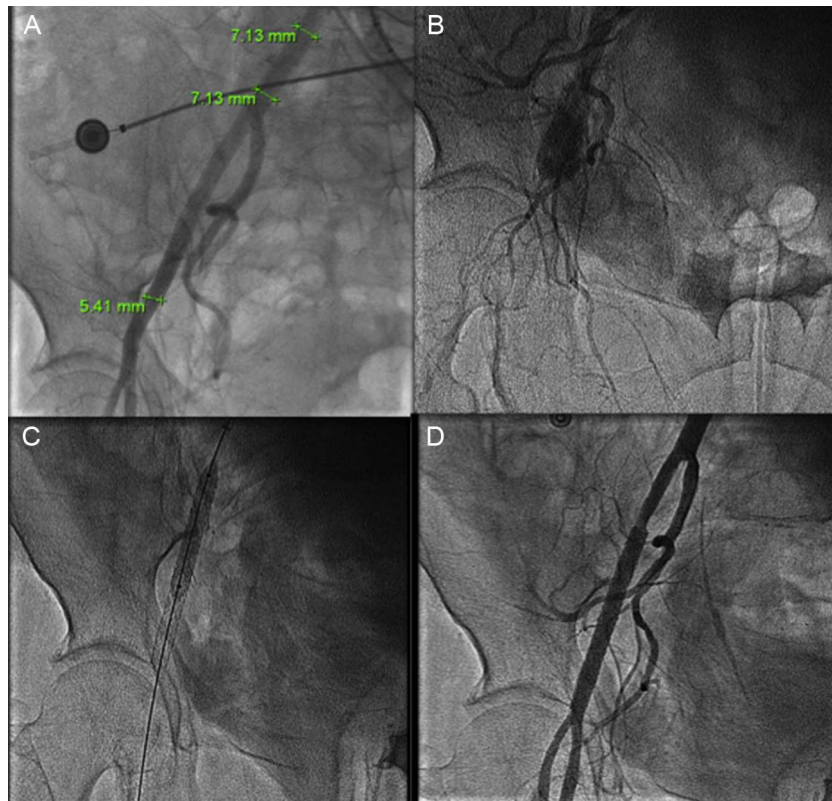


Figure 1. A: Femoral rupture after a Prostar closure device failure in a femoral artery with a diameter of less than 6 mm. This complication occurred after a successful transcatheter aortic valve implantation using an 18-F introducer. B: Angiography showing vessel rupture. C: Implantation of 2 coated stents. D: Final result.

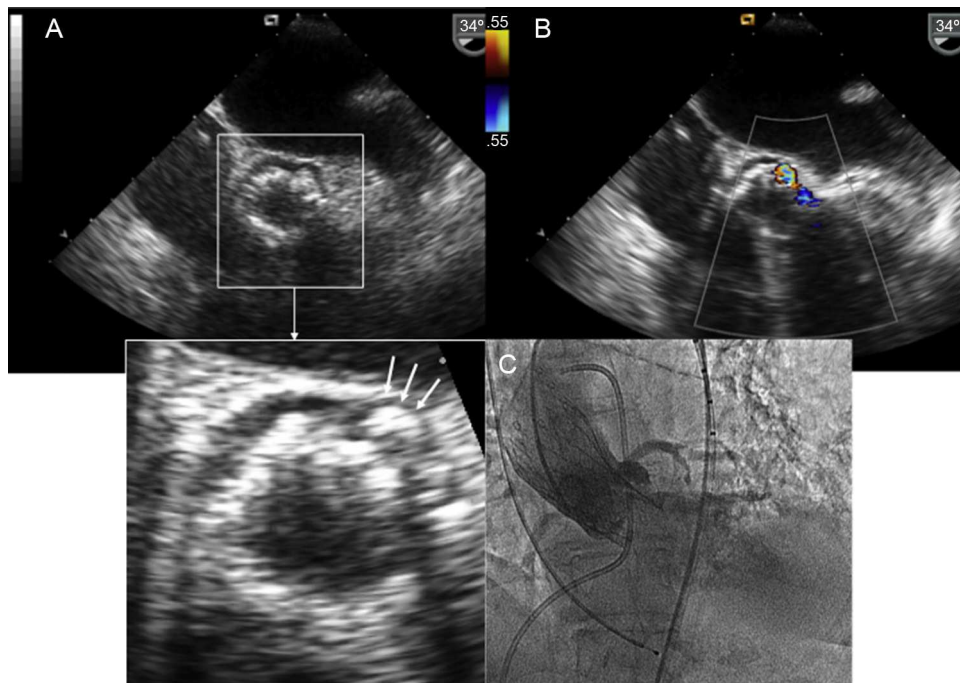


Figure 2. A: Calcific protuberance (arrows) preventing coaptation of a Corevalve prosthesis to the periprosthetic tissue. B and C: Periprosthetic aortic regurgitation (despite correct position), shown on color Doppler (B) and angiography (C).

with a 14-F sheath (for 23-mm and 26-mm valves) or a 16-F sheath (for 29 mm). Small sheath size has been achieved through the simplified cobalt chromium alloy frame, reduced strut thickness, and improved valve crimping system. It is the lowest profile delivery system currently available and it could become the system

of choice for patients with small-diameter femoral vessels (Figure 1).

Sapien 3 also has a polyethylene terephthalate inner and outer skirt, designed to minimize residual paravalvular leak. This is particularly beneficial for patients with an asymmetrical calcified

annulus (Figure 2). In fact, none of the patients described in the article¹⁰ had aortic regurgitation. The delivery system has a dual flex feature to improve valve positioning control and a radiopaque center marker on the balloon, which facilitates alignment along the valve plane. This feature is also an advantage for patients with a tortuous aorta.

Lotus

This device is a bovine pericardial tissue valve mounted on a preloaded nitinol stent. It is delivered over an 18-F sheath. With regard to the technical improvements mentioned above, this valve can be repositioned or retrieved before final implantation. It is also useful in patients with a highly tortuous aorta, which poses a challenge to correct device positioning. Another interesting new technical feature is the seal system with a urethane membrane, designed to conform to irregular calcified annulus surfaces (Figure 2). This technique minimizes the risk of paravalvular aortic regurgitation. In the series published in *Revista Española de Cardiología*, none of the patients had this complication.¹¹

DirectFlow

This prosthesis differs from the above-mentioned devices because it is a metal-free structure with communicating channels that are filled with a solution to conform 2 rings connected by a polyester frame. The lower ring anchors the prosthesis and the upper ring secures the 3 bovine pericardial leaflets. The delivery system consists of 3 wires attached to the lower ring. The positioning wires are used for ring filling and valve deployment. This device is also delivered over an 18-F sheath. It has 3 advantages over classical systems: it is retrievable, repositionable, and its ring inflation system creates a tight seal inside the periprosthetic tissue, thus minimizing the risk of periprosthetic regurgitation. As with the other devices, there were no reports of significant aortic regurgitation in the third case series.¹² One drawback is its reduced radial strength and slightly higher transvalvular pressure gradient, observed in 1 patient in the article.¹²

FUTURE PROSPECTS

Future indications for transcatheter aortic implantation will depend on the improvements over current devices in the coming years. We have mentioned many of these improvements above, and we expect to see a similar rate of change in the near future. Another key determinant in future of transcatheter aortic valves will be the findings of randomized studies comparing these valves with surgical valve replacement. In a recent study conducted in patients with severe aortic stenosis at high surgical risk, CoreValve implantation recipients had a higher 1-year survival rate than patients who underwent surgical valve replacement.¹³ In any event, more studies are required in patients at a lower surgical risk. To be able to expand current indications, we also need to know how long these prostheses will last in the long-term. At present, transcatheter aortic valve implantation is reserved for patients at high surgical risk. Since the technique was introduced, the number

of implantations performed has risen notably, from 10 000 implantations worldwide at the beginning of 2010, to more than 60 000 in 2013 (data supplied by Medtronic, the manufacturer of CoreValve). This rate of growth is expected to continue in coming years. The technical improvements made to the new devices, as reflected in the articles published in *Revista Española de Cardiología*,^{10–12} doubtlessly contribute to the growth rate. If this process follows the same trend as percutaneous revascularization in patients with heart disease, it is likely that there will soon be more transcatheter aortic valve implantations than surgical valve replacements, as was the case with heart revascularization. Whatever the future holds for transcatheter aortic valve implantation in the coming years, cardiologists who treat patients with aortic stenosis must work in close collaboration with one another.

CONFLICTS OF INTEREST

None declared.

REFERENCES

- García E, Pinto AG, Sarnago Cebada F, Pello AM, Paz M, García-Fernández MA, et al. Implantación percutánea de prótesis valvular aórtica: experiencia inicial en España. *Rev Esp Cardiol*. 2008;61:1210–4.
- Avanzas P, Muñoz-García AJ, Segura J, Pan M, Alonso-Briales JH, Lozano I, et al. Implante percutáneo de la prótesis valvular aórtica autoexpandible CoreValve® en pacientes con estenosis aórtica severa: experiencia inicial en España. *Rev Esp Cardiol*. 2010;63:141–8.
- Rodés-Cabau J, Webb JG, Cheung A, Ye J, Dumont E, Feindel CM, et al. Transcatheter aortic valve implantation for the treatment of severe symptomatic aortic stenosis in patients at very high or prohibitive surgical risk: acute and late outcomes of the multicenter Canadian experience. *J Am Coll Cardiol*. 2010;55:1080–90.
- Moreno R, Calvo L, Salinas P, Dobarro D, Santiago JV, Sanchez-Recalde A, et al. Causes of peri-operative mortality after transcatheter aortic valve implantation: a pooled analysis of 12 studies and 1223 patients. *J Invasive Cardiol*. 2011;23:180–4.
- Pan M, Suárez de Lezo J. Percutaneous aortic valve implant: Future indications. *Cardiovasc*. 2010;45:58–61.
- Van Mieghem NM, Tchetché D, Chieffo A, Dumonteil N, Messika-Zeitoun D, Van der Boon RM, et al. Incidence, predictors, and implications of access site complications with transfemoral transcatheter aortic valve implantation. *Am J Cardiol*. 2012;110:1361–7.
- Toggweiler S, Leipsic J, Binder RK, Freeman M, Barbanti M, Heijmen RH, et al. Management of vascular access in transcatheter aortic valve replacement: part 2: Vascular complications. *JACC Cardiovasc Interv*. 2013;6:767–76.
- Sabaté M, Cánovas S, García E, Hernández Antolín R, Maroto L, Hernández JM, et al. Predictores de mortalidad hospitalaria y a medio plazo tras el reemplazo valvular aórtico transcáteter: datos del registro nacional TAVI 2010–2011. *Rev Esp Cardiol*. 2013;66:949–58.
- Roy DA, Laborde JC, Sharma R, Jahangiri M, Brecker SJ. First-in-man assessment of a dedicated guidewire for transcatheter aortic valve implantation. *EuroIntervention*. 2013;8:1019–25.
- García E, Unzué L, García E, Solís J, Teijeiro R, Tarancón B. Experiencia inicial con la válvula aórtica percutánea de muy bajo perfil SAPIEN 3. *Rev Esp Cardiol*. 2014;67:953–4.
- Larman Tellechea M, Tellería Arrieta M, Lasa Larraya G, Sanmartín Peña JC, Gaviria Molinero K. Implante transcáteter de la válvula aórtica Lotus™: serie inicial de 5 casos. *Rev Esp Cardiol*. 2014;67:954–6.
- Hernández-Antolín RA, Salido L, González A, Samaranch N, Palomera A, Zamorano JL. Experiencia inicial en España con la prótesis aórtica percutánea DirectFlow. *Rev Esp Cardiol*. 2014;67:956–8.
- Adams DH, Popma JJ, Reardon MJ, Yakubov SJ, Coselli JS, Deeb GM, et al. Transcatheter aortic-valve replacement with a self-expanding prosthesis. *N Engl J Med*. 2014;370:1790–8.