

Neonatal Cholestasis. A Rare Complication of Fetal Tachycardia

To the Editor:

Fetal tachycardia is an infrequent problem (approximate prevalence of 1/10 000 pregnancies)¹ that causes important morbidity and mortality. The diagnosis can be made prenatally incidentally, although the most frequent form of presentation is heart failure and hydrops foetalis.² In order to avoid complications of a sustained foetal tachycardia, an intrauterine diagnosis can be made using foetal echocardiography and administering adequate treatment by the transplacental route.^{1,3,4} We present a case of a newborn that, in spite of prenatal diagnosis and treatment, developed a cholestasis secondary to foetal tachycardia, a complication which, to date, has rarely been described.⁵

In the ultrasound at 33 weeks gestation, foetal tachycardia of 240 beats/min was observed, with 1:1 atrio-ventricular conduction and pericardial effusion (Figure 1). Transplacental foetal treatment was started by administering digoxin to the mother, resulting in a decrease in the foetal heart rate to 140 beats/min. No toxicity was found in the mother. Ten days after starting treatment, the foetal tachycardia reappeared (223 beats/min); flecainide was added to the treatment, with a good response, but 5 days later, foetal tachycardia was again observed, and delivery was induced. During the 2 hours before birth, a normal foetal heart rate was observed. The baby was born with spontaneous cries, but progressive respiratory depression ensued and therefore the baby had to be examined in the delivery room (Apgar 3/8). When exploring the newborn, a macrosomia, an edematous aspect and a systolic murmur III/VI in the mesocardium stood

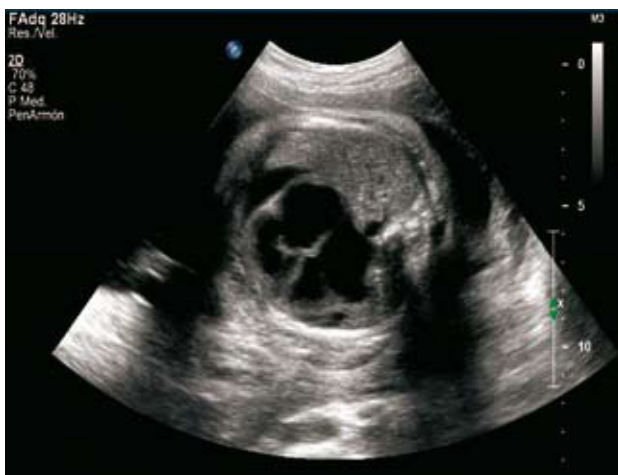

Figure 1. Prenatal echocardiography with pericardial effusion.

out. A cardiologic study was performed and a Wolff-Parkinson-White (WPW) type pre-excitation was found in the electrocardiogram (Figure 2). No pericardial effusion was found on echocardiography, but a moderate to severe tricuspid insufficiency and mild myocardial dysfunction (ejection fraction, 55%; shortening fraction, 27%) were observed. Neonatal treatment was initiated for the tachycardiomyopathy with furosemide and digoxin. The patient remained stable, with a normal heart rate, at all times, and there was an improvement in the functioning of the left ventricle.

On the fourth day of life, the newborn presented a green ictericia and coluria, without acolia nor other symptoms. Hyperbilirubinemia (20.2 mg/dL; direct, 4.9 mg/dL) was confirmed in the blood work. Direct bilirubin levels >2 mg/dL in newborns and lactating babies is considered indicative of cholestasis, and therefore complementary tests were requested to

complete the study. Alterations were not found in the hepatic enzymes (alkaline phosphatase, AST, ALT) nor in its function, except for elevated GGT and LDH (773 and 1255 U/L, respectively). In the abdominal ultrasound no anomalies were found in the biliary path and the rest of the study for neonatal cholestasis made it possible to exclude infectious or metabolic causes. The parameters for cholestasis were progressively decreasing without treatment until they reached normal levels at 18 days of life, and the baby was discharged with digoxin as its only treatment.

After 2 months of life, the baby was reviewed in a visit; it presented a good ponderal weight gain and no symptoms. Its ventricular function appeared completely normal on echocardiogram. As the cardiomyopathy diagnosed at birth had disappeared, treatment with digoxin was suspended and a prophylactic treatment was initiated with amiodarone that was also suspended at the 1 year review. Currently (18 months old), the baby continues to be symptom-free and has not presented any episodes of supraventricular tachycardia.

Foetal tachycardia and atrio-ventricular block (AVB) can produce cholestasis in the neonatal period; the pathophysiological mechanism is not clear, although it seems that it is due to congestion or ischemia.⁵ Hepatic alterations can be transitory, as in the case of our patient, but cases have been described that presented irreversible damage (specifically in those with AVB). Therefore, follow-up on liver function should be carried out on all newborns with a history of alterations of the intrauterine rhythm.

Álvaro Gimeno-Díaz de Atauri, Antonio Gil-Sánchez,
 Ángela García-Parrón, and Vega Murga-Herrero
 Unidad de Cardiología Pediátrica, Servicio de Pediatría, Hospital Clínico
 Universitario de Salamanca, Salamanca, Spain

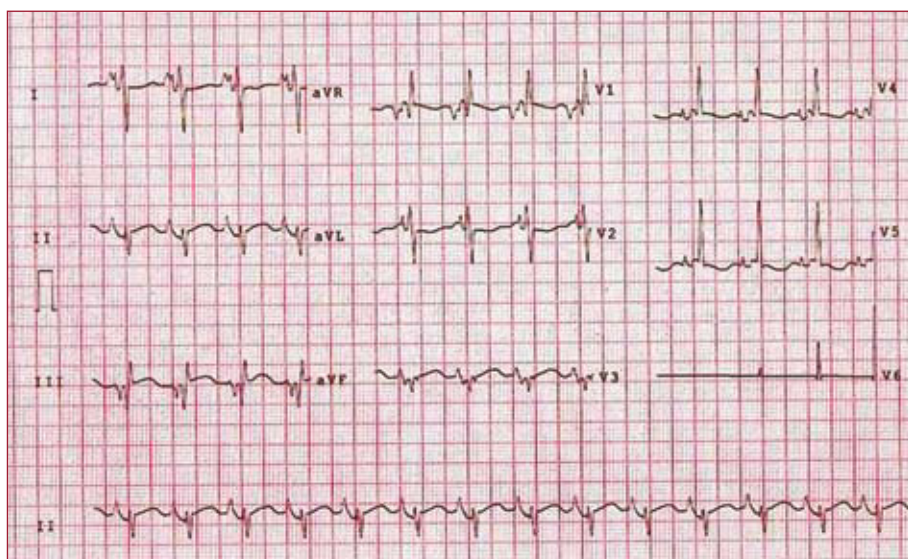


Figure 2. Electrocardiogram at birth. Wolff-Parkinson-White type pre-excitation.

REFERENCES

1. Gutiérrez-Larraya Aguado F, Galindo Izquierdo A, Olaizola Llodio I, Velasco Bayón, Merino Batres G, De la Fuente P. Taquicardias supraventriculares fetales. *Rev Esp Cardiol.* 1996;49:444-50.
2. Wren C. Cardiac arrhythmias in the fetus and newborn. *Semin Fetal Neonatal Med.* 2006;11:182-90.
3. Jaeggi ET, Nii M. Fetal brady- and tachyarrhythmias: new and accepted diagnostic and treatment methods. *Semin Fetal Neonatal Med.* 2005;10:504-14.
4. Simpson JM, Sharlanc GK. Fetal tachycardias: Management and outcome of 127 consecutive cases. *Heart.* 1998;79:576-81.
5. Sant'Anna AM, Fouron JC, Álvarez F. Neonatal cholestasis associated with fetal arrhythmia. *J Pediatr.* 2005;146:277-80.
6. Suchy FJ. Neonatal cholestasis. *Pediatr Rev.* 2004;25:388-96.
7. Manzanares López-Manzanares J, Medina Benítez E. Colestasis en el recién nacido y el lactante. Orientación diagnóstica. *An Pediatr.* 2003;58:162-7.