

Original article

# Natural History and Clinical Outcome of “Uncorrected” Scimitar Syndrome Patients: a Multicenter Study of the Italian Society of Pediatric Cardiology

Vladimiro L. Vida,<sup>a,\*</sup> Maddalena Padrini,<sup>b</sup> Giovanna Boccuzzo,<sup>c</sup> Gabriella Agnoletti,<sup>d</sup> Sara Bondanza,<sup>e</sup> Gianfranco Butera,<sup>f</sup> Enrico Chiappa,<sup>g</sup> Maurizio Marasini,<sup>e</sup> Mara Pilati,<sup>h</sup> Giacomo Pongiglione,<sup>h</sup> Daniela Prandstraller,<sup>i</sup> Maria Giovanna Russo,<sup>j</sup> Biagio Castaldi,<sup>j</sup> Giuseppe Santoro,<sup>j</sup> Isabella Spadoni,<sup>k</sup> Giovanni Stellin,<sup>a</sup> and Ornella Milanese,<sup>b</sup> on behalf of the Italian Society of Pediatric Cardiology

<sup>a</sup> Pediatric and Congenital Cardiac Surgery Unit, Department of Thoracic, Cardiac and Vascular Sciences, University of Padua, Padua, Italy

<sup>b</sup> Pediatric Cardiology Unit, Department of Pediatrics, University of Padua, Padua, Italy

<sup>c</sup> Department of Statistical Science, University of Padua, Padua, Italy

<sup>d</sup> Department of Pediatric Cardiology, Regina Margherita Children's Hospital, Turin, Italy

<sup>e</sup> Department of Pediatric Cardiology and Cardiac Surgery, Giannina Gaslini Institute, Genova, Italy

<sup>f</sup> Pediatric Cardiology and GUCH Unit, Policlinico San Donato, Milan, Italy

<sup>g</sup> Department of Pediatric Cardiology, Meyer Hospital, Florence, Italy

<sup>h</sup> Department of Pediatric Cardiology, Bambino Gesù Children's Hospital, Rome, Italy

<sup>i</sup> Pediatric Cardiology and Adult Congenital Unit, University of Bologna, Bologna, Italy

<sup>j</sup> Pediatric Cardiology Unit, Second University of Naples, Monaldi Hospital, Naples, Italy

<sup>k</sup> Department of Pediatric Cardiology, CNR G. Pasquonucci Hospital, Massa, Italy

Article history:

Received 4 January 2013

Accepted 11 March 2013

Available online 28 May 2013

Keywords:

Scimitar syndrome

Multicenter study

Natural history

ABSTRACT

**Introduction and objectives:** To analyze the clinical status of patients with “uncorrected” scimitar syndrome in a multicenter Italian study.

**Methods:** The natural history of scimitar syndrome was analyzed in 44 affected individuals (from 9 Italian centers).

**Results:** The median age at diagnosis was 1.05 years (range, 1 day-41 years). Thirty-three patients (75%) had an isolated form; 11 patients (25%) had associated congenital heart diseases. Twenty-two patients (50%) were symptomatic at diagnosis, including respiratory symptoms (n=20) and congestive heart failure (n=6). Patients with associated congenital heart defects had a higher prevalence of congestive heart failure (4 of 11 [36.4%] vs 2 of 33 [6.1%];  $P=.027$ ), pulmonary arterial hypertension (7 of 11 [63.6%] vs 2 of 33 [6.1%];  $P=.027$ ) than patients with isolated forms. Ten patients (22.7%) underwent correction of associated cardiac defects, leaving the anomalous pulmonary venous drainage intact. The median length of follow-up after diagnosis was 6.4 years (range, 0.2-27.5 years). Two patients died, both with associated cardiac defects and severe pulmonary arterial hypertension. Of 42 survivors, 39 (92.8%) were asymptomatic at the last follow-up visit; 3 patients still complained respiratory symptoms. There was no difference between isolated and associated forms of the disease.

**Conclusions:** In most patients, scimitar syndrome presented as an isolated lesion with a benign outcome. Nonetheless, when associated with other cardiac defects and pulmonary arterial hypertension, there was an increased risk of congestive heart failure and mortality. Correction of associated cardiac defects (transforming “associated” into “isolated” forms), together with the therapeutic occlusion of anomalous arterial supply to the lung, led to a benign outcome comparable to that in primarily isolated forms.

© 2013 Sociedad Española de Cardiología. Published by Elsevier España, S.L. All rights reserved.

## Historia natural y evolución clínica de los pacientes con síndrome de la cimitarra «no corregido»: un estudio multicéntrico de la Sociedad Italiana de Cardiología Pediátrica

RESUMEN

**Introducción y objetivos:** Analizar el estado clínico de los pacientes con síndrome de la cimitarra «no corregido» en un estudio multicéntrico italiano.

**Métodos:** Se analizó la evolución natural del síndrome de la cimitarra en 44 individuos afectados de nueve centros de Italia.

**Resultados:** La mediana de edad de diagnóstico fue 1,05 años (intervalo, 1 día-41 años). En total, 33 pacientes (75%) presentaban una forma aislada; en 11 (25%) había cardiopatías congénitas asociadas; 22 pacientes (50%) tenían síntomas en el momento del diagnóstico, que consistían en síntomas

Palabras clave:

Síndrome de la cimitarra

Estudio multicéntrico

Evolución natural

\* Corresponding author: Pediatric and Congenital Cardiac Surgery Unit, Department of Cardiac, Thoracic and Vascular Surgery, University of Padua, Via Giustiniani 2, 35100 Padua, Italy.

E-mail address: vladimiro.vida@unipd.it (V.L. Vida).

respiratorios (n = 20) e insuficiencia cardiaca congestiva (n = 6). Los pacientes con cardiopatías congénitas asociadas presentaban prevalencias de insuficiencia cardiaca congestiva (4 de 11 [36,4%] frente a 2 de 33 [6,1%]; p = 0,027) e hipertensión arterial pulmonar (7 de 11 [63,6%] frente a 2 de 33 [6,1%]; p = 0,027) superiores que los pacientes con formas aisladas del trastorno. A 10 pacientes (22,7%), se les practicó una corrección de los defectos cardiacos asociados, con lo que se dejó intacto el drenaje venoso pulmonar. La mediana de duración del seguimiento después del diagnóstico fue de 6,4 (0,2–27,5) años. Fallecieron 2 pacientes, ambos con defectos cardiacos asociados e hipertensión arterial pulmonar grave. De los 42 supervivientes, 39 (92,8%) estaban asintomáticos en la última visita de seguimiento; 3 pacientes continuaban refiriendo síntomas respiratorios. No se observaron diferencias entre las formas aisladas y las formas asociadas de la enfermedad.

**Conclusiones:** En la mayoría de los pacientes, el síndrome de la cimitarra se manifestó en forma de una lesión aislada con evolución benigna. No obstante, cuando se asociaba a otros defectos cardiacos y a hipertensión arterial pulmonar, había aumento del riesgo de insuficiencia cardiaca congestiva y muerte. La corrección de los defectos cardiacos asociados (transformación de una forma «asociada» a una forma «aislada»), junto con la oclusión terapéutica de la irrigación arterial anómala del pulmón, proporcionó una evolución benigna comparable a la de las formas aisladas primarias.

© 2013 Sociedad Española de Cardiología. Publicado por Elsevier España, S.L. Todos los derechos reservados.

### Abbreviations

CHD: congenital heart disease  
CHF: congestive heart failure  
PAH: pulmonary arterial hypertension

## INTRODUCTION

Scimitar syndrome is a rare association of cardiopulmonary anomalies and represents only 3% to 6% of all forms of partial anomalous pulmonary venous connections.<sup>1–4</sup> Both the right lung and the right pulmonary artery are frequently hypoplastic and the lung receives its blood supply from systemic collaterals mainly arising from the thoracic or the abdominal aorta.<sup>5–8</sup> An associated atrial septal defect is found in approximately 60% to 70% of patients with scimitar syndrome, and other congenital heart diseases (CHDs) are associated in 19% to 31%.

The decision-making process for surgical correction is often challenging, and there is still no consensus on the correct indications and the ideal timing of repair, especially in asymptomatic patients who are frequently diagnosed incidentally.<sup>9–12</sup>

The objective of this study was to analyze the clinical status of patients with scimitar syndrome who did not undergo surgical repair of the anomalous venous drainage and who underwent follow-up of the natural history of their disease within an Italian multicenter study.

## METHODS

A review of the medical records and computerized hospital data was approved by the Ethical Committee of the University Hospital of Padua, and the procedures followed were in accordance with the institutional guidelines for retrospective record review and protection of patient confidentiality. The data reviewed were related to the in-hospital clinical course and to the follow-up status of patients with scimitar syndrome who did not undergo surgical correction of the anomalous pulmonary venous drainage (“scimitar drainage”) and who underwent follow-up of the natural history of the syndrome from January 1997. Data collection was carried out in 9 Italian pediatric cardiology centers within the Italian Society of Pediatric Cardiology.

In this study, the patients were divided in 2 groups: group 1 included patients with isolated scimitar syndrome (without hemodynamically significant associated CHDs, thus including

patients with a patent foramen ovale) who did not require surgical treatment; group 2 included patients with associated CHDs who required treatment of associated congenital heart defects.

The variables analyzed included patient age at diagnosis, the presence of symptoms at the time of diagnosis, including both congestive heart failure (CHF) and respiratory symptoms (due to recurrent upper respiratory tract infections, pneumonia, and hemoptysis), the presence of pulmonary arterial hypertension (PAH) (defined as a mean pulmonary artery pressure greater than 25 mmHg at rest), and the presence of moderate-severe right ventricular dilation. We also considered the impact of hemodynamic procedures (ie, interventional coil embolization of aorto-pulmonary collaterals or other interventional maneuvers in associated CHDs including percutaneous occlusion of patent ductus arteriosus) and the impact of surgical procedures on associated CHD (leaving scimitar vein drainage intact) on patient outcome.

The primary outcome was the patients' clinical status at the end of follow-up (defined as the presence of symptoms).

The association between dichotomous variables was verified by Fisher's exact test. Quantitative variables were compared by using the Wilcoxon signed rank test. The significance level was set at 0.05. Data were analyzed using SAS Stat 9.2® (SAS Institute Inc.; North Carolina, United States).

## RESULTS

Forty-four patients were included from 9 Italian centers (median of 3.5 patients per center [range, 1–20 patients]). There were 25 women (56.8%) and 19 men (43.2%). In all patients, diagnosis was established by chest X-ray and echocardiography. Additional instrumental examinations included cardiac catheterization in 31 patients (70.4%), computed tomography in 16 patients (36.3%) and magnetic resonance angiography in 11 patients (25%).

Thirty-three patients (75%) presented with an isolated form of scimitar syndrome. The remaining 11 patients (25%) presented with other associated CHD including an atrial septal communication, secundum type (n=4), a patent ductus arteriosus (n=6), a ventricular septal defect (n=4), an aortic isthmus coarctation (n=2), and a mixed anomalous pulmonary venous connection (including “scimitar vein drainage” and a partial anomalous pulmonary venous drainage of the left superior pulmonary vein into the innominate vein through a vertical collector vein) (n=1). Five patients had 2 or more associated CHDs (excluding a patent foramen ovale).

The median age of the patients at diagnosis was 1.05 years (range, 1 day–41 years). Prenatal two-dimensional-echo diagnosis

was possible in 2 patients. Twenty-two patients (50%) were symptomatic at the time of diagnosis; symptoms included respiratory symptoms (n=20) (caused by recurrent respiratory infections in 20 patients and by recurrent hemoptysis in 1 patient) and CHF (n=6). Four patients had both CHF and respiratory symptoms. Two of the 33 patients with the isolated form of scimitar syndrome had CHF at diagnosis (2 of 33 [6.1%] vs 4 of 11 [36.4%] patients with associated CHDs;  $P=.027$ ) (Table 1). No correlation was found between patient age and the presence of significant right lung hypoplasia and the presence of symptoms at diagnosis.

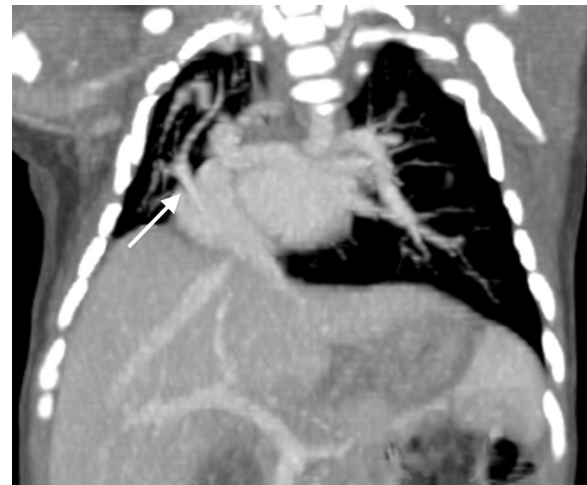
Significant right lung hypoplasia was found in 25 patients (56.8%) and there was no difference between groups in the prevalence of significant lung hypoplasia (17 of 33 [51.5%] in group 1 vs 8 of 11 [72.7%] in group 2;  $P=.301$ ). One patient presented with a horseshoe lung (Figure).

Moderate-to-severe right ventricular chamber dilatation was assessed in 14 patients (31.8%); patients with associated CHD had a higher prevalence of moderate-to-severe right ventricle dilatation (6 of 11 [54.5%] vs 8 of 33 [24.2%] in patients with isolated forms;  $P=.132$ ).

At cardiac angiography, a systemic arterial supply to the right lung was demonstrated in 24 of 31 patients (77.4%); of these, 15 were treated by coil embolization. The median mean pulmonary artery pressure was 20 mmHg (range, 13–50 mmHg) (Table 1). Seven patients (7 of 31 [22.5%]) presented with PAH (demonstrated by angiography); patients with associated CHD had a higher prevalence of PAH (2 of 24 [8.3%] in group 1 and 5 of 7 [71.4%] in group 2;  $P<.0001$ ).

All patients with associated CHDs underwent repair of their cardiac malformations without correction of the anomalous pulmonary venous connection (scimitar collector).

Nine patients underwent surgical treatment including: a) atrial septal defect secundum type closure (n=4); b) ventricular defect closure (n=4); c) patent ductus arteriosus ligation (n=6); d) isthmic coarctation repair (n=2), and e) correction of the left anomalous pulmonary venous drainage in the patient with a mixed anomalous pulmonary venous connection (n=1). In 2 of these patients the diagnosis of scimitar syndrome was reached incidentally, a few years after the closure of an atrial septal communication. In the remaining 7 patients, all with significant



**Figure.** Computed tomography-angiography image of an asymptomatic 1 month-old boy with scimitar syndrome. Note the anomalous pulmonary venous drainage (arrow), the hypoplasia of the right lung, the dextrocardia of the heart and the horseshoe lung.

right lung hypoplasia, the anomalous pulmonary venous drainage was deemed not hemodynamically significant at the time of diagnosis and was not treated.

The remaining 2 patients with associated CHDs underwent percutaneous patent ductus arteriosus occlusion during angiographic evaluation.

### Follow-up

The median follow-up was 6.4 years (range, 0.2–27.5 years). None of the patients underwent correction of scimitar vein drainage. Two patients (4.5%), both with associated CHDs at diagnosis, died: the first died at the age of 14 months from CHF and severe untreatable pulmonary hypertension and the second died at the age of 5 months from CHF, pulmonary hypertension and acute renal failure after surgical correction of a left anomalous pulmonary venous drainage.

**Table 1**

Demographics, Clinical Status at Diagnosis and Hemodynamic Parameters According to the Different Forms of Scimitar Syndrome (n=44 Patients)

	Isolated forms (n=33 [75%])	Forms associated with CHDs <sup>a</sup> (n=11 [25%])	Total, no.	P
Males	13 (39.4)	6 (54.6)	44	.48
Age at diagnosis, months	1.7 [0–41]	0.3 [0.1–30]	44	.11
Asymptomatic patients	18 (54.6)	4 (36.4)	22	.48
Symptoms at diagnosis	15 (45.4)	7 (63.6)	22	.48
Congestive heart failure	2 (6.1)	4 (36.4)	6	.02
Respiratory symptoms	15 (45.4)	5 (45.4)	20	1
Qp:Qs	1.45 [1–3]	1.95 [1–2.8]	44	.18
mPAP, mmHg	20 [13–34] <sup>a</sup>	34 [18–50] <sup>b</sup>	44	.004
mPAP>25 mmHg	2/24 (8.3)	5/7 (71.4)	7	.002
Right ventricular dilation	8 (24.2)	6 (54.6)	14	.13
Embolization of collaterals	11/24 (45.8)	4/7 (57.1)	15	.46
Pulmonary hypoplasia	17 (51.5)	8 (72.7)	25	.30
Surgery for other CHDs	0	8 (72.7)	8	–
Hemodynamic procedures on other CHDs	0	2 (18.2)	2	–

CHD, congenital heart disease; mPAP, median pulmonary arterial pressure<sup>a</sup>.

Data are expressed as no. (%) or median [range].

<sup>a</sup> Data from 24 of 33 patients who underwent cardiac catheterization.

<sup>b</sup> Data from 7 of 11 patients who underwent cardiac catheterization.

**Table 2**  
Outcomes and Clinical Status at Follow-up According to the Different Forms of Scimitar Syndrome (n=44 Patients)

	Isolated forms (n=33 [75%])	Forms associated to CHDs (n=11 [25%])	Total, no.	P
Deaths	0	2 (18.2)	2	.05
Symptoms at follow-up	2 (6.1)	1 (11.1)	3	.1
Congestive heart failure	0	0	0	–
Respiratory symptoms	2 (6.1)	1 (11.1)	3	1

CHD, congenital heart disease.

Data are expressed as no. (%).

Thirty-nine patients (39 of 42 survivors [92.8%]) were asymptomatic at the last follow-up visit (31 patients with isolated scimitar syndrome [93.9%] and 8 patients with the associated form [88.8%]). Three patients still had respiratory symptoms (age at follow-up was 2.7, 6.0 and 47.2 years) (Table 2). Twenty-two patients have never complained of symptoms (22 of 42 survivors [52.3%]), whereas 17 patients (17 of 42 [40.7%]) had improved clinical status, mainly presenting with respiratory symptoms at diagnosis (16 of 17 patients). The clinical status of 4 patients with CHF at diagnosis also improved: a) following the correction of associated CHDs plus embolization of collaterals in 2 patients with associated CHDs, and b) following embolization of collaterals in 2 patients with isolated forms.

## DISCUSSION

Scimitar syndrome is a rare CHD characterized by the association of various cardiothoracic malformations and a wide clinical spectrum of presentation.

It is widely accepted that the infantile form, due to its severity, usually requires prompt intervention to relieve clinical symptoms, especially when associated with complex cardiovascular anomalies and PAH.<sup>3,12–16</sup>

However, many of these patients are incidentally diagnosed during infancy and adulthood and usually remain asymptomatic or mildly symptomatic for many years, leading a normal life without surgical repair.<sup>3,17–19</sup>

Surgical correction of the anomalous pulmonary venous return is usually accomplished in symptomatic patients or in patients with an increased pulmonary blood flow and signs of right heart chamber dilation and consists of redirection of the anomalous pulmonary venous connection into the left atrium or the removal of part of or the whole of the right lung in patients with severe clinical features.<sup>3,9,12</sup> When planning the most appropriate surgical approach, complete preoperative knowledge of the course of anomalous venous return and systemic collateral arteries is useful. However, surgery is not free of complications and, based on the suboptimal results of surgical repair from previous reports,<sup>3,4,20</sup> affected individuals require continuous clinical follow-up to assess their clinical status and the long-term patency of the scimitar vein.

With this concept in mind, based on multi-institutional data collection, we evaluated the clinical outcome of patients with scimitar syndrome who underwent follow-up of the natural history of the anomaly (without correction of scimitar vein drainage) with particular emphasis on patients with isolated forms: in our opinion, these latter patients represent a challenging subset of patients when choosing the ideal treatment option.

According to our results, the majority of patients (75%) had an isolated form of scimitar syndrome, which was diagnosed incidentally, and most were asymptomatic. In contrast, patients with associated CHDs had a greater association with preoperative CHF and more frequently had associated PAH. Overall, almost half of the patients had respiratory symptoms at diagnosis, with no

difference between patients with isolated forms and those with associated CHDs.

At the last follow-up visit, at a median of 6.4 years after the initial diagnosis, we found a significant decrease in the prevalence of respiratory symptoms, which mainly suggested a decreasing prevalence with age (20 of 44 [45.4%] at diagnosis vs 3 of 42 [7.1%] at follow-up). The surgical treatment of associated CHDs (leaving the anomalous venous connection intact and transforming an associated form to an isolated form of scimitar syndrome) proved safe and effective, with no significant difference in symptomatic patients between groups at the last follow-up visit. Notably, none of the patients in either group had signs of CHF at the final follow-up visit.

In agreement with previous reports, the presence of PAH is the most important prognostic factor in patient outcome and may be related to the presence of coexisting CHDs, to high resistances in the pulmonary vascular bed (where the pulmonary circulation fails to adapt normally after birth) and to a large shunt between abnormal arteries arising from the abdominal aorta and supplying the lower part of the right lung.<sup>4,21–24</sup> For this reason, therapeutic occlusion of any anomalous arterial supply to the lung, when demonstrated, should be accomplished either by preoperative coil embolization or at the time of surgical repair, thus reducing the amount of blood flow to the lungs and intracardiac shunts.<sup>25,26</sup>

## Limitations

The design of this study has some limitations. This was a retrospective study that included a medium-term follow-up evaluation of patients of all ages with scimitar syndrome. Cardiac catheterization was performed in only a few patients in our cohort; therefore, some important data such as the Qp:Qs and the median pulmonary artery pressure were not available in all patients. In addition, because data were collected in 9 centers, there may be interinstitutional and intrainstitutional variability in the evaluation of risk factors.

Nonetheless, we have collected a complete series of data on a relatively large series of patients who did not undergo surgical correction of their anomalous right pulmonary venous connection (scimitar drainage) and who underwent follow-up of the natural history of their anomaly in the context of a rare congenital heart malformation.

## CONCLUSIONS

Scimitar syndrome presents as an isolated lesion in the majority of patients who are usually asymptomatic. The correction of associated CHDs (transforming “associated” into “isolated” forms), together with therapeutic occlusion of anomalous arterial supply to the lung, may lead, in selected patients, to a benign outcome that is maintained over time, as in the primarily isolated forms. Nonetheless, when scimitar syndrome is associated with other CHDs and PAH there is an increased risk of CHF and mortality.

Continuous clinical and noninvasive follow-up is indicated in these patients to determine any clinical or physiological variations and to plan the most appropriate treatment.<sup>27,28</sup>

Because scimitar syndrome is almost always associated with right lung hypoplasia and the scimitar vein often carries a small amount of blood flow, surgical correction of the anomalous pulmonary venous return should be considered only when the scimitar drainage has been proven to cause a considerable amount of pulmonary overload. An angiographic study is recommended if there is persistence or worsening of clinical symptoms or if there is elevated pressure in the pulmonary arterial tree (by indirect measurement through two-dimensional echocardiography).

## CONFLICTS OF INTEREST

None declared.

## REFERENCES

- Kiely B, Filler J, Stone S, Doyle EF. Syndrome of anomalous venous drainage of the right lung to the inferior vena cava: a review of 67 reported cases and three new case in children. *Am J Cardiol.* 1967;29:102–16.
- Dupuis C, Charaf LA, Brevière GM, Abou P. "Infantile" form of the scimitar syndrome with pulmonary hypertension. *Am J Cardiol.* 1993;71:1326–30.
- Dupuis C, Charaf LA, Brevière GM, Abou P, Rémy-Jardin M, Helmius G. The "adult" form of the scimitar syndrome. *Am J Cardiol.* 1992;70:502–7.
- Hoffman JIE. The natural and unnatural history of congenital heart disease. Scimitar syndrome. Hoboken: Wiley-Blackwell; 2009: 161–6.
- Snellen HA, Van Ingen HC, Hoefsmit EC. Patterns of anomalous pulmonary venous drainage. *Circulation.* 1968;38:45–63.
- Folger GM. The scimitar syndrome. Anatomic, physiologic, developmental and therapeutic considerations. *Angiology.* 1976;27:373–407.
- Clements BS, Warner JO. Pulmonary sequestration and related congenital bronchopulmonary-vascular malformations: nomenclature and classification based on anatomical and embryological considerations. *Thorax.* 1987;42:401–8.
- Espinosa-Zavaleta N, Jativa-Chavez S, Munos-Castellanos L, Zamora-Gonzales C. Aspectos clínicos y ecocardiográficos del síndrome de la cimitarra. *Rev Esp Cardiol.* 2006;59:284–8.
- Alsoufi B, Cai S, Van Arsdell GS, Williams WG, Caldarone CA, Coles JG. Outcomes after surgical treatment of children with partial anomalous pulmonary venous connection. *Ann Thorac Surg.* 2007;84:2020–6.
- Vida VL, Speggorin S, Padalino MA, Crupi G, Marcelletti CF, Zannini L, et al. The scimitar syndrome: an Italian multicenter study. *Ann Thorac Surg.* 2009;88:440–4.
- Najm HK, Williams WG, Coles JG, Rebecky IM, Freedom RM. Scimitar syndrome: twenty years' experience and results of repair. *J Thorac Cardiovasc Surg.* 1996;112:1161–212.
- Vida VL, Padalino MA, Boccuzzo G, Tarja E, Berggren H, Carrel T, et al. The scimitar syndrome: A European Congenital Heart Surgeons Association (ECHSA) multi-centric study. *Circulation.* 2010;122:1159–66.
- Canter CE, Martin TC, Spray TL, Weldon CS, Strauss AW. Scimitar syndrome in childhood. *Am J Cardiol.* 1986;58:652–4.
- Huddleston CB, Exil V, Canter CE, Mendeloff EN. Scimitar syndrome presenting in infancy. *Ann Thorac Surg.* 1999;67:154–9.
- Gao YA, Burrows PE, Benson LN, Rabinovitch M, Freedom RM. Scimitar syndrome in infancy. *J Am Coll Cardiol.* 1993;22:873–82.
- Blaysat G, Kachaner J, Villain E, Sidi D, Pedroni E, Piechaud JF, et al. Scimitar syndrome in infants. Physiopathology and therapeutic implications in 12 cases. *Arch Fr Pediatr.* 1987;44:245–51.
- Tjang YS, Blanz U, Kirana S, Körfer R. Scimitar syndrome presenting in adults. *J Card Surg.* 2008;23:71–2.
- Dupuis C, Charaf LA, Abou CP, Brevière GM. Surgical treatment of the scimitar syndrome in children, adolescents and adults. A cooperative study of 37 cases. *Arch Mal Coeur Vaiss.* 1993;86:541–7.
- Huang SF, Yu WC, Chern JH, Lee YC. Scimitar syndrome in an older adult. *J Chin Med Assoc.* 2011;74:516–9.
- Benito Bartolomé F, González García A, Oliver Ruiz JM. Dilatación intraluminal de la estenosis de la vena cava inferior tras corrección del síndrome de la cimitarra en el adulto. *Rev Esp Cardiol.* 2002;55:190–2.
- Uthaman B, Abushaban L, Al-Qbandi M, Rathinasamy J. The impact of interruption of anomalous systemic arterial supply on scimitar syndrome presenting during infancy. *Catheter Cardiovasc Interv.* 2008;71:671–8.
- Haworth SG, Sauer U, Bühlmeier K. Pulmonary hypertension in scimitar syndrome in infancy. *Br Heart J.* 1983;50:182–9.
- Tummers RF, Lam J, Nijveld A, Marcelletti C, Losekoot G. An infant with the scimitar syndrome and pulmonary hypertension; successful surgical intervention. *Eur Heart J.* 1987;8:194–7.
- Nedelcu C, Carette MF, Parrot A, Hammoudi N, Marsault C, Khalil A. Hemoptysis complicating Scimitar Syndrome: from diagnosis to treatment. *Cardiovasc Interv Radiol.* 2008;31:S96–8.
- Muta H, Akagi T, Iemura M, Kato H. Coil occlusion of aortopulmonary collateral arteries in an infant with scimitar syndrome. *Jpn Circ J.* 1999;63:729–31.
- Ishibashi N, Takahashi Y, Kikuchi T, Kobayashi N, Suzuki R, Mizutani S. Case report of scimitar syndrome in infancy: intracardiac repair after coil embolization of systemic arterial supply to sequestered lung. *Kyobu Geka.* 2001;54:875–9.
- Espinola-Zavaleta N, Jativa-Chávez S, Muñoz-Castellanos L, Zamora-González C. Aspectos clínicos y ecocardiográficos del síndrome de la cimitarra. *Rev Esp Cardiol.* 2006;59:284–8.
- Pérez-David E, Mahía-Casado P, García-Fernández MA. Síndrome de la cimitarra: estudio con angiorresonancia magnética. *Rev Esp Cardiol.* 2006;59:1330.