

though 50 patients (66.6%) with echocardiographic NCC underwent cardiac magnetic resonance imaging to complete the study, the use of this technique was uneven across the cohort. Of note, NCC was confirmed in all the patients who underwent magnetic resonance imaging. Importantly, only a minority of our patients underwent genetic testing. Finally, the presence of neuromuscular disorders was not evaluated and all patients came from and were followed up at heart failure units; this may have created a possible selection bias which could influence the observed outcomes.

In conclusion, our study shows a nonsignificant effect of NCC on mortality compared with IDC in symptomatic adult patients being followed up at specialized heart failure units.

Joel Salazar-Mendiguchía,^{a,b,*} José González-Costello,^a Teresa Oliveras,^c Francisco Gual,^c Josep Lupón,^c and Nicolás Manito^a

^aÁrea de Enfermedades del Corazón, Hospital Universitario de Bellvitge, L'Hospitalet de Llobregat, Barcelona, Spain

^bDepartamento de Genética, Universitat Autònoma de Barcelona, Bellaterra, Cerdanyola del Vallès, Barcelona, Spain

^cServicio de Cardiología, Hospital Universitario Germans Trias i Pujol, Badalona, Barcelona, Spain

* Corresponding author:

E-mail address: jsalazarmg@gmail.com (J. Salazar-Mendiguchía).

Available online 27 December 2017

REFERENCES

1. Almeida A, Pinto FJ. Non-compaction cardiomyopathy. *Heart*. 2013;99:1535–1542.
2. Jenni R, Oechslin N, van der Loo B. Isolated ventricular non-compaction of the myocardium in adults. *Heart*. 2007;93:11–15.
3. Jenni R, Oechslin E, Schneider J, Attenhofer Jost C, Kaufmann PA. Echocardiographic and pathoanatomical characteristics of isolated left ventricular non-compaction: a step towards classification as a distinct cardiomyopathy. *Heart*. 2001;86:666–671.
4. Homma S, Thompson JL, Qian M, et al. Quality of anticoagulation control in preventing adverse events in heart failure patients in sinus rhythm: A Warfarin Aspirin Reduced Cardiac Ejection Fraction Trial (WARCEF) substudy. *Circ Heart Fail*. 2015;8:504–509.
5. Kohli S, Pantazis A, Shah JS, et al. Diagnosis of left-ventricular non-compaction in patients with left-ventricular systolic dysfunction: time for a reappraisal of diagnostic criteria? *Eur Heart J*. 2008;29:89–95.

<https://doi.org/10.1016/j.rec.2017.11.021>

1885-5857/

© 2017 Sociedad Española de Cardiología. Published by Elsevier España, S.L.U. All rights reserved.

Nanotechnology Applied to Preserve Extracellular Matrix as Teranostic Tool in Acute Myocardial Infarction



Nanotecnología aplicada a conservar la matriz extracelular como herramienta teranóstica en el infarto agudo de miocardio

To the Editor,

Hyperoxygenation after coronary reperfusion causes reperfusion injury, partly as a result of macrophage infiltration contributing to activation of extracellular matrix metalloproteinases (MMP), the main effectors of ventricular necrosis.¹ Extracellular-matrix-metalloproteinase-inducer (EMMPRIN) is an essential activation factor.² A murine coronary ischemia-reperfusion (IR) model has shown the importance of EMMPRIN as a target for the treatment of acute myocardial infarction,¹ and more recently, the use of EMMPRIN-targeted magnetic nanoparticles (Figure 1) has been shown to be a potential therapeutic tool for preventing necrosis.³ Before they are studied in a clinical setting, we aimed to evaluate the effectiveness of a porcine coronary IR model.

The study included 15 female Yorkshire albino pigs. Five of these were infarct-free. The remaining animals were anesthetized with intravenous administration of propofol 2 mL/kg/h and phentanyl 50 mg/kg/h and submitted to 45minutes of occlusion of the anterior descending artery by balloon inflation. The animals were then injected with 10mg/kg of nanoprobe NAP9 (containing EMMPRIN binding peptide AP9) or NAPSC (containing scramble peptide) as control (Figure 1A).³ Myocardial function was assessed before and 7 days after infarction by echocardiography. Tissue samples were examined for the presence of nanoparticles (confocal microscopy), myocardial integrity (histological staining with hematoxylin-eosin), necrotized area (staining with triphenyl tetrazolium), and EMMPRIN, MMP-9, and MMP-13 as necrosis markers.

Cytotoxicity was studied by injecting NAP9 at 0, 10, 50mg/kg and measuring serum concentrations of aspartate transaminase and alanine transaminase as markers of hepatic injury, creatinine as a renal marker, and creatine kinase MB isoenzyme as a marker of cardiac necrosis. Total absence of cytotoxicity occurred at a dose of 10mg/kg (Figure 1B). Biodistribution was analyzed by confocal microscopy of sections of heart, liver, kidney, pancreas, spleen, lung, bladder, and intestine after 7 days of IR (IR7); the heart and lung were the tissues with highest NAP9 uptake (Figure 1C).

The effect of NAP9 on progression of acute myocardial infarction was studied by injecting 10mg/kg of NAP9 or NPASC after 15minutes of reperfusion of the anterior descending artery. It was found that left ventricular ejection fraction (estimated in B mode by the Simpson biplane method and in M mode [Teichholz method], with similar results) of the pigs injected with NAP9 was significantly greater than in control animals (NAP9 IR7 vs control IR7, 51.7% [3.5%] vs 45.2% [2.2%]; $P < .05$) (Figure 2A). In contrast, the extent of the necrotized area, expressed as a percentage of the total surface of the left ventricle (control vs NAP9, 28.05% [3.68%] vs 16.08% [4.96%]; $P < .0003$) (Figure 2B) and expression of MMP-9 and MMP-13 (Figure 2C), indicative of necrosis due to extracellular matrix degradation, decreased in pigs treated with NAP9.

Nanotechnology applied to the treatment and prevention of reperfusion injury is an approach with promising clinical results.^{4,5} In conclusion, the extension of infarction was significantly reduced in the pigs that underwent coronary IR and received NAP9, and therefore ventricular function was at least improved through reduction of necrosis associated with degradation of the extracellular matrix. Before studying the approach in clinical trials, and bearing in mind the limitation of using echocardiography compared with magnetic resonance imaging for functional assessment of contractility, it would be necessary to increase the sample size of the study and, depending on the visibility of NAP9 in magnetic resonance imaging, complement the results by

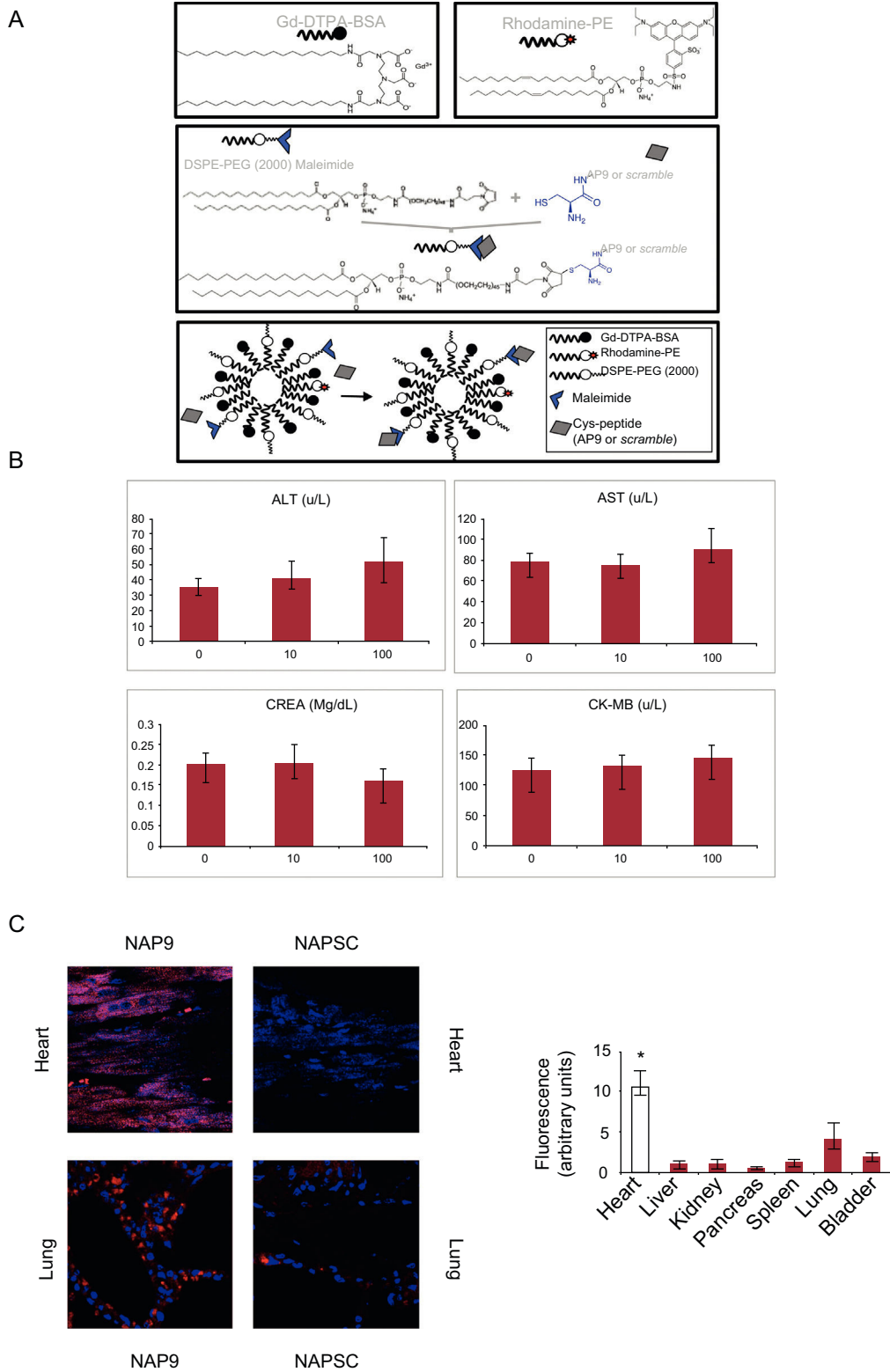


Figure 1. A, Structure of NAP9 or scramble control peptide (NAPSC). B, Production of ALT, AST, creatinine, and CK-MB after administration of 10 mg/kg of NAP9 (n = 5). C, Left panel, detection of NAP9 and NAPSC by confocal microscopy is shown in sections of heart and lung after 7 days of ischemia-coronary reperfusion and injection of 10 mg/kg of NAP9 or NAPSC. Right panel, distribution of NAP9 after 7 days of ischemia-coronary reperfusion and injection of 10 mg/kg of NAP9 in the tissues indicated (n = 10). The plots show mean (SD) values. ALT, alanine transaminase; AST, aspartate transaminase; CK-MB, creatine kinase MB isoenzyme; CREA, creatine kinase; NAP9, nanoparticles containing AP9; NASPC, scramble control peptide.

* $P > .05$, heart vs lung.

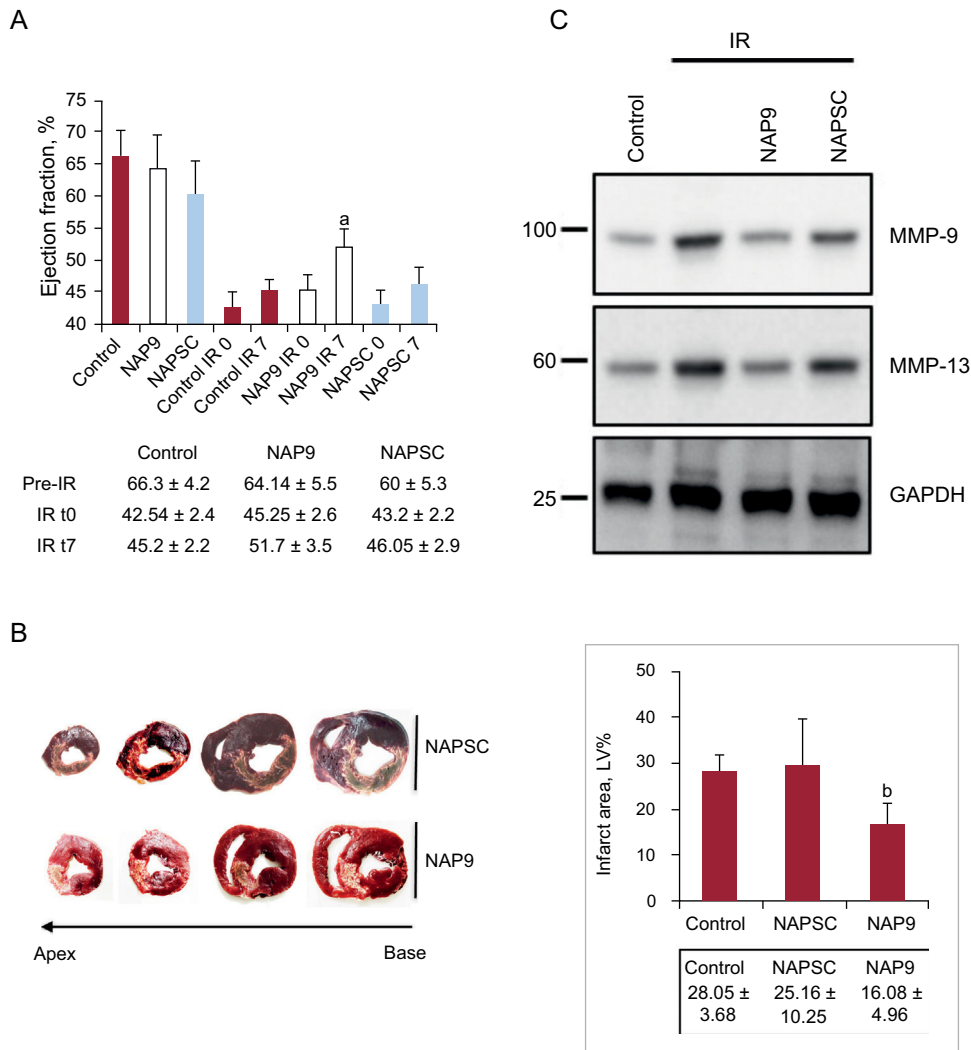


Figure 2. A, The upper panel shows left ventricular ejection fraction (mean [SD]) of pigs without infarction or infarcted and injected or not injected with 10 mg/kg of NAP9 or NAPSC (n = 15). The lower panel shows the values of ejection fraction prior to the procedure, after ischemia-reperfusion (IR0) and after 7 days of IR (IR7). B, The left panel shows serial 0.5 cm sections of the hearts of the pigs injected with NAP9 or NAPSC microprobes. The right panel shows the values (mean [SD]) of the infarcted area expressed as percentage of the total ventricular volume (n = 15). C, Detection of metalloproteinases MMP-9 and MMP-13 in the hearts of pigs injected with NAP9 or NAPSC after 7 days of IR. GAPDH was used as control (n = 15). GAPDH, glyceraldehyde 3-phosphodehydrogenase; IR, ischemia/reperfusion; MMP, metalloproteinases; NAP9, AP9 peptide; NASC, scramble peptide; LV, left ventricle.

^a NAP9 IR7 vs control IR7, *P* < .05.

^b NAP9 vs control, *P* < .0003.

noninvasive means with magnetic resonance imaging. This would enable molecular imaging to be used in the future as a tool to assess the utility of EMMPRIN in the treatment of acute myocardial infarction.

FUNDING

This study received a grant from the Spanish Society of Cardiology project in 2016.

Rafael Ramírez,^a Javier Díez,^a Marcelo Sanmartín,^b Marta Saura,^b José Luis Zamorano,^b and Carlos Zaragoza^{a,*}

^aServicio de Cardiología, Unidad de Investigación del Hospital Ramón y Cajal (IRYCIS)-Universidad Francisco de Vitoria, Madrid, Spain

^bServicio de Cardiología, Hospital Universitario Ramón y Cajal (IRYCIS)-Universidad de Alcalá de Henares, Madrid, Spain

* Corresponding author:

E-mail address: c.zaragoza.prof@ufv.es (C. Zaragoza).

Available online 9 April 2018

REFERENCES

- Tarin C, Lavin B, Gomez M, et al. The extracellular matrix metalloproteinase inducer EMMPRIN is a target of nitric oxide in myocardial ischemia/reperfusion. *Free Radic Biol Med.* 2011;51:387–395.
- Schmidt R, Bültmann A, Ungerer M, et al. Extracellular matrix metalloproteinase inducer regulates matrix metalloproteinase activity in cardiovascular cells: implications in acute myocardial infarction. *Circulation.* 2006;113:834–841.

3. Cuadrado I, Piedras MJ, Herruzo I, et al. EMMPRIN-targeted magnetic nanoparticles for in vivo visualization and regression of acute myocardial infarction. *Theranostics*. 2016;6:545–557.
4. Yilmaz A. Visualising inflammation after myocardial infarction with the use of iron oxide nanoparticles. *Heart*. 2017;103:1479–1480.
5. Yilmaz A, Rösch S, Yildiz H, et al. First multiparametric cardiovascular magnetic resonance study using ultrasmall superparamagnetic iron oxide nanoparticles in a patient with acute myocardial infarction: new vistas for the clinical

application of ultrasmall superparamagnetic iron oxide. *Circulation*. 2012;126:1932–1934.

<https://doi.org/10.1016/j.rec.2017.12.023>
1885-5857/

© 2017 Sociedad Española de Cardiología. Published by Elsevier España, S.L.U. All rights reserved.

Extracorporeal Membrane Oxygenation Support During Pregnancy in Pulmonary Veno-occlusive Disease



Soporte circulatorio con oxigenador extracorpóreo de membrana durante el embarazo en la enfermedad venooclusiva pulmonar

To the Editor,

An 18-year-old woman with heritable pulmonary veno-occlusive disease (PVOD) (homozygous carrier of the c.3344C>T(p.P1115L) founder mutation in the *EIF2AK4* gene¹ [Figure A]) was urgently admitted due to clinical worsening during the last few weeks with presyncope and angina on exertion, third heart sound, an increase in N-terminal pro-B-type natriuretic peptide levels up to 1400 pg/mL, and respiratory insufficiency despite oxygen therapy. Previous treatment with pulmonary vasodilator therapy had to be discontinued due to increased dyspnea and signs of pulmonary edema. Although the patient was advised about contraception, at admission she was pregnant (22nd week of gestation), with 2 previous spontaneous abortions. Although the risk-benefit ratio was explained, she refused to undergo a therapeutic abortion. Despite increasing oxygen supply, intravenous furosemide and inotropes, clinical signs of right heart failure and low cardiac output persisted, while respiratory insufficiency worsened, requiring an increase in fraction of inspired oxygen up to 100%. Transthoracic echocardiogram showed a severely dilated and hypertrophic right ventricle (Figure B-C) with severely impaired function. Gynecological evaluation was performed without signs of fetal distress. The case was discussed with the Heart Team and, since the clinical course was mainly determined by refractory hypoxemia, venovenous extracorporeal membrane oxygenation (VV-ECMO) support and lung transplantation (LTx) evaluation were decided. Due to the high risk of pregnancy, the patient was again advised about therapeutic abortion, but she decided to continue with the pregnancy, and therefore the case was discussed with the obstetricians and elective cesarean delivery was planned when fetal viability could be guaranteed (at least 24 weeks of gestation). Until delivery, fetal monitoring was performed with obstetric ultrasound and ultrasound for fetal heart rate detection because conventional external monitoring is practically impossible to perform due to the high fetal mobility in those weeks of gestation. Right femoral-right internal jugular vein VV-ECMO was the preferred cannulation configuration with normal decubitus position. After 24 hours of clinical stabilization, cesarean delivery was performed (24th week of pregnancy) with no hemorrhagic or thrombotic complications. During the following days, respiratory and hemodynamic improvement allowed inotropic and VV-ECMO withdrawal after 10 days of support. In the meantime, LTx evaluation was performed and after careful assessment of

comorbidities, LTx was rejected due to high preformed human leukocyte antigen class I cytotoxic antibodies with an estimated panel reactive antibody higher than 50%, which contraindicates national prioritization on the LTx waiting list. After VV-ECMO removal, the patient showed worsening of respiratory (increased oxygen demand and mechanical ventilation) and hemodynamic parameters (mean pulmonary artery pressure = 53 mmHg, cardiac output = 2.4 L/min and right atrial pressure = 30 mmHg) without response to medical treatment, finally dying 24 hours later. Unfortunately, the newborn also died within the first 24 hours after cesarean delivery.

PVOD is a rare cause of pulmonary hypertension (PH), which is part of the special designation (subgroup 1') within the PH group 1.² Despite advances in noninvasive diagnosis and knowledge of the genetic basis in the last decade, PVOD remains a rare etiology of PH. There is no approved effective medical treatment and outcomes are poor.³ LTx is the only definitive treatment, with some patients needing extracorporeal circulatory support prior to LTx due to severe respiratory failure. Although ECMO has been increasingly used in the last few years to treat patients with cardiopulmonary failure, there is a lack of evidence about its use in some specific populations, such as pregnant women. Outcomes in this population are limited to small case series and case reports with favorable maternal and fetal survival rates but high hemorrhagic or thrombotic complications.^{4,5} In a recent comprehensive literature review of all reported cases of ECMO support during pregnancy, Moore et al.⁵ reported maternal and fetal survival rates of 78% and 65%, respectively. In that review, a total of 45 patients were treated with ECMO during pregnancy and the main indication for ECMO support was severe H1N1 influenza complicated with acute respiratory distress syndrome (73%). VV-ECMO support was used in as many as 91% of the cases reported with a median gestational age of 26.5 weeks and median duration of support of 12.2 days.⁵ As in nonpregnant adults, the most common ECMO-related complication was bleeding, with major bleeding rates of 57%.⁶ Interestingly, there were no differences in maternal or fetal mortality rates according to the time of ECMO implantation (second vs third trimester) or the type of ECMO cannulation (VV-ECMO vs venoarterial ECMO).⁶ However, these results could have been influenced by the small sample size and the likelihood of publication bias. In the present work, we describe what is, to best of our knowledge, the first reported case of cesarean delivery during VV-ECMO support in a pregnant woman with PH due to PVOD.

In conclusion, in experienced centers with a multidisciplinary approach, ECMO support can be used during pregnancy with good maternal and fetal outcomes. Of note, a delivery plan should be prepared for all pregnant patients who receive ECMO, considering both maternal and fetal clinical status. However, the widespread use of ECMO in this population warrants further investigation.