

# Myocardial Echocardiography With Intracoronary Injection of Contrast in Post-Infarction Patients. Implications and Comparison With Angiography and Magnetic Resonance Imaging

Vicent Bodí,<sup>a</sup> Juan Sanchís,<sup>a</sup> María P. López-Lereu,<sup>b</sup> Àngel Llúcer,<sup>a</sup> Mauricio Pellicer,<sup>a</sup> Antonio Losada,<sup>a</sup> Vicente Bertomeu,<sup>a</sup> David Moratal,<sup>c</sup> José Millet,<sup>c</sup> Luis Insa,<sup>a</sup> and Francisco J. Chorro<sup>a</sup>

<sup>a</sup>Servicio de Cardiología, Hospital Clínic i Universitari, Universitat de València, Valencia, Spain.

<sup>b</sup>Resonancia Magnética Cardíaca, Eresa, Valencia, Spain.

<sup>c</sup>Departamento de Ingeniería Electrónica, Universidad Politécnica, Valencia, Spain.

**Objectives.** We analyzed the safety and feasibility of myocardial echocardiography with intracoronary injection of contrast, its effect on left ventricular remodeling and systolic function, and its relationship with angiography and magnetic resonance imaging (MRI) for the evaluation of post-infarction coronary microcirculation.

**Patients and method.** Thirty patients with a first ST-elevation myocardial infarction and a patent infarct-related artery were studied. Mean perfusion score of the infarcted area was analyzed with myocardial echocardiography. TIMI and Blush grades (angiography) were determined. Mean perfusion score (MRI-perfusion), end-diastolic volume index and ejection fraction were determined with MRI. At 6 months all studies were repeated in the first 17 patients.

**Results.** Forty-seven perfusion studies (30 in the first week and 17 after 6 months) were done without complications (6 [2] min per myocardial echocardiography study). Normal perfusion (myocardial echocardiography 0.75) was detected in 67% of the patients. Myocardial echocardiography was the best predictor of end-diastolic volume ( $r=-0.69$ ;  $P=.002$ ) and ejection fraction ( $r=0.72$ ;  $P=.001$ ) after 6 months. Normal perfusion was observed in 80% of the patients with TIMI grade 3, and in 14% of those with TIMI grade 2. Of the 40 studies in patients with TIMI grade 3, normal perfusion was seen in 85% of the patients with Blush grade 2-3 and in 50% of those with Blush 0-1. Perfusion was also normal in 90% of the patients with MRI-perfusion = 1 and in 62% of those with MRI-perfusion < 1.

**Conclusions.** Myocardial echocardiography is a feasible and relatively rapid technique with no side effects. This technique provided the most reliable perfusion index for predicting late left ventricular remodeling and systolic function. To achieve normal perfusion, TIMI grade 3 is necessary but does not

guarantee success. In patients with TIMI grade 3, a normal Blush score or a normal MRI-perfusion study suggests good reperfusion.

**Key words.** *Infarction. Perfusion. Echocardiography. Magnetic resonance imaging.*

Full English text available at: [www.revespcardiol.org](http://www.revespcardiol.org)

## Estudio de perfusión en pacientes postinfarto mediante ecografía miocárdica con inyección de contraste intracoronario. Implicaciones y relación con la angiografía y la resonancia magnética

**Objetivos.** Analizamos la aplicabilidad y seguridad de la ecografía miocárdica con inyección intracoronaria de contraste, su papel en la remodelación ventricular y en la función sistólica, así como su relación con la angiografía y la resonancia magnética para valorar la microcirculación coronaria postinfarto.

**Pacientes y método.** Se estudió a 30 pacientes con un primer infarto de miocardio con elevación del segmento ST y arteria responsable abierta. Con inyección intracoronaria de contraste se determinó la puntuación media de perfusión en la zona infartada. Mediante angiografía se cuantificaron los grados TIMI y Blush. Se utilizó la resonancia magnética para determinar la puntuación media de perfusión (RM-perfusión), el índice de volumen telediastólico y la fracción de eyección. Al sexto mes se repitieron todas las exploraciones en los primeros 17 pacientes.

**Resultados.** Se realizaron 47 estudios de perfusión (30 en la primera semana y 17 en el sexto mes) sin complicaciones ( $6 \pm 2$  min por estudio de inyección intracoronaria de contraste). Se observó una perfusión normal (inyección intracoronaria de contraste > 0,75) en el 67% de los casos. La inyección intracoronaria de contraste fue el mejor predictor de volumen telediastólico ( $r = -0,69$ ;  $p = 0,002$ ) y de fracción de eyección ( $r = 0,72$ ;  $p = 0,001$ ) al sexto mes. Hubo perfusión normal en el 80% de los casos con TIMI 3 y en el 14% de los casos con TIMI 2. Entre los 40 estudios con TIMI 3 se observó una perfusión normal en el 85% de casos con un índice de Blush de 2-3 y en el 50% de aquellos con un índice de

SEE EDITORIAL ON PAGES 4-6

Correspondence: Dr. V. Bodí.  
Servicio de Cardiología. Hospital Clínic i Universitari.  
Avda. Blasco Ibáñez, 17. 46010 Valencia. España.  
E-mail: vicentbodi@hotmail.com

Received 27 May, 2003.

Accepted for publication 30 October, 2003.

## ABBREVIATIONS

$\Delta$ VTD: increase in end-diastolic volume from week 1 to month 6.

EF: ejection fraction.

MCE: myocardial contrast echocardiography.

MRI: magnetic resonance imaging.

EDV: end-diastolic volume.

Blush de 0-1, así como en el 90% de casos con RM-perfusión = 1 y en el 62% con RM-perfusión < 1.

**Conclusiones.** La inyección intracoronaria de contraste es factible con un escaso consumo de tiempo y sin efectos secundarios; asimismo, fue el índice de perfusión más fiable para predecir la remodelación y la función sistólica tardía. Para lograr una perfusión normal es indispensable (aunque no una garantía) que el paciente se encuentre con flujo TIMI 3. En los casos con TIMI 3, la normalidad en el índice Blush o en el estudio de perfusión con resonancia magnética sugiere una buena reperfusión.

**Palabras clave:** Infarto. Perfusión. Ecocardiografía. Resonancia magnética.

## INTRODUCTION

In the last 20 years, treatment for acute myocardial infarction has focused on eliminating the thrombus that impedes epicardial blood flow.<sup>1-4</sup> Recent studies have, however, shown that microcirculation has been affected in as many as a third of patients even when angiography suggests good reperfusion.<sup>5,6</sup> This “no-reflow” phenomenon has many causes and has been associated with worse prognosis in patients with successful reperfusion as indicated by angiography (thrombolysis in myocardial infarction [TIMI] grade 3 flow).<sup>5-14</sup>

Microcirculation has been reliably evaluated by echocardiographic study of myocardial perfusion after intracoronary injection of contrast, a technique known as myocardial contrast echocardiography (MCE).<sup>5-8,12,15</sup> The objectives of the present study were: *a*) to assess the safety of this technique and its applicability in a catheterization laboratory; *b*) to determine whether the technique could better predict ventricular dilation and late systolic function compared to normal perfusion indices, and *c*) to study the usefulness of this technique combined with angiography and magnetic

resonance imaging (MRI) in the assessment of coronary perfusion after infarction.

## PATIENTS AND METHODS

### Study Population

We studied 30 patients who suffered their first acute myocardial infarction with ST-segment elevation. Infarction was evidenced by typical chest pain lasting more than 30 minutes, with ST-segment elevation >1 mm at 80 ms after the J point in more than one lead that was unresponsive to nitroglycerin, and increase in markers of myocardial damage. The study was approved by the ethics committee of our institution and all patients gave their informed consent prior to enrollment.

Patients with a known history of heart disease (whether ischemic or not), concomitant diseases that might interfere with long-term follow-up, significant disease of an artery other than the infarct-related one (lesion >50% in the coronary angiography) or non-patent infarct-related artery on completion of catheterization prior to discharge were excluded from the study.

Thrombolytic treatment was administered within six hours of the onset of symptoms in 20 patients (67%). All patients received treatment with acetylsalicylic acid, beta-blockers and angiotensin converting enzyme inhibitors (or angiotensin receptor antagonists in case of contraindication) from the first 24 hours until follow-up was complete. The baseline characteristics of the patient population are presented in Table 1.

TABLE 1. Characteristics of the Study Group (n=30)\*

Men	26 (87%)
Age, years	54±10
Smoker	23 (77%)
Arterial hypertension	11 (37%)
Hypercholesterolemia	11 (37%)
Diabetes	6 (20%)
Thrombolysis	20 (67%)
Anterior infarction	20 (67%)
Anterior proximal descending	7 (23%)
Precatheterization stenosis, %	80±27
Postcatheterization stenosis, %	19±20
Precatheterization TIMI 3	16 (53%)
Postcatheterization TIMI 3	27 (90%)
Postcatheterization blush grade 2-3	24 (80%)
Stent	22 (73%)
Glycoprotein IIb-IIIa inhibitors	6 (20%)
Creatinine, mg/dL	0.9±0.2
Ejection fraction, %	47±12
CK-MB weight, ng/ml	273±193

\*CK-MB indicates creatinine kinase MB isozyme.

## Cardiac Catheterization

Cardiac catheterization was performed prior to discharge (median, 6 days after infarction; range, 3-9 days). Catheterization was repeated before discharge in the 3 patients (10%) who underwent rescue angioplasty. Thus, the information from catheterization was obtained from 3 to 9 days after the onset of symptoms.

Right femoral approach was used for the catheterization study. Quantitative analysis was performed with the software of the Integris HM-3000 digital equipment (Philips, Holland). Patients with a fully occluded (n=14) or >50% occluded infarct-related artery underwent revascularization with stent placement. After completion of angioplasty (or the diagnostic study if stenosis was negligible) and with the epicardial artery patent, angiographic studies were performed (with administration of intracoronary nitroglycerin) in the optimal projection for analysis of the infarct-related artery. An experienced observer who was blinded to the findings of the other examinations subsequently assessed the TIMI flow (grade 2 or 3) and myocardial blush grade (0: no myocardial blush after injection of contrast; 1: minimal myocardial blush; 2: myocardial blush less than that obtained from a non-infarct-related artery; 3: normal myocardial blush). A TIMI flow of 3<sup>16</sup> and a myocardial blush grade of 2 or 3 were considered normal.<sup>13</sup> Consensus with a second observer was sought in case of doubt. Inter-observer variability in the assessment of normal perfusion (TIMI flow 3 and myocardial blush grade 2 or 3) was analyzed in 10 patients. Agreement was found in 9 out of 10 patients.

## Myocardial Contrast Echocardiography

When assessment of the degree of angiographic perfusion was complete, second harmonic MCE was performed with the Ving Med 750 echocardiograph (General Electrics, United States) in real time. The images were recorded on super-VHS tape and processed digitally for analysis. Gain, depth and compression were kept constant. Two intracoronary boluses of 1 ml of sonicated galactose followed by 5 mL of physiological serum were administered via a catheter in the infarct-related artery. The first bolus was for parasternal assessment (longitudinal and transversal) and a second bolus for two- and four-chamber apical assessment.

A third bolus was administered in cases of doubt. The infarct-related artery was divided into 16 segments and a semiquantitative perfusion grade was assigned to the anterior, inferior or lateral segments of the infarct zone.<sup>17</sup> Each segment of the infarct zone was assigned a grade of 1 (normal contrast uptake), 0.5 (patchy contrast uptake) or 0 (no uptake). The

grade in each case corresponded to the mean grade of all segments of the infarct zone. Perfusion was considered normal if the MCE grade was greater than 0.75. Previous studies have considered a perfusion deficit after revascularization of less than 25% of the area at risk (the area with no perfusion prior to primary angioplasty) as normal.<sup>6</sup> The perfusion calculations with MCE were performed by an experienced observer who was unaware of the findings of the other assessments. In case of doubt, consensus was reached with a second observer. Inter-observer variability in the assessment of normal perfusion (MCE>0.75) was analyzed in 10 patients. Agreement was reached in all 10 cases.

## Cardiac Magnetic Resonance Imaging

A study was performed with cardiac MRI (Sonata 1.5 Tesla, Siemens, Germany) in 27 patients a median of 9 days (range, days 6-12) after the infarction, and at least 24 hours after catheterization. Three patients did not undergo MRI because of claustrophobia. The end-diastolic volume (EDV) in mL/m<sup>2</sup> was determined by the Simpson method. The ejection fraction (%EF) was also determined. The mean perfusion grade (MRI-perfusion) was determined on the same semiquantitative scale as MCE by analyzing the early (first minute) uptake of gadolinium in the segments of the infarct zone. A gadolinium dose of 0.1 mmol/L was used and a True-FISP sequence was applied. The best cut-point for the receiver operator characteristics (ROC) curve for predicting normal perfusion with MCE (>0.75) was determined. An MRI-perfusion grade of 1 was taken as normal perfusion. All investigations were performed by an experienced observer who was unaware of the findings of the other examinations. In case of doubt, consensus with a second observer was obtained. Inter-observer variability in the assessment of normal perfusion (MRI-perfusion grade=1) was analyzed in 10 patients. Agreement was obtained in nine out of the 10 studies. Interobserver differences with respect to EF and EDV were likewise assessed in 15 patients. Minimal differences were detected in both EF (3.4±2.2%) and EDV (5.5±5 mL/m<sup>2</sup>).

## Follow-Up

All patients were followed up in cardiology outpatient clinics of our institution. Catheterization, MCE and MRI were repeated in the first 17 patients (all with patent infarct-related artery at month 6).

## Statistical Analysis

Continuous variables were expressed as mean±standard deviation and compared by the Student

*t* test for unpaired data. The categorical variables were expressed as percentages of the study population and compared by the  $\chi^2$  test. Perfusion was considered normal if MCE>0.75. Sensitivity (percentage of the patients with MCE>0.75 and TIMI grade 3 flow), specificity (percentage of patients with MCE<0.75 and TIMI flow<3), positive predictive value (percentage of patients with TIMI grade 3 flow and MCE>0.75) and negative predictive value (percentage of patients with TIMI flow <3 and MCE<0.75) for detection of normal perfusion (MCE>0.75) with respect to myocardial blush grades 2 to 3 and MRI-perfusion grade 1. Simple univariate regression analyses were performed (with calculation of the Pearson coefficient and its significance).

Multivariate linear regression with simultaneous inclusion of variables was used to determine which of the four angiographic grading systems assessed (TIMI, myocardial blush grade, MCE and MRI) independently predicted EDV and EF at month 6 after infarction and the increase in EDV from week 1 to month 6 ( $\Delta$ VTD). The coefficient of determination R<sup>2</sup> was calculated in the multivariate analysis. All calculations were performed using the SPSS 9.0 statistics package (Chicago, Illinois, United States). For all tests, *P*<.05 were considered significant.

## RESULTS

### Myocardial Contrast Echocardiography

TABLE 2. Differences Between Patients With Normal Perfusion (MCE>0.75) and Impaired Perfusion (MCE<0.75) in the Pre-Discharge Study\*

	MCE>0.75	MCE<0.75	<i>P</i>
Number of patients	20 (67%)	10 (33%)	
Men	17 (85%)	9 (90%)	NS
Age, years	53±10	57±10	NS
Smoker	17 (85%)	6 (60%)	NS
Arterial hypertension	4 (20%)	7 (70%)	.02
Hypercholesterolemia	8 (40%)	3 (30%)	NS
Diabetes	4 (20%)	2 (20%)	NS
Anterior infarction	11 (55%)	9 (90%)	.100
TIMI 3	20 (100%)	7 (70%)	.050
Blush grade 2-3	18 (90%)	6 (60%)	.100
MRI perfusion grade 1	9 (53%)	1 (10%)	.040
EDV week 1, mL/m <sup>2</sup>	63±20	76±16	.100
EDV month 6, mL/m <sup>2</sup>	56±12	79±19	.020
	(n=10)	(n=7)	
EF week 1, %	53±11	39±9	.002
EF month 6 %	55±8	40±13	.030
	(n=10)	(n=7)	

\*EF indicates ejection fraction; MCE, perfusion grade derived from myocardial contrast echocardiography; NS, not significant (*P*>.1 in all cases); MRI-perfusion grade, perfusion grade derived from magnetic resonance imaging; EDV, end-diastolic volume.

Forty-seven MCE perfusion studies were performed (30 in week 1 and 17 at month 6). The time taken to complete the study (once the diagnostic and/or therapeutic catheterization had been completed) was 6±2 minutes. There were no complications. Poor perfusion (MCE<0.75) in the study prior to discharge was found in 10 of the 30 patients of the study group (33%). Table 2 presents the differences between patients with and without good reperfusion.

For the 17 patients with reassessment of MCE at month 6 (all with patent infarct-related artery), a clear tendency towards improved MCE compared with week 1 was found (MCE: 0.73±0.34 at week 1 compared to 0.82±0.32 at month 6 [*P*=0.07]).

### Angiography

The pre-discharge diagnostic catheterization showed TIMI flow 3 in 16 patients (53%). Thirteen of the 20 patients (65%) who were treated with thrombolytics and three of the 10 who received no thrombolytic treatment (30%) presented TIMI flow 3. When the week-1 catheterization was finished, all patients showed a patent infarct-related artery (27 out of 30 [90%] with TIMI flow 3 and three out of 30 [10%] with TIMI flow 2).

Good reperfusion, defined as MCE>0.75, was seen in the first week in 20 out of 27 (74%) patients with TIMI flow 3 compared to none out of the three patients with TIMI flow 2 (*P*=.05). In the 47 perfusion studies (30 in week 1 and 17 in month 6), MCE>0.75 was seen in 80% of the patients with TIMI flow 3 and 14% of those with TIMI flow 2 (*P*=.002; Figure 1). Given that TIMI flow 2 clearly indicated poor reperfusion, our comparison of the different methods for study of perfusion included only patients with TIMI flow 3.

Of the 40 patients with TIMI flow 3 (27 in week 1 and 13 in month 6), 34 (85%) had a myocardial blush grade of 2 to 3 and six (15%) had a blush grade of 0 to 1. The presence of myocardial blush grade 2 to 3 was associated with a higher probability of good reperfusion (MCE>0.75)—85% versus 50% in patients with a myocardial blush grade of 0 to 1 (*P*=.07; Figure 1). A myocardial blush grade of 2 to 3 showed a sensitivity of 91%, a specificity of 37%, a positive predictive value of 85% and a negative predictive value of 50% for detecting MCE>0.75. A significant improvement in the myocardial blush grade was observed from week 1 to month 6 in the 17 reevaluated patients (1.82±1.24 vs 2.53±0.87; *P*=.02).

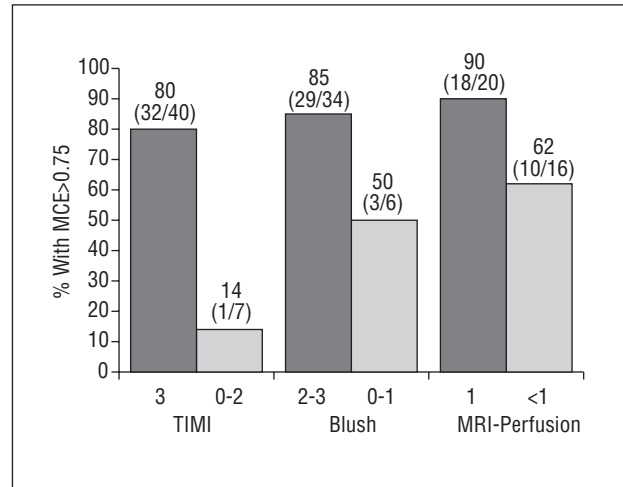
### Magnetic Resonance Imaging

Of the 36 perfusion studies performed with MRI in patients with TIMI flow 3, normal perfusion (MRI-perfusion grade=1) was observed in 20 patients (56%)

and abnormal perfusion (MRI-perfusion grade <1) in 16 patients (44%). A greater probability of reperfusion (MCE>0.75) was found in patients with MRI-perfusion grade 1 (90% compared to 62% in patients with MRI-perfusion grade<1; *P*=.1; Figure 1). Normal perfusion in the MRI examination showed a sensitivity of 64%, a specificity of 75%, a positive predictive value of 90% and a negative predictive value of 37% for detection of reperfusion (MCE>0.75). A tendency towards improvement in the degree of perfusion analyzed with MRI from week 1 to month 6 was observed in the 17 reevaluated patients (0.76±0.33 compared to 0.88±0.19; *P*=.2).

**Follow-Up and Relationship Between Perfusion Grade and Ejection Fraction and End-Diastolic Volume**

No event was reported (death, readmission because of acute coronary syndrome or for revascularization) during the first 6 months. The 17 reevaluated patients had a patent infarct-related artery at month 6 (TIMI flow 3 in 13 patients, TIMI flow 2 in four patients). The only independent predictor was MCE in the analysis of the correlation between the four perfusion grades (TIMI, myocardial blush, MRI and MCE) and EDV and EF in week 1 and at month 6 (Table 3). Of the different grades, MCE correlated best with increase in EDV (*P*=.07) but it was not an independent predictor (Table 3).



**Figure 1.** Percentage of the patients with normal perfusion (MCE>0.75) according to TIMI, blush and MRI-perfusion grades. The results for TIMI flow refer to the 47 studies performed. The results for the myocardial blush and MRI-perfusion grades refer to the 40 studies of patients with TIMI 3. MCE indicates perfusion grade derived from myocardial contrast echocardiography; MRI-perfusion, perfusion grade derived from magnetic resonance imaging.

The MCE at month 6 correlated strongly with EDV (*r*=-0.79; *P*<.0001), EF (*r*=0.78; *P*<.0001) and increase in EDV from week 1 to month 6 (*r*=-0.68; *P*=.003) (Table 3, Figure 2). When the four perfusion grades (TIMI, myocardial blush, MRI and MCE) at

**TABLE 3. Univariate and Multivariate Linear Regression (With Simultaneous Inclusion of Variables) Between Perfusion Grades and Ejection Fraction (Month 6), End-Diastolic Volume (Month 6) and Increase in End-Diastolic Volume From Week 1 to Month 6 in the 17 Patients With Complete Follow-Up (All With Patent Artery at Month 6)\***

	EDV		EF		ΔEDV	
	r	P	r	P	r	P
First model (week 1)						
MCE	-0.69	.002*	0.72	.001*	-0.45	.07
TIMI	-0.41	.1	0.35	NS	-0.36	NS
Blush grade	-0.20	NS	0.58	.01	0.1	NS
MRI-perfusion grade	-0.51	.04	0.65	.005	-0.1	NS
R <sup>2</sup>	0.57	.03	0.69	.004	0.33	NS
Second model (week 6)						
MCE	-0.79	<.0001*	0.78	<.0001*	-0.68	.003*
TIMI	-0.58	.02	0.56	.02	-0.48	.06
Blush grade	-0.54	.03	0.53	.03	-0.31	NS
MRI-perfusion grade	-0.2	NS	0.55	.02	-0.1	NS
R <sup>2</sup>	0.70	.006	0.70	.006	0.61	.02

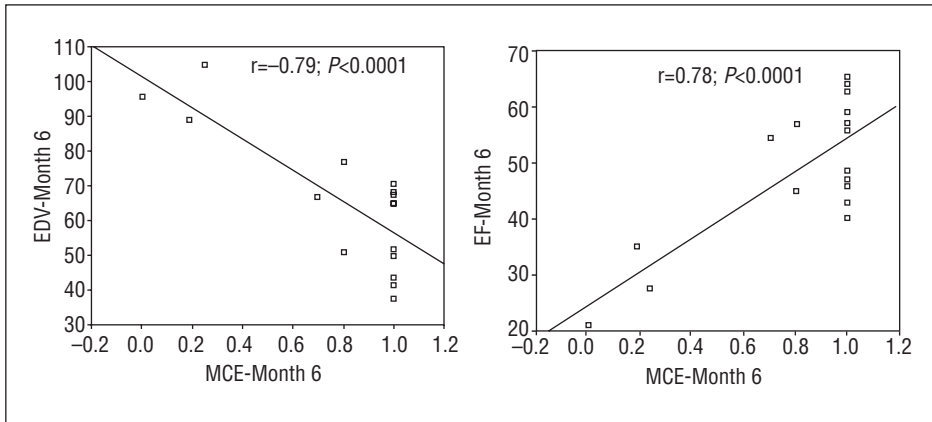
\*EF indicates ejection fraction; MCE, perfusion grade derived from myocardial contrast echocardiography; NS, not significant (*P*>.1 in all cases); MRI-perfusion grade, perfusion grade derived from magnetic resonance imaging; R<sup>2</sup>, coefficient of determination that indicates percentage of the dependent variable explained by the independent variables included in the regression; EDV, end-diastolic volume; ΔEDV, increase end-diastolic volume from week 1 to month 6. \*Independent predictor in the multivariate analysis.

All variables were analyzed as continuous variables.

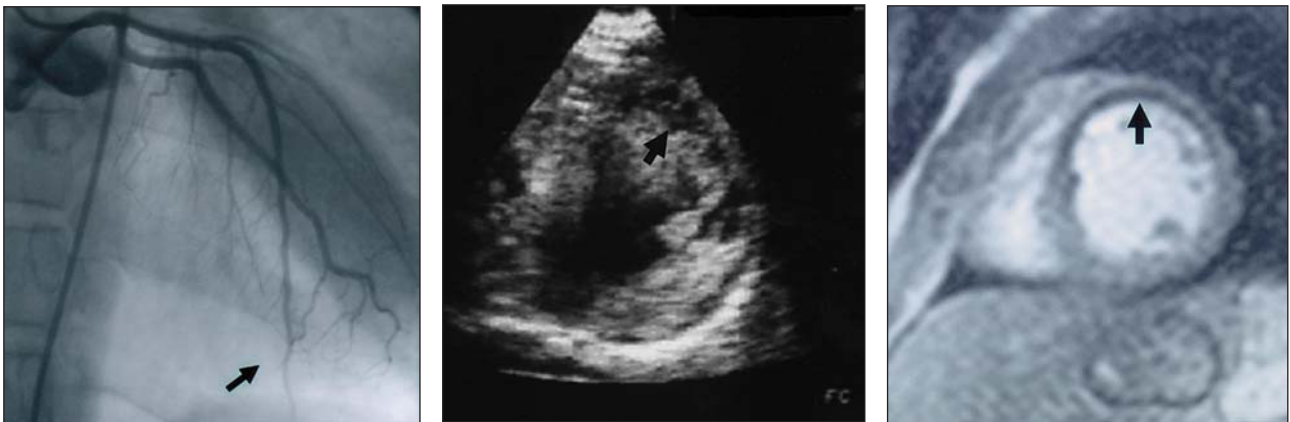First model: the 4 perfusion grades analyzed in week 1 were included.

Second model: the 4 perfusion grades analyzed in week 1 are added to the value of the perfusion grades determined at month 6.

The correlation coefficients (*r*) and the level of significance (*P*) in the univariate analysis are presented for each grade. The coefficient of determination R<sup>2</sup> is presented in the last row of each model with the level of significance of the final regression in the multivariate analysis.



**Figure 2.** Plot of linear regression between MCE (analyzed at month 6) and EF and EDV (determined at month 6 by magnetic resonance imaging). EF indicates ejection fraction; MCE, perfusion grade derived from myocardial contrast echocardiography; EDV, end-diastolic volume



**Figure 3.** Left: patent descending anterior coronary artery but with blush grade 0 (arrow). Centre: myocardial echocardiographic study with left coronary contrast injection in patient with anterior infarction and no reflow (arrow). Right: magnetic resonance imaging in same patient with no reflow (arrow).

month 6 were included in the multivariate model with the four perfusion grades at week 1, MCE at month 6 was the only independent predictor of EDV ( $R^2=0.70$ ;  $P=.006$ ), EF ( $R^2=0.70$ ;  $P=.006$ ) and increase in EDV ( $R^2=0.61$ ;  $P=.02$ ) (Table 3).

## DISCUSSION

In recent years it has become evident that, even in best case scenario of good angiographic reperfusion (TIMI flow 3),<sup>16</sup> blood flow to the ischemic area is impeded because of microvascular damage.<sup>5-15</sup> This so-called no-reflow phenomenon has many causes associated with endothelial damage secondary to stenosis, reperfusion damage, embolization and vasospasm.<sup>5,12</sup>

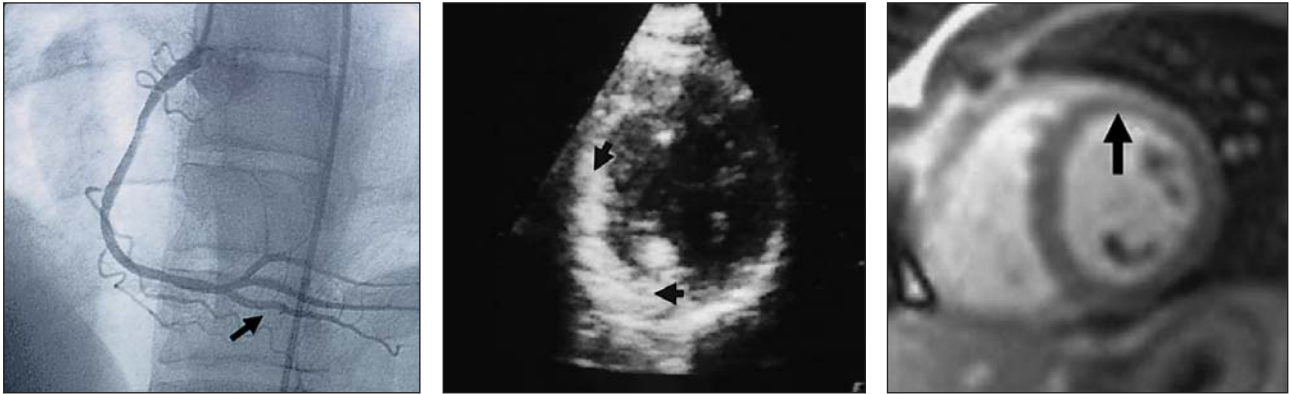
The presence of the no-reflow phenomenon is associated with worse prognosis, greater systolic dysfunction and a greater chance of remodeling.<sup>5-14,18</sup> Our study is interesting because it: *a)* compares a reliable technique (MCE) with 2 grading systems used extensively in perfusion studies (MRI and myocardial blush) but whose relative worth has yet to be estab-

lished; *b)* uses a very accurate method—MRI—for the studies of EDV and EF, and *c)* is conducted in Spain (few studies on this topic have been performed in this country).

## Myocardial Contrast Echocardiography

When a new diagnostic technique is introduced into clinical practice, the cardiologist will consider, among other things, the usefulness of the information provided, the safety of the technique for the patient, the extent to which the technique interferes with often busy schedules and the ease with which the information is interpreted.

Our study suggests that the technique provides very useful information because almost 25% of patients with good angiography but with impaired microcirculation can be identified. This grade was the most reliable of the four for predicting systolic function and remodeling in subsequent months. There were no side effects, the study duration was usually short (mean, 6 minutes) and we found that interpretation of the



**Figure 4.** Patient with inferior infarction, right coronary artery initially occluded with blush grade 3 after intervention. Left: patent after stent placement with blush grade 3 (arrow). Center: normal perfusion in the infarct area (arrows) after injection of contrast into right coronary artery. Right: magnetic resonance imaging of normal perfusion (arrow).

myocardial perfusion image with this technique was simple (Figures 3 and 4).

In agreement with the results from a pioneering study by Ito et al,<sup>9</sup> and subsequent studies by this group and others,<sup>6,7,10-14</sup> around a quarter of the patients with TIMI flow 3 presented no-reflow in the first week, whereas all patients with TIMI flow 2 showed poor microcirculation. Our findings therefore confirm that TIMI flow 3 is needed to achieve complete reperfusion but does not guarantee it. The proportion of patients with TIMI flow 3 and, for this subgroup, the proportion with no reflow, can only be increased by improvement in treatment. For example, the time between onset and treatment should be reduced, access to primary angioplasty should be improved and greater use should be made of interventions such as glycoprotein IIb-IIIa inhibitors, intracoronary adenosine and thrombectomy devices.<sup>1,3,16</sup>

### Myocardial Blush Grading

If we exclude patients with TIMI flow <3 (patients likely to have no reflow), we still need angiographic methods that can identify the appreciable number of patients with TIMI flow 3 and poor reperfusion. The myocardial blush grading is the most important of the new grading systems introduced.<sup>13,14</sup> Patients with myocardial blush grade 0 to 1 have been shown to have worse survival and greater systolic dysfunction compared to patients with myocardial blush grade 2 to 3.<sup>13</sup>

Analysis of the 40 studies with TIMI flow 3 showed 15% of our patients had myocardial blush grade 0 to 1, a percentage similar to the 11% found by Henriques et al.<sup>13</sup> These authors analyzed the prognostic value of this grade but did not compare it with any reference method. Our results suggest that myocardial blush grade 2 to 3 has a high positive predictive value (85%)

for good reperfusion but a negative predictive value of 50% (with respect to MCE). Thus myocardial blush grade 2 to 3 reaffirms the likelihood of good reperfusion, but no reflow cannot be immediately ruled out with a myocardial blush grade 0 to 1 (with TIMI flow 3). It has been suggested that the myocardial blush grade is a qualitative but not a quantitative marker of reperfusion that may explain some cases of apparently good reperfusion (but not throughout the entire infarct area).<sup>14</sup> The subjective nature of myocardial blush grading and difficulties in interpretation may explain why the technique gives false negatives and its low predictive value.

### Magnetic Resonance Imaging

Magnetic resonance imaging is becoming increasingly valued and popular among cardiologists because of its high reliability and resolution. Studies of cardiac volumes, function and viability with MRI show little variability.<sup>19-21</sup> It was therefore chosen as the reference technique for sequential analysis of EDV and EF in our study. The technique can also be applied to perfusion analysis by measurement of early uptake of gadolinium after intravenous injection.<sup>19</sup> In an analysis with a similar design, Wu et al<sup>20</sup> observed the no-reflow phenomenon by MRI in 11 out of 44 patients prior to discharge. This finding was associated with greater ventricular dilation and a greater infarct area after 6 months. Similarly, we have observed that a larger perfusion deficit by MRI is associated with a larger EDV and worse EF after 6 months.

As with myocardial blush grading, normal perfusion as evidenced by MRI indicates a high probability of normal perfusion (90%) in the presence of TIMI flow 3 with respect to the reference method for measurement of perfusion (MCE), though the negative predictive value was low (37%). These studies suggest

that intracoronary injection of echographic contrast is much more sensitive than intravenous injection of gadolinium for detection of normal microcirculation.

The myocardial blush grading therefore tends to overestimate perfusion (85% of the patients with TIMI flow 3 showed normal myocardial blush grade), whereas MRI tends to underestimate microcirculation (only 56% of the patients with TIMI flow 3 showed normal perfusion with MRI).

A TIMI flow of 3 in conjunction with another normal perfusion grade (myocardial blush or MRI) practically confirms good reperfusion so other techniques are not required. In contrast, TIMI flow 3 with an abnormal result in these grades is not equivalent to no reflow and MCE may be useful to clarify such cases in daily clinical practice. Myocardial contrast echocardiography could also find applications as the gold standard for assessing other techniques and for sequential perfusion studies after administration of neoangiogenesis treatments.<sup>22</sup>

### Relationship Between End-Diastolic Volume and Ejection Fraction at Month 6

In agreement with other authors, we have found that microvascular perfusion is a first order determinant of systolic function and end volumes.<sup>8-11</sup> Our previous experience in the analysis of postinfarction remodeling showed that the angiographic state of the infarct-related artery had a limited influence on ventricular volumes.<sup>23,24</sup> Our present study has shown, through reliable measurement of volumes (MRI) and perfusion (MCE), that microvascular condition determines ventricular remodeling. These findings suggest that the open artery theory<sup>4</sup> holds true, but the entire artery (down to microcirculation) must remain patent.

In a recent study, Candell et al<sup>25</sup> observed an improvement in perfusion over 6 months with the three techniques used. In contrast, analysis with MCE in late phases was the variable that correlated best with EF, EDV and increase in EDV (the most accurate indicator of the late remodeling process). This suggests that not only should we strive to recuperate microcirculation but also to maintain it, and that perfusion analysis after discharge from hospital would be useful to monitor microcirculation.

### Limitations

Only 17 patients underwent repeat study at month 6. Studies with larger patient populations and a complete statistical analysis of other variables are needed to clarify the role of microcirculation in remodeling and systolic function. The correlation coefficients between MCE and EDV at month 6 could have been overestimated because few patients (n=3) with highly impaired perfusion (MCE<0.3) were analyzed.

Postangioplastic reactive hyperemia could affect the results of MCE, but MCE (performed after catheterization) was the strongest predictor of remodeling and systolic function, whereas the MRI-perfusion grade (performed several days later) showed weaker correlations.

### CONCLUSIONS

Myocardial contrast echocardiography is feasible in the catheterization laboratory as it is not time-consuming and has no side effects. The state of microcirculation analyzed with this technique was the most reliable perfusion grade for predicting systolic function and ventricular remodeling in the months after infarction. A TIMI flow of 3 was necessary for complete reperfusion, but did not guarantee it. In patients where a TIMI flow of 3 was achieved, a normal myocardial blush grade or MRI perfusion grade almost ensured good reperfusion, whereas an abnormal myocardial blush or MRI-perfusion grade in patients with a TIMI flow of 3 was not necessarily equivalent to no reflow. Myocardial contrast echocardiography can therefore be used to determine reperfusion in daily clinical practice.

### REFERENCES

1. Braunwald E. Reperfusion therapy for acute myocardial infarction: historical context and future promise. *Eur Heart J* 2002; 4:E10-4.
2. Kloner RA. Coronary angioplasty: a treatment option for left ventricular remodeling after myocardial infarction? *J Am Coll Cardiol* 1992;20:314-6.
3. van de Werf F, Baim DS. Reperfusion for ST-segment elevation myocardial infarction. An overview of current treatment options. *Circulation* 2002;105:2813-6.
4. Kim CB, Braunwald E. Potential benefits of late reperfusion of infarcted myocardium. The open artery hypothesis. *Circulation* 1993;88:2426-36.
5. Rezkalla SH, Kloner RA. No-reflow phenomenon. *Circulation* 2002;105:656-62.
6. Iwakura K, Ito H, Kawano S, Shintani Y, Yamamoto K, Kato A, et al. Predictive factors for development of the no-reflow phenomenon in patients with reperfused anterior wall acute myocardial infarction. *J Am Coll Cardiol* 2001;38:472-7.
7. Sakuma T, Hayashi Y, Sumii K, Imazu M, Yamakido M. Prediction of short and intermediate term prognoses of patients with acute myocardial infarction using myocardial contrast echocardiography one day after recanalization. *J Am Coll Cardiol* 1998; 32:890-7.
8. Balcells E, Powers ER, Lepper W, Belcik T, Wei K, Ragosta M, et al. Detection of myocardial viability by contrast echocardiography in acute infarctions predicts recovery of resting function and contractile reserve. *J Am Coll Cardiol* 2003;41:827-33.
9. Ito H, Tomooka T, Sakai N, Yu H, Higashino Y, Fujii K, et al. Lack of myocardial perfusion immediately after successful thrombolysis. A predictor of poor recovery of left ventricular



- function in anterior myocardial infarction. *Circulation* 1992;85:1699-705.
10. Mengozzi G, Rossini R, Palagi C, Musumeci G, Petronio AS, Limbruno U, et al. Usefulness of intravenous myocardial contrast echocardiography in the early left ventricular remodeling in acute myocardial infarction. *Am J Cardiol* 2002;90:713-9.
  11. Destro G, Marino P, Barbieri E, Zorzi A, Brighetti G, Maines M, et al. Postinfarctional remodeling: increased dye intensity in the myocardial risk area after angioplasty of infarct-related coronary artery is associated with reduction of ventricular volumes. *J Am Coll Cardiol* 2001;37:1239-45.
  12. Ito H, Iwakura K. Assessing the relation between coronary reflow and myocardial reflow. *Am J Cardiol* 1998;81:G8-12.
  13. Henriques JP, Zijlstra F, van't Hof AW, de Boer MJ, Dambrink JH, Gosselink M, et al. Angiographic assessment of reperfusion in acute myocardial infarction by myocardial blush grade. *Circulation* 2003;107:2115-9.
  14. Haager PK, Christott P, Heussen N, Lepper W, Hanrath P, Hoffmann R. Prediction of clinical outcome after mechanical revascularization in acute myocardial infarction by markers of myocardial reperfusion. *J Am Coll Cardiol* 2003;41:532-8.
  15. Marques KM, Visser CA. Myocardial contrast echocardiography in the assessment of pharmacologic intervention of the reperfusion injury. *Eur Heart J* 2003;24:19-20.
  16. Cannon CP. Importance of TIMI 3 flow. *Circulation* 2001;104:624-7.
  17. Feigenbaum H. Enfermedad coronaria. En: Feigenbaum H, editor. *Ecocardiografía*. Malvern: Lea and Febiger, 1994; p. 436-95.
  18. Pomar F, Albero JV, Peris E, Echanove I, Vilar JV, Pérez E, et al. Valor pronóstico de la persistencia del segmento ST elevado después de una angioplastia primaria realizada con éxito. *Rev Esp Cardiol* 2002;55:816-22.
  19. Wu KC. Myocardial perfusion imaging by magnetic resonance imaging. *Current Cardiology Reports* 2003;5:63-8.
  20. Wu KC, Zerhouni EA, Judd RM, Lugo-Olivieri CH, Barouch LA, Schulman SP, et al. Prognostic significance of microvascular obstruction by magnetic resonance imaging in patients with acute myocardial infarction. *Circulation* 1998;97:765-72.
  21. Grothues F, Smith GC, Moon JC, Bellenger NG, Collins P, Klein HU, et al. Comparison of interstudy reproducibility of cardiovascular magnetic resonance imaging with two-dimensional echocardiography in normal subjects and in patients with heart failure or left ventricular hypertrophy. *Am J Cardiol* 2002;90:29-34.
  22. Schwartz Y, Kornowsky R. Progenitor and embryonic stem cell transplantation for myocardial angiogenesis and functional restoration. *Eur Heart J* 2003;24:404-11.
  23. Sanchis J, Bodí V, Insa L, Berenguer A, Chorro FJ, Llácer A, et al. Predictors of early and late ventricular remodeling after acute myocardial infarction. *Clin Cardiol* 1999;22:581-6.
  24. Bodí V, Sanchis J, Berenguer A, Insa L, Chorro FJ, Llácer A, et al. Wall motion of noninfarcted myocardium. Relationship to regional and global systolic function and to early and late left ventricular dilation. *Int J Cardiol* 1999;71:157-65.
  25. Candell J, Pereztol O, Oller G, Llevadot J, Aguadé S, Castell J, et al. Evolución de la función sistólica y de la perfusión miocárdica valoradas mediante gated-SPECT durante el primer año después de un infarto agudo de miocardio. *Rev Esp Cardiol* 2003;56:438-44.