

Original article

Magnetic Resonance for Noninvasive Detection of Microcirculatory Disease Associated With Allograft Vasculopathy: Intracoronary Measurement Validation



Jesús G. Mirelis,^{a,b,*} Pablo García-Pavía,^a Miguel A. Cavero,^a Esther González-López,^a Mauro Echavarría-Pinto,^{b,c} Miguel Pastrana,^d Javier Segovia,^a Juan F. Oteo,^a Luis Alonso-Pulpón,^a and Javier Escaned^c

^aServicio de Cardiología, Hospital Universitario Puerta de Hierro, Majadahonda, Madrid, Spain

^bCentro Nacional de Investigaciones Cardiovasculares (CNIC), Madrid, Spain

^cServicio de Cardiología, Hospital Clínico San Carlos, Madrid, Spain

^dServicio de Radiología, Hospital Puerta de Hierro, Majadahonda, Madrid, Spain

Article history:

Received 16 June 2014

Accepted 18 July 2014

Available online 15 December 2014

Keywords:

Cardiac allograft vasculopathy
Dobutamine stress magnetic resonance
Microcirculation

ABSTRACT

Introduction and objectives: Cardiac allograft vasculopathy affects both epicardial and microcirculatory coronary compartments. Magnetic resonance perfusion imaging has been proposed as a useful tool to assess microcirculation mostly outside the heart transplantation setting. Instantaneous hyperemic diastolic flow velocity-pressure slope, an intracoronary physiology index, has demonstrated a better correlation with microcirculatory remodelling in cardiac allograft vasculopathy than other indices such as coronary flow velocity reserve. To investigate the potential of magnetic resonance perfusion imaging to detect the presence of microcirculatory remodeling in cardiac allograft vasculopathy, we compared magnetic resonance perfusion data with invasive intracoronary physiological indices to study microcirculation in a population of heart transplantation recipients with macrovascular nonobstructive disease demonstrated with intravascular ultrasound.

Methods: We studied 8 heart transplantation recipients (mean age, 61 [12] years, 100% male) with epicardial allograft vasculopathy defined by intravascular ultrasound, nonsignificant coronary stenoses and negative visually-assessed wall-motion/perfusion dobutamine stress magnetic resonance. Quantitative stress and rest magnetic resonance perfusion data to build myocardial perfusion reserve index, noninvasively, and 4 invasive intracoronary physiological indices were determined.

Results: Postprocessed data showed a mean (standard deviation) myocardial perfusion reserve index of 1.22 (0.27), while fractional flow reserve, coronary flow velocity reserve, hyperemic microvascular resistance and instantaneous hyperemic diastolic flow velocity-pressure slope were 0.98 (0.02), cm/s/mmHg, 2.34 (0.55) cm/s/mmHg, 2.00 (0.69) cm/s/mmHg and 0.91 (0.65) cm/s/mmHg, respectively. The myocardial perfusion reserve index correlated strongly only with the instantaneous hyperemic diastolic flow velocity-pressure slope ($r = 0.75$; $P = .033$).

Conclusions: Myocardial perfusion reserve index derived from a comprehensive dobutamine stress magnetic resonance appears to be a reliable technique for noninvasive detection of microcirculatory coronary disease associated with cardiac allograft vasculopathy.

© 2014 Sociedad Española de Cardiología. Published by Elsevier España, S.L.U. All rights reserved.

Resonancia magnética para la detección no invasiva de la enfermedad microcirculatoria asociada a la vasculopatía de alotrasplante: validación de la determinación intracoronaria

RESUMEN

Introducción y objetivos: La vasculopatía del aloinjerto cardiaco afecta tanto al compartimento coronario epicárdico como al de la microcirculación. Se ha propuesto el uso de las técnicas de imagen de perfusión de la resonancia magnética como instrumento útil para la evaluación de la microcirculación, principalmente fuera del contexto del trasplante de corazón. La pendiente de velocidad del flujo-presión diastólica hiperémica instantánea, que es un índice de la fisiología intracoronaria, ha mostrado mejor correlación con el remodelado microcirculatorio en la vasculopatía del aloinjerto cardiaco que la de otros índices como la reserva de velocidad del flujo coronario. Con objeto de investigar el potencial de las técnicas de imagen de perfusión de resonancia magnética para detectar la presencia de remodelado

Palabras clave:

Vasculopatía de aloinjerto cardiaco
Resonancia magnética de estrés
con dobutamina
Microcirculación

* Corresponding author: Centro Nacional de Investigaciones Cardiovasculares, C/ Melchor Fernandez Almagro 3, 28029 Madrid, Spain.
E-mail address: jesus.gmirelis@telefonica.net (J.G. Mirelis).

microcirculatorio en la vasculopatía de aloinjerto cardíaco, se ha comparado los datos de perfusión de resonancia magnética con los índices fisiológicos intracoronarios invasivos, para estudiar la microcirculación en una población de pacientes con trasplante de corazón que presentaban una enfermedad macrovascular no obstructiva demostrada por la ecografía intravascular.

Métodos: Se estudió a 8 pacientes con trasplante de corazón (media de edad, 61 ± 12 años; el 100% varones) que presentaban una vasculopatía del aloinjerto epicárdica definida por ecografía intravascular, estenosis coronarias no significativas y una resonancia magnética de estrés con dobutamina con evaluación visual del movimiento de la pared/perfusión negativa. Se determinaron los datos de perfusión de resonancia magnética cuantitativa en estrés y en reposo para establecer el índice de reserva de perfusión miocárdica, de manera no invasiva, y se determinaron cuatro índices fisiológicos intracoronarios evaluados de manera invasiva.

Resultados: Los datos posprocesados mostraron una media del índice de reserva de perfusión miocárdica de $1,22 \pm 0,27$, mientras que la reserva de flujo fraccional, la reserva de velocidad del flujo coronario, la resistencia microvascular hiperémica y la pendiente de velocidad del flujo-presión diastólica hiperémica instantánea fueron de $0,98 \pm 0,02$, $2,34 \pm 0,55$, $2,00 \pm 0,69$ y $0,91 \pm 0,65$ cm/s/mmHg respectivamente. El índice de reserva de perfusión miocárdica presentó una correlación intensa tan solo con la pendiente de velocidad del flujo-presión diastólica hiperémica instantánea ($r = 0,75$; $p = 0,033$).

Conclusiones: El índice de reserva de perfusión miocárdica obtenido a partir de la resonancia magnética de estrés con dobutamina completa resulta una técnica fiable para la detección no invasiva de la enfermedad coronaria microcirculatoria asociada a la vasculopatía de aloinjerto cardíaco.

© 2014 Sociedad Española de Cardiología. Publicado por Elsevier España, S.L.U. Todos los derechos reservados.

Abbreviations

CAV: cardiac allograft vasculopathy
 CFVR: coronary flow velocity reserve
 HT: heart transplantation
 IHDVPS: instantaneous hyperemic diastolic flow velocity-pressure slope
 MPRI: myocardial perfusion reserve index
 MR: magnetic resonance

INTRODUCTION

Heart transplantation (HT) is an effective treatment for selected patients with end-stage heart failure.^{1,2} Cardiac allograft vasculopathy (CAV) is the leading cause of late death among HT recipients.³ Epicardial coronary arteries as well as microvasculature (microvascular allograft vasculopathy) are affected in CAV.

Both obstructive and nonobstructive (microvascular) components of CAV influence patient prognosis.⁴ Detection of CAV is clinically relevant in the management of HT recipients. Immunosuppressive therapy modification is recommendable once CAV is detected because several immunosuppressive drugs have been shown to slow CAV progression and reduce events related to this entity.^{5–7}

Coronary intravascular ultrasound is currently considered the gold standard for detection of macrovascular allograft vasculopathy. Due to the peculiar concentric distribution of CAV, detection of macrovascular allograft vasculopathy is higher by intravascular ultrasound than by angiography because an important subset of patients with apparently normal angiograms is affected by CAV.^{8–10} Intravascular ultrasound also provides important prognostic information⁸ and has therefore been established as the routine technique for the detection of macrovascular allograft vasculopathy in experienced HT centers. Despite the usefulness of intravascular ultrasound, this technique does not explore the microvasculature and is therefore not useful to diagnose microvascular allograft vasculopathy.

Assessment of microvascular allograft vasculopathy is hampered by the lack of a robust methodology. It has been customary to assess microvascular allograft vasculopathy using the intracoronary Doppler wire to measure coronary flow velocity reserve (CFVR).^{11,12} However, our group recently reported that combined pressure and flow velocity indices, particularly the instantaneous hyperemic flow pressure velocity slope (IHDVPS) index, correlate better with structural microcirculatory remodeling documented in cardiac biopsies than CFVR.¹³

Cardiac magnetic resonance (MR) provides a comprehensive evaluation of cardiac structure and function, allowing assessment of complete segmental wall motion and myocardial perfusion. Dobutamine stress MR has been proven to be useful for the detection of stenosis in epicardial coronary arteries.¹⁴ Visual assessment of dobutamine stress MR perfusion imaging has also been applied for the study of microvasculature in X syndrome.¹⁵ Although without invasive intracoronary validation, quantitative myocardial perfusion indices have also been developed and applied to the study of the microcirculatory component of CAV.¹⁶ Use of comprehensive cardiac stress MR to explore both, macro- and microvascular components of the coronary tree in HT patients has not been previously evaluated.

The aim of this study was to evaluate the value of noninvasive stress perfusion MR to detect microvascular allograft vasculopathy, using the IHDVPS as an invasive reference index.

METHODS

Subjects

Seventeen consecutive clinically stable HT recipients with CAV diagnosed by intravascular ultrasound as harboring at least 1 coronary segment with Stanford classification \geq class 3 were included. The mean (standard deviation) time from HT to the MR study was 10.3 (5.47) years. To avoid interference of epicardial stenoses on coronary hemodynamics, the study was conducted in cardiac allografts without obstructive coronary disease, assessed angiographically and confirmed with intracoronary physiology. Therefore none of the patients had significant stenosis in epicardial

arteries on angiography. To assure a “functionally pure scenario” to study the microvascular compartment, we included only participants who were classified as negative on a visually-assessed dobutamine stress MR. Thus, all patients showed negative wall-motion and negative visually-assessed perfusion on dobutamine stress MR. The study was approved by our institution’s local review board and conformed to the ethical guidelines of the Declaration of Helsinki. Informed consent was obtained from all participants.

Dobutamine Stress Magnetic Resonance

The studies were performed with a 1.5 T scanner (Philips Achieva® CV; Best, The Netherlands) equipped with a gradients PowerTrak 6000 system (23 mT/m, rise time 219 μ s; Philips Achieva®). Cardiac synchronization was performed with 4 electrodes in the anterior region of the left hemithorax. For cine imaging sequences, balanced steady-state free precession was used with retrospective cardiac gating. Standard cardiac geometries were acquired (3 short-axis: basal, mid and apical, and 3 long-axis: 4-chamber, 2-chamber and 3-chamber) both at rest and at every step of the stress protocol (Figure 1).

Dobutamine was infused using a Space Perfusor® pump (B. Braun Melsungen AG; Germany) at a standard increasing rate, from 10 to 40 μ g/kg/min (Figure 1). Target heart rate = (theoretical maximum heart rate = 220 – age) \times (0.85). Once the target heart rate was achieved, stress first-pass perfusion imaging was performed and dobutamine infusion was stopped immediately after. Although adenosine could have been used as a pharmacologic stressor, high specificity for wall motion abnormality described on dobutamine stress MR¹⁷ was preferred. For myocardial perfusion imaging, steady-state free precession sequences were used with the following parameters: echo time, 1.4 ms; repetition time, 2.8 ms; and flip angle, 50°, along with a saturation prepulse, acquiring 3 short-axis per beat. The spatial resolution was 2.8 \times 3 \times 10 mm. SENSE factor 3.0 was used. Gadobutrol was administered (Gadovist® Bayer Schering Pharma; Berlin, Germany) through a peripheral vein at a dose of 0.1 mmol/kg for first-pass myocardial perfusion at a rate of 3 mL/s, using a pump COVIDIEN Optistar™ LE MR Injector (Siemens; Munich, Germany). Following a 10-min wait to allow a heart rate of around 100 bpm, a new dose of 0.1 mmol/kg was infused intravenously at a rate of 3 mL/s to complete the total 0.2 mmol/kg dose used to study myocardial perfusion at rest. Standard late gadolinium enhancement imaging was performed¹⁸ (an example of dobutamine stress MR is shown in Figure 1).

Stress Protocol

Wall Motion and Qualitative Magnetic Resonance Perfusion Analysis

All image analysis was performed using the workstation Extended Workspace® (Philips Medical Systems; Best, The Netherlands). Two observers, blinded to clinical, perfusion, angiographic and physiology data, performed segmental wall analysis using a synchronized quad-screen image display and applying a standard 16-segment method.

Quantitative Perfusion Analysis

The myocardial perfusion reserve index (MPRI) was defined as the ratio of hyperemic and basal myocardial blood flow. Therefore, the MPRI was calculated as the ratio of the normalized time-signal upslopes measured for rest and stress images.^{19,20} Upslope was defined as the first derivative of the time-intensity curve during the ascent of the first passes; units were signal intensity per second (S/s). The upslope of the myocardium was normalized by the upslope of left ventricular blood pool to correct for differences of the speed and compactness of the contrast agent bolus.^{21,22} Stress and rest upslopes were measured in segment 8 (mid anteroseptal) according to 16-segment nomenclature²³ to better assess myocardial tissue from left anterior descending artery territory (Doppler-wire measurements are performed in the midleft anterior descending artery). An example of the time-intensity signal curve is shown in Figure 2.

Catheterization Procedure

A standard catheterization procedure was performed. Two experienced cardiologists analyzed coronary angiography data independently and blinded to dobutamine stress MR data. Significant coronary stenosis was defined as a lumen stenosis \geq 70% in at least 1 of the coronary arteries or their major branches. Intravascular ultrasound images were acquired using 40 MHz Atlantis intravascular ultrasound catheters and the corresponding Galaxy2® console (Boston Scientific; Massachusetts, United States), which also served as a workstation for intravascular ultrasound measurements. Slow pullback of 2 major epicardial coronary arteries, ie, left anterior descending artery and circumflex artery, towards their ostia was performed. The position of the transducer was angiographically determined. Coronary segments were defined according to standard anatomical landmarks.

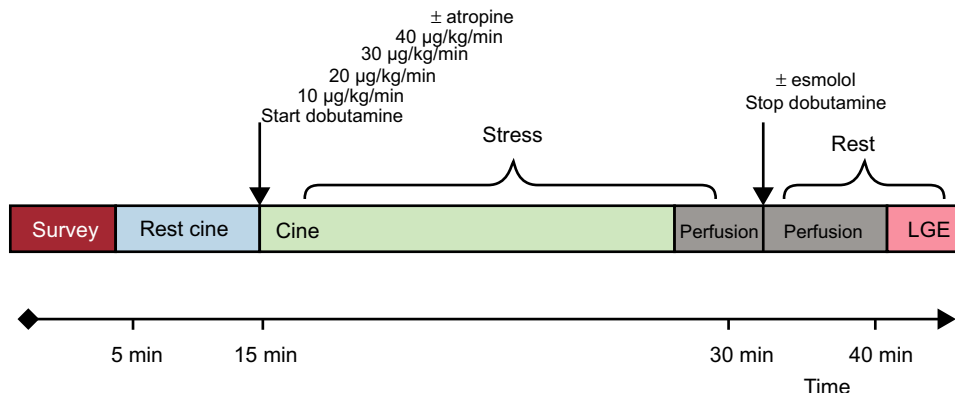


Figure 1. Dobutamine stress magnetic resonance protocol. LGE, late gadolinium enhancement.

Representative images were acquired for each segment. The most affected area was selected in each segment and was quantitatively evaluated according to the degree of thickness and circumferential extent of intimal hyperplasia. For CAV evaluation, we used the Stanford classification and the index of intimal thickening as previously described.^{24,25}

Intravascular Hemodynamics

Coronary flow measurements were performed in the midsegment of the left anterior descending artery using an 0.014" intracoronary guidewire fitted with Doppler and pressure sensors (ComboMap[®], Volcano Corporation; San Diego, California, United States) connected to the corresponding interface (ComboMap, Volcano Corporation, San Diego, California, United States). Measurements were obtained 3 min to 5 min after the intracoronary administration of nitroglycerin for the rest phase and afterward repeated measurements were taken during hyperemia with adenosine for the stress phase. Digital electrocardiogram, aortic pressure and instantaneous intracoronary peak flow data were extracted from the console and analyzed using a custom software package designed with MATLAB[®] (Mathworks, Inc.; Natick, Massachusetts, United States). The following indices were calculated: a) fractional flow reserve²⁶: as the ratio of distal coronary pressure (P_d) to proximal coronary pressure (P_a) at maximal hyperemia; b) CFVR²⁶: as the ratio between the average of peak velocities (V_{cor}) measured at rest and during hyperemia (V_{cor} hyperemia/ V_{cor} basal); c) coronary resistance reserve: as the ratio between resting coronary resistance (P_d / V_{cor} basal) and hyperemic coronary resistance (P_d / V_{cor} at hyperemia); d) hyperemic microvascular resistance²⁷: as the ratio between mean aortic pressure (P_a) and average peak velocities during hyperemia (P_a / V_{cor} at hyperemia), and finally; e) the slope of the IHDVPS defined as the slope of the pressure-velocity flow during mid- and end-diastole under maximal hyperemia.²⁸ Diastolic pressure and flow rate measurements were automatically identified using as reference peak flow velocity (initiation of middiastole) and the fast decrease in diastolic velocity at the end of diastole. Linear regression analysis was applied to the selected data and a slope of the regression curve (diastolic coronary conductance under hyperemia) expressed in mmHg/cm/s was obtained. The linearity of the relationship in this specific range was described using the

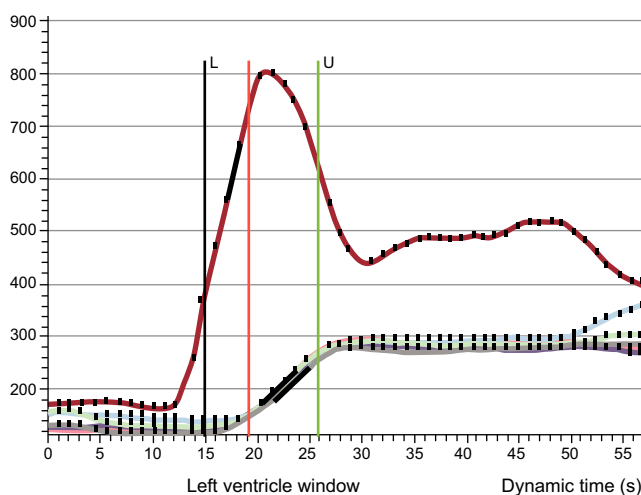


Figure 2. Perfusion imaging postprocessing. Time-intensity-curve of the blood pool (red line) and 6 segments in the midventricle (overlapping lines). The upslope was calculated and corrected with blood pool (see text for details). L, lower frame included in the analysis; U, upper frame included in the analysis.

regression coefficient r^2 . A IHDVPS calculation example is shown in Figure 3.

Statistical Analysis

The statistical package used was IBM SPSS Statistics, release 20.0.0. Continuous variables were expressed as mean (standard deviation). Discrete data are shown as the number of participants and %. Person correlation was used to compare continuous variables. Statistical tests were bilateral; significance was reached if $P < .05$.

RESULTS

Seventeen HT recipients (61 [11] years old, 16 males, time from transplant 10 [5] years) were initially recruited. Three patients were excluded from analysis due to the lack of either dobutamine stress MR (1 patient, claustrophobia) or catheterization procedure (2 patients: traumatic death and aortic thrombus), and 4 patients because of inconclusive stress conditions to evaluate MPRI. Finally 2 patients were excluded due to technical issues in invasive microcirculatory assessment. Therefore, 8 patients were finally eligible for the noninvasive vs invasive comparison performed in the study. The patients' baseline characteristics and MR data are shown in the Table.

In the perfusion postprocessing analysis, the mean (standard deviation) MPRI value measured at segment 8 was 1.22 (0.27). Intracoronary measurements yielded the following values: fractional flow reserve 0.98 (0.02) (confirming the absence of obstructive epicardial disease); CFVR, 2.34 (0.55) (in 1 patient CFVR could not be calculated due to artifacts in the recorded baseline flow velocity); hyperemic microvascular resistance, 2.00 (0.69) cm/s/mmHg, and IHDVPS, 0.91 (0.65) cm/s/mmHg. In investigating the relationship between these intracoronary indices and MPRI, a significant correlation was documented for IHDVPS ($r = 0.75$; $P = .033$), but not for fractional flow reserve, CFVR or hyperemic microvascular resistance (Table, Figure 4).

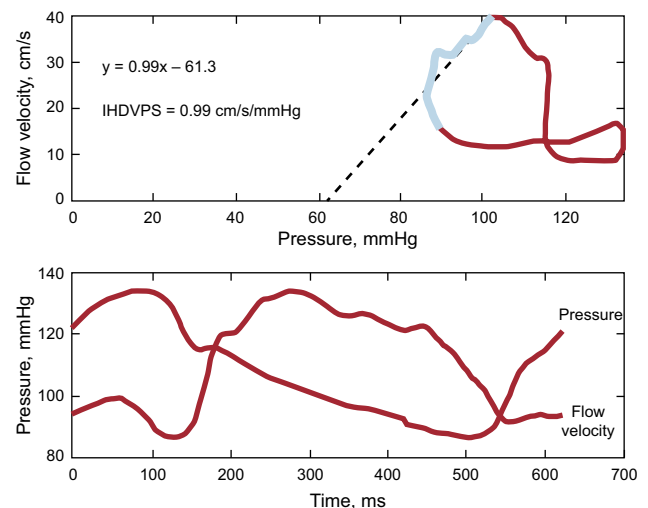


Figure 3. Coronary flow velocity/pressure relationship in one of the patients included in the study. Upper panel shows the pressure/flow velocity loop obtained by averaging several beats during maximal hyperemia. A instantaneous hyperemic diastolic velocity pressure slope index of 0.9 mmHg/cm/s was calculated by performing linear regression analysis (dotted line) of values measured in mid- and late-diastole (blue segment in loop). The lower panel shows pressure and flow velocity waveforms. IHDVPS, instantaneous hyperemic diastolic flow velocity-pressure slope.

Table
Patient Characteristics

	Complete cohort (n = 17)	Patients included in the analysis (n = 8)
<i>Patient's baseline characteristics</i>		
Gender male	16 (94.1)	8 (100)
Age at DSMR, mean (SD), y	61 (11)	61 (12)
BSA, mean (SD), m ²	1.96 (0.2)	2 (0.2)
Hypertension	13 (72)	7 (88)
DM	6 (33)	0 (0)
Hyperlipidemia	7 (39)	3 (38)
Current smoker	1 (6)	0 (0)
Family history of CAD	2 (11)	2 (14)
Total cholesterol, mean (SD), mg/dL	170.4 (25.6)	170.5 (17.3)
LDL-C, mean (SD), mg/dL	83.5 (19.4)	85.5 (21.4)
HDL-C, mean (SD), mg/dL	54.8 (21.3)	54.4 (16.9)
Triglycerides, mean (SD), mg/dL	160.6 (80.2)	153.3 (89.2)
NT-proBNP, mean (SD), pg/mL	458.8 (313.2)	374.9 (89.2)
Creatinine, mean (SD), mg/dL	1.4 (0.4)	1.3 (0.3)
GFR MDRD 7, mean (SD), mL/min/1.73m ²	67.7 (21.8)	72.8 (23.8)
<i>HT and medication</i>		
Age at HT, mean (SD), y	51 (12)	50 (11)
Time between HT and DSMR, mean (SD), y	10 (5)	8 (5)
Orthotopic HT	14 (100)	8 (100)
On-pump time, mean (SD), min	126 (39)	147 (49)
Ischemic time, mean (SD), min	190 (55)	183 (88)
Rejection episodes, median [range]	0 [0-5]	0 [0-5]
Ischemic cardiomyopathy pre-HT	8 (47)	5 (63)
Dilated cardiomyopathy pre-HT	8 (47)	3 (38)
Myocarditis pre-HT	1 (6)	0 (0)
Mycophenolate	13 (76)	5 (63)
Cyclosporine	14 (82)	5 (63)
Tacrolimus	1 (6)	1 (13)
Steroids	13 (76)	8 (100)
Everolimus	4 (18)	3 (38)
ACE inhibitors/ARB	14 (82)	5 (63)
Beta-blockers	2 (12)	1 (13)
Calcium channel blockers	3 (18)	1 (13)
Statins	17 (100)	8 (100)
Antiplatelet drugs	6 (35)	3 (38)
Anticoagulants	4 (24)	1 (13)
<i>MR basal characteristics and DSMR data</i>		
Aortic root, median (range), cm	3.0 (0.3)	3.2 (0.3)
Left atrial diameter, mean (SD), cm	4.9 (0.9)	4.8 (1.0)
End diastolic LV diameter mean (SD), cm	4.5 (0.4)	4.5 (0.4)
End systolic LV diameter, mean (SD), cm	2.9 (0.5)	2.9 (0.6)
Anteroseptal wall thickness, mean (SD), cm	1.3 (0.3)	1.3 (0.3)
Posterior wall thickness, mean (SD), cm	1.0 (0.1)	1.0 (0.1)
End diastolic LV volume, mean (SD), mL	106.9 (29.1)	111.5 (33.2)

Table (Continued)
Patient Characteristics

	Complete cohort (n = 17)	Patients included in the analysis (n = 8)
End diastolic LV volume index, mean (SD), mL/m ²	55.0 (14.8)	55.6 (13.2)
LVEF, mean (SD), %	66 (8)	66 (9)
<i>DSMR</i>		
Positive WM DSMR	0 (0)	0 (0)
Positive perfusion DSMR	0 (0)	0 (0)
Positive LGE	0 (0)	0 (0)
Age, mean (SD), y	61 (11)	61 (12)
Relevant complications	0 (0)	0 (0)
Peak HR, mean (SD), bpm	143.0 (12.7)	139.3 (6.3)
Double product, mean (SD), bpm × mmHg	18978.6 (3815.5)	18392.3 (1830.5)
Max dobutamine dose administered, mean (SD), µg/kg/min	36.3 (6.2)	36.3 (5.2)
Esmolol given	16 (94)	8 (100)
Esmolol dose, mean (SD), mg	54.1 (17.6)	51.9 (20.0)
Atropine given	9 (53)	3 (38)
Atropine dose mean (SD), mg	0.56 (0.80)	0.33 (0.70)
TMHR, mean (SD), bpm	158.7 (10.8)	158.7 (11.5)
TMHR, mean (SD), %	90.9 (8.6)	88.1 (7.1)
Conclusive	13 (76)	8 (100)
MPRI, mean (SD)	1.29 (0.83)	1.22 (0.27)
<i>Intracoronary physiology indices</i>		
FFR, mean (SD)		0.98 (0.02)
CFVR, mean (SD)		2.34 (0.55)
HMR, mean (SD), mmHg/cm/s		2.00 (0.69)
IHDVPS, mean (SD), mmHg/cm/s		0.91 (0.65)
Stanford classification score, mean (SD)		3.30 (0.86)
Coronary sites with an index of intimal thickening > 20%, mean (SD)		3.00 (1.93)

ACE, angiotensin-converting enzyme; ARB, angiotensin receptor blockers; BSA, bovine serum albumin; CAD, coronary artery disease; CFVR, coronary flow velocity reserve; DM, diabetes mellitus; DSMR, dobutamine stress magnetic resonance; FFR, fractional flow reserve; GFR, glomerular filtration rate; HDL-C, high-density lipoprotein cholesterol; HMR, hyperemic microvascular reserve; HR, heart rate; HT, heart transplantation; IHDVPS, instantaneous hyperemic diastolic flow velocity-pressure slope; LDL-C, low-density lipoprotein cholesterol; LGE, late gadolinium enhancement; LV, left ventricle; LVEF, left ventricular ejection fraction; MDRD, Modification of Diet in Renal Disease; MPRI, myocardial perfusion reserve index; MR, magnetic resonance; NT-proBNP, N-terminal pro-B-type natriuretic peptide; SD, standard deviation; TMHR, theoretical maximum heart rate; WM, wall motion.

Data are expressed as No. (%), mean (standard deviation) or median [range].

All patients included in the analysis had evidence of macrovascular allograft vasculopathy in intravascular ultrasound with, as per protocol, at least 1 coronary site of Stanford classification class ≥ 3 .

DISCUSSION

The main finding of our study is that, in patients with cardiac allografts, noninvasive quantitative assessment of myocardial perfusion with MR imaging reflects the presence of underlying microcirculatory disease associated with structural remodelling,

as evaluated by intracoronary assessment of microcirculatory hemodynamics. To strengthen these observations, the study was conducted in a selected population of patients with intravascular ultrasound-detected CAV but no obstructive epicardial disease.

The availability of methods to assess the status of coronary microcirculation remains a pending subject in adequately assessing the prognosis of ischemic heart disease in atherosclerosis²⁹ and other conditions such as CAV.⁴ The potential use of MR to noninvasively evaluate the presence and transmural distribution of microcirculatory disease was first revealed in the assessment of acute coronary syndromes,³⁰ with subsequent studies revealing its prognostic implications.³¹

Several studies have evaluated MPRI in several microvascular disorders, although CFVR has usually been taken as the intracoronary invasive reference.^{15,16} In 2003, Muehling et al.¹⁶ assessed for the first time CAV (both macrovascular allograft vasculopathy and microvascular allograft vasculopathy) with MPRI, using angiography and CFVR as references. This group reported that a cutoff point for MPRI of < 2.3 had a sensitivity and specificity of 100% for the detection of CAV. In that study, a CFVR cutoff value of < 2.5 was used to define microvascular allograft vasculopathy. More recently, Lanza et al.¹⁵ demonstrated the ability of perfusion MR to evaluate coronary microcirculation in cardiac syndrome X, a condition in which microcirculatory dysfunction allegedly plays a major role. This group highlighted the concurrence of myocardial perfusion defects (assessed visually) and a reduced value of CFVR in affected individuals.

In the present study, we addressed the value of MR perfusion sequences to quantify the degree of microvascular allograft

vasculopathy in transplant patients. Unlike previous studies, the study population was carefully selected to ensure that the presence of evident or concealed obstructive coronary disease would not interfere with the observations. Patients were thus carefully selected and underwent multiple testing at the expense of limiting the population size. First, the presence of obstructive epicardial disease that might influence the observations at a microcirculatory level was excluded not only by limiting inclusion to cardiac allografts without angiographic stenoses, but also by demonstrating a normal epicardial conductance with fractional flow reserve. The use of physiology to confirm angiographic findings is important, since diffuse luminal irregularities may cause significant intracoronary pressure loss in the absence of focal stenoses.³² In this regard, it is worth noting that fractional flow reserve values in our series (0.98 [0.02]) were similar to those reported by Melikian et al.³³ in a population of control participants without coronary atheroma (0.96 [0.02]). Second, intravascular ultrasound was performed to document nonobstructive evidence of allograft vasculopathy, demonstrating a Stanford score of 3.30 (0.86). Finally, a negative wall-motion analysis for dobutamine stress MR was a prerequisite for study inclusion.

Furthermore, an alternative intracoronary physiology index to CFVR was used as a reference to assess the presence of microvascular allograft vasculopathy. This was required because, despite having been frequently used to evaluate microcirculatory status, CFVR is limited by being a relative index of coronary flow. This implies that any modification of baseline flow velocity resulting from hemodynamic factors, age, diabetes mellitus or sex, to name a few factors, will affect the final CFVR value.³⁴ This may

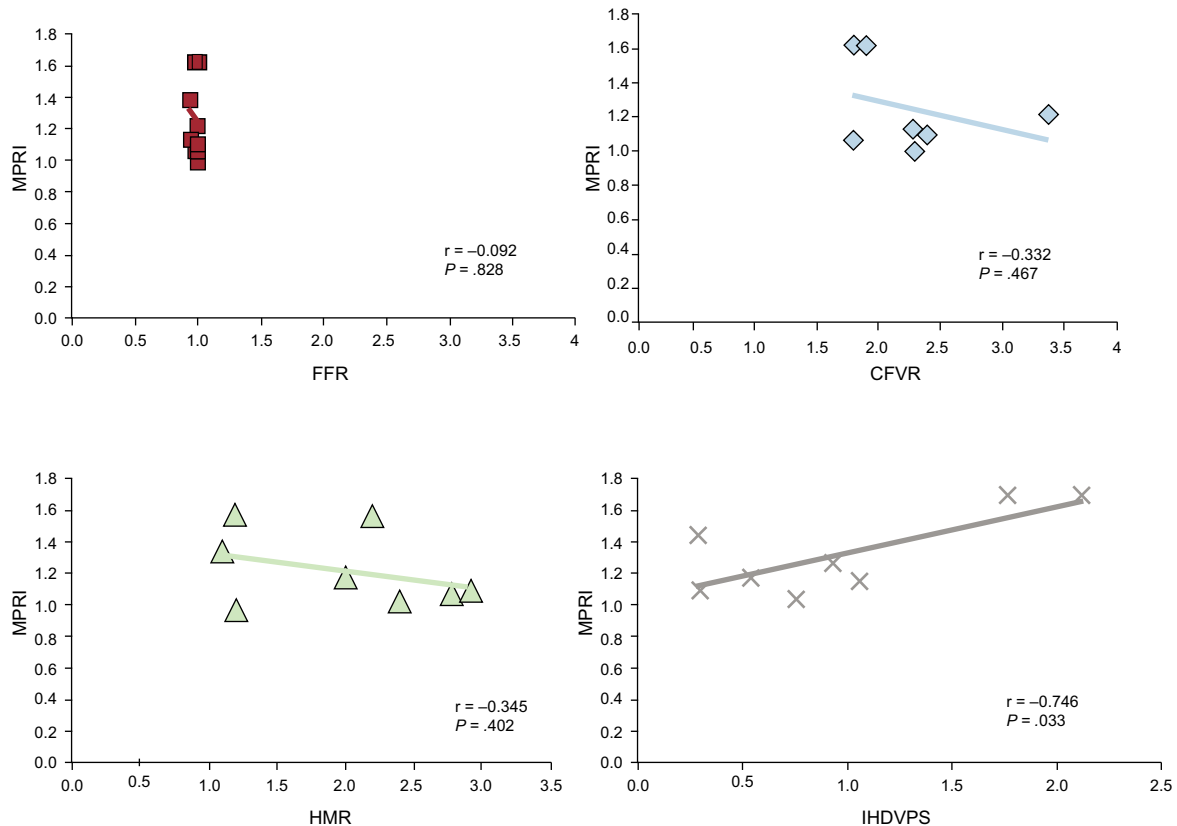


Figure 4. Pearson correlations between intracoronary physiology indices. CFVR, coronary flow velocity reserve; FFR, fractional flow reserve; HMR, hyperemic microvascular resistance; IHDVPS, instantaneous hyperemic diastolic flow velocity-pressure slope; MPRI, myocardial reserve perfusion index. Pearson correlation coefficient r , and P value are shown for each comparison.

potentially be more relevant in cardiac allografts, since denervation and enhanced sympathomimetic tone may influence baseline flow velocity measurements.

Due to these considerations, in a previous work we explored the possibility of using baseline flow-independent indices based on either whole-cycle microcirculatory resistance (coronary resistance index) or on the coronary pressure-flow velocity relationship measured selectively during mid- and late-diastole IHDVPS. Specifically, IHDVPS demonstrated an excellent, independent correlation with 2 important elements of structural microcirculatory remodeling in CAV namely, arteriolar obliteration, and capillary rarefaction.¹³ When the combined contribution of these 2 elements of microcirculatory disease was taken into account, the strength of the relationship between IHDVPS and the underlying microcirculatory changes ($r = 0.84$; $P = .0002$) was far superior to CFVR and to the microcirculatory resistance ratio.¹³

Although both indexes are derived from the same theoretical framework, namely coronary flow reserve, in our study, we could not document a significant relationship between MPRI and CFVR. In understanding this discrepancy, 2 important differences between these 2 indexes should be remembered: a) MPRI assesses changes in myocardial blood in response to stress, while CFVR assesses changes in flow velocity in an epicardial artery, and b) maximal hyperemia is obtained in response to dobutamine administration in MPRI, while intravenous adenosine infusion is used in CFVR; although intravenous dobutamine infusion has been found to be as effective as adenosine at dosages of 40 $\mu\text{g}/\text{kg}/\text{min}$ in inducing myocardial hyperemia,³⁵ in practice this dosage is not always achievable, as demonstrated in our series (in 3 patients [38%] the stress protocol had to be stopped before that dobutamine dose).

The MPRI values obtained in our study were similar to those registered in the so-called group C population published by Muehling et al.¹⁶ Both populations (group C of Muehling et al and ours) had a similar profile (macrovascular allograft vasculopathy was present and CFVR was relatively low).

On the other hand, the existence of a significant correlation between MPRI and IHDVPS, and not with CFVR, mirrors our previous comparisons of both indices with histomorphometric findings in cardiac biopsies of cardiac allografts, and provides a new piece of evidence supporting the value of IHDVPS for this purpose. It is also interesting to note that hyperemic microvascular resistance, a microcirculatory resistance index similar to the coronary resistance index used in our previous validation work, did not correlate significantly with MR findings. Because this resistance index is obtained from averaged, whole cardiac cycle measurements of pressure and flow velocity, hyperemic microvascular resistance may be not as sensitive as IHDVPS in the detection of microvascular allograft vasculopathy, while still being superior to CFVR.¹³

As shown in our study, MPRI had an excellent and statistically significant correlation with IHDVPS. According to the results of our analysis, dobutamine stress MR was a safe test in patients after HT if they were clinically stable. The safety profile of the technique is comparable to results previously published in non-HT patients.³⁶ No extraordinary safety measures for these patients were necessary. Unlike published evidence in HT recipients with denervated hearts,³⁷ a chronotropic response to atropine was found and therefore this drug would be considered useful for pharmacological stress protocols to reach the target heart rate.

To our knowledge, no validation of MR perfusion sequences with IHDVPS has previously been published. Potentially, our research would facilitate the development of a noninvasive platform, comprehensive dobutamine stress MR, as a model for study both vascular compartments, helping to consolidate MR as a valid approach for the evaluation of microcirculatory disease.

In terms of clinical applicability, due to the intrinsic difficulties of routinely performing invasive tests in HT patients, our proposed noninvasive methodology, MPRI, could be an attractive alternative for the follow-up of the CAV, given its high accuracy for the identification of micro- and macrovascular allograft vasculopathy. If CAV is detected early in these patients, improvements in clinical outcomes could be made through adequate medication management.^{5,6}

Study Limitations

The most obvious limitation of our study is its small sample size, resulting from the complexity of the study and the rigorous patient selection made to ensure the validity of our observations. Different pharmacologic stressors were used for each technique (adenosine for the calculation of IHDVPS and dobutamine for MPRI). Although the stress generated on both tests appeared to be equal and this approach has been used in the past,¹⁵ we cannot guarantee there are no differences derived from using different drugs. Although perfusion analysis was performed at segment 8 (midanteroseptal) because the Doppler-wire was positioned in the midleft anterior descending artery, evaluation of alternative segments (including those supplied by the circumflex or right coronary artery) should be assessed in specific protocols.

CONCLUSIONS

The quantitative, fully available MR perfusion index comparing stress/rest time-intensity-curves upslopes, MPRI, had an excellent correlation with a histologically validated Doppler-wire intracoronary index for the detection of microvascular allograft vasculopathy in a functionally pure microvascular scenario (nonsignificant coronary stenosis at angiography and negative wall-motion at dobutamine stress MR). We propose MPRI for the study and follow-up of HT patients for the detection and repercussion of microvascular allograft vasculopathy.

ACKNOWLEDGMENTS

We gratefully acknowledge our technicians for their excellent technical assistance during cardiac stress MR examinations and also Borja Ibañez PhD from *Centro Nacional de Investigaciones Cardiovasculares* (CNIC), Justin Davies from the Imperial College Healthcare and NHS Trust, London (United Kingdom), and Rolf Gebker from the German Heart Institute, Berlin (Germany) for their review of the manuscript and support of the project.

FUNDING

This work was partially supported by a grant from the Spanish Society of Cardiology (Clinical Research in Cardiology, 2009) and, the *Centro Nacional de Investigaciones Cardiovasculares* (CNIC), Madrid (Spain) (CardiImagen to J.G.M.) and the Spanish Ministry of Health (RD12/0042/0066).

CONFLICTS OF INTEREST

J. Escaned has served as speaker in educational activities organized by Boston Scientific, St Jude Medical and Volcano Corporation.

REFERENCES

- Hunt SA. Taking heart—cardiac transplantation past, present, and future. *N Engl J Med*. 2006;355:231–5.
- Jaramillo N, Segovia J, Gómez-Bueno M, García-Cosío D, Castedo E, Serrano S, et al. Características de los pacientes con supervivencia mayor de 20 años tras un trasplante cardíaco. *Rev Esp Cardiol*. 2013;66:797–802.
- Taylor DO, Edwards LB, Boucek MM, Trulock EP, Aurora P, Christie J, et al. Registry of the International Society for Heart and Lung Transplantation: Twenty-fourth Official Adult Heart Transplant Report—2007. *J Heart Lung Transplant*. 2007;26:769–81.
- Hiemann NE, Wellnhofer E, Knosalla C, Lehmkuhl HB, Stein J, Hetzer R, et al. Prognostic impact of microvasculopathy on survival after heart transplantation: evidence from 9713 endomyocardial biopsies. *Circulation*. 2007;116:1274–82.
- Abstracts of the International Society for Heart and Lung Transplantation 24th Annual Meeting, April 21–24, 2004. San Francisco, California, USA. *J Heart Lung Transplant*. 2004;23(2 Suppl):S42–183.
- Mancini D, Pinney S, Burkhoff D, LaManca J, Itescu S, Burke E, et al. Use of rapamycin slows progression of cardiac transplantation vasculopathy. *Circulation*. 2003;108:48–53.
- Alonso-Pulpón L, Segovia J, Gómez-Bueno M, García-Pavía P. Heart transplantation: organisational aspects and current trends in immunosuppression—a view from Spain. *Heart*. 2012;98:878–89.
- Mehra MR, Ventura HO, Stapleton DD, Smart FW, Collins TC, Ramee SR. Presence of severe intimal thickening by intravascular ultrasonography predicts cardiac events in cardiac allograft vasculopathy. *J Heart Lung Transplant*. 1995;14:632–9.
- Rickenbacher PR, Pinto F, Chenzbraun A, Botas J, Lewis N, Alderman E, et al. Incidence and severity of transplant coronary artery disease early and up to 15 years after transplantation as detected by intravascular ultrasound. *J Am Coll Cardiol*. 1995;25:171–7.
- Tuzcu EM, Hobbs RE, Rincon G, Bott-Silverman C, De Franco AC, Robinson K, et al. Occult and frequent transmission of atherosclerotic coronary disease with cardiac transplantation. Insights from intravascular ultrasound. *Circulation*. 1995;91:1706–13.
- Wolford TL, Donohue TJ, Bach RG, Drury JH, Caracciolo EA, Kern MJ, et al. Heterogeneity of coronary flow reserve in the examination of multiple individual allograft coronary arteries. *Circulation*. 1999;99:626–32.
- Mazur W, Bitar JN, Young JB, Khalil AA, Vardan S, Short BC, et al. Progressive deterioration of coronary flow reserve after heart transplantation. *Am Heart J*. 1998;136:504–9.
- Escaned J, Flores A, García-Pavía P, Segovia J, Jimenez J, Aragoncillo P, et al. Assessment of microcirculatory remodeling with intracoronary flow velocity and pressure measurements: validation with endomyocardial sampling in cardiac allografts. *Circulation*. 2009;120:1561–8.
- Nagel E, Lehmkuhl HB, Bocksch W, Klein C, Vogel U, Frantz E, et al. Noninvasive diagnosis of ischemia-induced wall motion abnormalities with the use of high-dose dobutamine stress MRI: comparison with dobutamine stress echocardiography. *Circulation*. 1999;99:763–70.
- Lanza GA, Buffon A, Sestito A, Natale L, Sgueglia GA, Galiuto L, et al. Relation between stress-induced myocardial perfusion defects on cardiovascular magnetic resonance and coronary microvascular dysfunction in patients with cardiac syndrome X. *J Am Coll Cardiol*. 2008;51:466–72.
- Muehling OM, Wilke NM, Panse P, Jerosch-Herold M, Wilson BV, Wilson RF, et al. Reduced myocardial perfusion reserve and transmural perfusion gradient in heart transplant arteriopathy assessed by magnetic resonance imaging. *J Am Coll Cardiol*. 2003;42:1054–60.
- Paetsch I, Jahnke C, Wahl A, Gebker R, Neuss M, Fleck E, et al. Comparison of dobutamine stress magnetic resonance, adenosine stress magnetic resonance, and adenosine stress magnetic resonance perfusion. *Circulation*. 2004;110:835–42.
- Steen H, Merten C, Refle S, Klingenberg R, Dengler T, Giannitsis E, et al. Prevalence of different gadolinium enhancement patterns in patients after heart transplantation. *J Am Coll Cardiol*. 2008;52:1160–7.
- Al-Saadi N, Nagel E, Gross M, Bornstedt A, Schnackenburg B, Klein C, et al. Noninvasive detection of myocardial ischemia from perfusion reserve based on cardiovascular magnetic resonance. *Circulation*. 2000;101:1379–83.
- Jerosch-Herold M, Seethamraju RT, Swingen CM, Wilke NM, Stillman AE. Analysis of myocardial perfusion MRI. *J Magn Reson Imaging*. 2004;19:758–70.
- Schwittler J, Nanz D, Kneifel S, Bertschinger K, Buchi M, Knusel PR, et al. Assessment of myocardial perfusion in coronary artery disease by magnetic resonance: a comparison with positron emission tomography and coronary angiography. *Circulation*. 2001;103:2230–5.
- Nagel E, Klein C, Paetsch I, Hettwer S, Schnackenburg B, Wegscheider K, et al. Magnetic resonance perfusion measurements for the noninvasive detection of coronary artery disease. *Circulation*. 2003;108:432–7.
- Cerqueira MD, Weissman NJ, Dilsizian V, Jacobs AK, Kaul S, Laskey WK, et al.; American Heart Association Writing Group on Myocardial Segmentation and Registration for Cardiac Imaging. Standardized myocardial segmentation and nomenclature for tomographic imaging of the heart. A statement for healthcare professionals from the Cardiac Imaging Committee of the Council on Clinical Cardiology of the American Heart Association. *Circulation*. 2002;105:539–42.
- St Goar FG, Pinto FJ, Alderman EL, Valantine HA, Schroeder JS, Gao SZ, et al. Intracoronary ultrasound in cardiac transplant recipients. In vivo evidence of “angiographically silent” intimal thickening. *Circulation*. 1992;85:979–87.
- Botas J, Pinto FJ, Chenzbraun A, Liang D, Schroeder JS, Oesterle SN, et al. Influence of preexistent donor coronary artery disease on the progression of transplant vasculopathy. An intravascular ultrasound study. *Circulation*. 1995;92:1126–32.
- Kern MJ, De Bruyne B, Pijls NH. From research to clinical practice: current role of intracoronary physiologically based decision making in the cardiac catheterization laboratory. *J Am Coll Cardiol*. 1997;30:613–20.
- Meuwissen M, Chamuleau SA, Siebes M, Schotborgh CE, Koch KT, De Winter RJ, et al. Role of variability in microvascular resistance on fractional flow reserve and coronary blood flow velocity reserve in intermediate coronary lesions. *Circulation*. 2001;103:184–7.
- Di Mario C, Krams R, Gil R, Serruys PW. Slope of the instantaneous hyperemic diastolic coronary flow velocity-pressure relation. A new index for assessment of the physiological significance of coronary stenosis in humans. *Circulation*. 1994;90:1215–24.
- Murthy VL, Naya M, Foster CR, Gaber M, Hainer J, Klein J, et al. Association between coronary vascular dysfunction and cardiac mortality in patients with and without diabetes mellitus. *Circulation*. 2012;126:1858–68.
- Wu KC, Zerhouni EA, Judd RM, Lugo-Olivieri CH, Barouch LA, Schulman SP, et al. Prognostic significance of microvascular obstruction by magnetic resonance imaging in patients with acute myocardial infarction. *Circulation*. 1998;97:765–72.
- Bodi V, Sanchis J, Nunez J, Mainar L, Lopez-Lereu MP, Monmeneu JV, et al. Prognostic value of a comprehensive cardiac magnetic resonance assessment soon after a first ST-segment elevation myocardial infarction. *JACC Cardiovasc Imaging*. 2009;2:835–42.
- De Bruyne B, Hersbach F, Pijls NH, Bartunek J, Bech JW, Heyndrickx GR, et al. Abnormal epicardial coronary resistance in patients with diffuse atherosclerosis but “normal” coronary angiography. *Circulation*. 2001;104:2401–6.
- Melikian N, Vercauteren S, Fearon WF, Cuisset T, MacCarthy PA, Davidavicius G, et al. Quantitative assessment of coronary microvascular function in patients with and without epicardial atherosclerosis. *EuroIntervention*. 2010;5:939–45.
- Spaan JA, Piek JJ, Hoffman JJ, Siebes M. Physiological basis of clinically used coronary hemodynamic indices. *Circulation*. 2006;113:446–55.
- Bartunek J, Wijns W, Heyndrickx GR, De Bruyne B. Effects of dobutamine on coronary stenosis physiology and morphology: comparison with intracoronary adenosine. *Circulation*. 1999;100:243–9.
- Wahl A, Paetsch I, Gollesch A, Roethemeyer S, Foell D, Gebker R, et al. Safety and feasibility of high-dose dobutamine-atropine stress cardiovascular magnetic resonance for diagnosis of myocardial ischaemia: experience in 1000 consecutive cases. *Eur Heart J*. 2004;25:1230–6.
- Epstein AE, Hirschowitz BI, Kirklin JK, Kirk KA, Kay GN, Plumb VJ. Evidence for a central site of action to explain the negative chronotropic effect of atropine: studies on the human transplanted heart. *J Am Coll Cardiol*. 1990;15:1610–7.