

Original article

LEOPARD Syndrome: A Variant of Noonan Syndrome Strongly Associated With Hypertrophic Cardiomyopathy

Atilano Carcavilla,^{a,b,*} José L. Santomé,^b Isabel Pinto,^c Jaime Sánchez-Pozo,^d Encarna Guillén-Navarro,^e María Martín-Frías,^f Pablo Lapunzina,^g and Begoña Ezquieta^b^a Servicio de Pediatría, Hospital Virgen de la Salud, Toledo, Spain^b Laboratorio de Genética Molecular, Hospital General Universitario Gregorio Marañón, Instituto de Investigación Sanitaria Gregorio Marañón, Madrid, Spain^c Servicio de Pediatría, Hospital Severo Ochoa, Leganés, Madrid, Spain^d Servicio de Pediatría, Hospital Universitario 12 de Octubre, Madrid, Spain^e Unidad de Genética Médica, Servicio de Pediatría, Hospital Universitario Virgen de la Arrixaca, El Palmar, Murcia, Spain^f Servicio de Pediatría, Hospital Universitario Ramón y Cajal, Madrid, Spain^g Instituto de Genética Médica y Molecular, Hospital Universitario La Paz, Madrid, Spain

Article history:

Received 18 May 2012

Accepted 22 September 2012

Available online 11 January 2013

Keywords:

Noonan syndrome

LEOPARD syndrome

Multiple lentiginos

Hypertrophic cardiomyopathy

RAS-MAPK genes

ABSTRACT

Introduction and objectives: LEOPARD syndrome is an autosomal dominant condition related to Noonan syndrome, although it occurs less frequently. The aim of this study was to characterize the clinical and molecular features of a large series of LEOPARD syndrome patients.**Methods:** We collected clinical data from 19 patients in 10 hospitals. Bidirectional sequencing analysis of *PTPN11*, *RAF1*, and *BRAF* focused on exons carrying recurrent mutations.**Results:** After facial dysmorphism, structural heart defects (88%) were the most common feature described. Hypertrophic cardiomyopathy (71%) was diagnosed more often than pulmonary valve stenosis (35%). Multiple lentiginos or café au lait spots were found in 84% of the series, and deafness was diagnosed in 3 patients. Mutations in *PTPN11* were identified in 16 (84%) patients (10 patients had the recurrent LEOPARD syndrome mutation, p.Thr468Met) (NP_002825.3T468M). Two other patients had a mutation in *RAF*, and 1 patient had a mutation in *BRAF*. When compared with other neurocardiofaciocutaneous syndromes, LEOPARD syndrome patients showed a higher prevalence of hypertrophic cardiomyopathy and cutaneous abnormalities, and a lower prevalence of pulmonary valve stenosis and short stature.**Conclusions:** LEOPARD syndrome patients display distinctive features apart from multiple lentiginos, such as a higher prevalence of hypertrophic cardiomyopathy and lower prevalence of short stature. Given its clinical implications, active search for hypertrophic cardiomyopathy is warranted in Noonan syndrome spectrum patients, especially in LEOPARD syndrome patients.

© 2012 Sociedad Española de Cardiología. Published by Elsevier España, S.L. All rights reserved.

Síndrome LEOPARD: una variante del síndrome de Noonan con fuerte asociación a miocardiopatía hipertrófica

RESUMEN

Introducción y objetivos: El síndrome LEOPARD es una enfermedad autosómica dominante relacionada con el síndrome de Noonan, aunque menos conocida. El objetivo del presente estudio es describir las características clínicas y moleculares de una serie amplia de pacientes con síndrome LEOPARD.**Métodos:** Se obtuvieron datos clínicos de 19 pacientes procedentes de 10 hospitales. Se estudiaron los genes *PTPN11*, *RAF1* y *BRAF* mediante secuenciación bidireccional de los exones más recurrentes.**Resultados:** Tras las dismorfias faciales, la principal característica descrita es la cardiopatía congénita (88%). La más frecuente es la miocardiopatía hipertrófica (71%), por delante de la estenosis pulmonar (35%). Se describió lentiginos múltiple o manchas café con leche en un 84% y sordera en 3 pacientes; 16 pacientes (84%) portaban mutación en *PTPN11* (en 10 de ellos, la mutación recurrente en el síndrome LEOPARD, p.Thr468Met) (NP_002825.3). En otros 2 pacientes se identificó mutación en *RAF1* y 1 solo en *BRAF*. En comparación con otros síndromes neurocardiofaciocutáneos, los pacientes con LEOPARD tienen mayor prevalencia de miocardiopatía hipertrófica y lesiones cutáneas y menor prevalencia de estenosis pulmonar y talla baja.**Conclusiones:** El síndrome LEOPARD presenta algunas características distintivas además de la lentiginos múltiple, como son la mayor frecuencia de miocardiopatía hipertrófica y menor prevalencia de talla baja. Dadas las potenciales implicaciones clínicas de la miocardiopatía hipertrófica, se debe

Palabras clave:

Síndrome de Noonan

Síndrome LEOPARD

Lentiginos múltiple

Miocardiopatía hipertrófica

Genes RAS-MAPK

* Corresponding author: Servicio de Pediatría, Hospital Virgen de la Salud, Avda. Barber 30, 45004 Toledo, Spain.

E-mail address: atcarcavilla@gmail.com (A. Carcavilla).

buscar activamente en los pacientes del espectro clínico del síndrome de Noonan, y muy especialmente en aquellos con síndrome LEOPARD.

© 2012 Sociedad Española de Cardiología. Publicado por Elsevier España, S.L. Todos los derechos reservados.

Abbreviations

LS: LEOPARD syndrome

NCFCS: neurocardiofaciocutaneous syndromes

NS: Noonan syndrome

INTRODUCTION

LEOPARD syndrome (LS), or Noonan syndrome (NS) with multiple lentigines (OMIM 151100), is an autosomal dominant disorder characterized by multiple lentigines or *café au lait* spots, electrocardiographic abnormalities, ocular hypertelorism, pulmonary valve stenosis or hypertrophic cardiomyopathy, genital abnormalities, constitutional growth delay, and deafness.¹ LS shares many features with NS (OMIM 163950), which is characterized by an association with congenital heart disease, short stature, and craniofacial malformations² but does not usually include multiple lentigines and deafness among its manifestations. Mutations have been identified in the *PTPN11* gene in 50% of NS^{3–5} cases and in 85% of LS cases.^{6,7} Mutations in the *RAF1*⁸ and *BRAF*⁹ genes have also been identified in LS. Although there are no exact data on its prevalence, it is thought that NS is present in 1 in 1000 to 2500 live births, suggesting that it is an underdiagnosed disorder.¹⁰ LS is less frequent, although precise data on its prevalence at birth are also unavailable. To date, at least 200 cases have been reported in the literature and a comprehensive review of the disorder has been published recently.¹¹ Both disorders show considerable phenotypic variability, making them difficult to identify and diagnose correctly. Genetic studies can therefore provide a useful contribution to differential diagnosis. Diagnosis is also made difficult by the evolving and changeable nature of many of the condition's features. For that reason, any objectifiable congenital heart disease can provide valuable help in identifying the syndrome. We present a phenotypic description of a series of patients with LS characterized in genetic studies of the *PTPN11*, *RAF1*, and *BRAF* genes, and compare them with a large series of patients with other neurocardiofaciocutaneous syndromes (NCFCS) who were also characterized by the genetic study of mutations in the *PTPN11*, *SOS1*, *RAF1*, *BRAF*, and *HRAS* genes.

METHODS

Clinical Evaluation

Patients were evaluated by clinical geneticists and pediatric cardiologists or endocrinologists involved in a Spanish multicenter study of genotype-phenotype relationships, and were diagnosed with LS using the criteria described by Voron et al.¹² Blood samples or patient DNA were sent to our center from participating hospitals by the attending clinicians, who had previously obtained informed consent from patients. An initial clinical evaluation based on the preanalytical questionnaire described by Ezquieta et al.¹³ was used for case selection. Data on clinical characteristics relating to congenital heart conditions, skin changes, weight-to-height ratio, hearing problems, genital abnormalities, and patient facial characteristics were collected and stored in an Access database

whose structure had been agreed among the clinicians involved. Facial phenotype was classified as typical when three or more of the following malformations were present: ocular hypertelorism, ptosis, low-set ears, and downward inclination of the palpebral fissures, and as suggestive when this criterion was not met. Height was assessed in standard deviations from a reference population¹⁴ and was considered low at <-2 standard deviations. All patients underwent electrocardiography and echocardiography evaluated by a pediatric cardiologist. Pulmonary valve stenosis was diagnosed using classic ultrasound criteria. Hypertrophic cardiomyopathy was diagnosed when the thickness of the left ventricular anterior wall was >2 standard deviations by age.

In 2 patients diagnosed with NS in which the genetic study identified a typical LEOPARD mutation, the patients' evolution was monitored. The appearance of multiple lentigines was later confirmed, leading to a modification of the diagnosis (cases 1 and 8). With regard to the familial cases, a family of 3 members was evaluated clinically from the outset (family A), and subsequent genetic study confirmed the initial suspicion. In the other familial case evaluated (family B), the molecular study identified the mother of the index case as the mutation carrier, which led to further clinical study.

For the group of patients with other NCFCS, we used interim data from the same multicenter genotype-phenotype correlation study, which is still ongoing.^{13,15} For patients with NS, Van der Burgt's diagnostic criteria were used¹⁰; in those with cardiofaciocutaneous syndrome we used the cardiofaciocutaneous index,¹⁶ and where Costello syndrome was suspected, the diagnosis was considered confirmed if the *HRAS* mutation was identified.¹⁷ Clinical data for all of these patients were collected using the same methodology described for patients with LS.

Mutation Testing

Blood samples were obtained from patients and their families after they had provided informed consent. Genomic DNA was extracted using standard procedures. Polymerase chain reaction amplification was performed using the primers and cycling parameters originally described by Tartaglia et al.¹⁸ This was followed by bidirectional sequencing of the coding regions and adjacent intronic regions using an ABI Prism Genotyper[®]. The SeqScape 2.5 software was used to analyze the electrophoretograms obtained.

Statistical Analysis

Statistical analysis was performed using Fisher exact test. Statistical significance was set at $P < .05$. The analysis was performed using SPSS 19.0.

RESULTS

The study included 19 patients (13 men, 6 women; age at diagnosis, 11 months to 49 years; mean age, 7.4 years). Cases were referred from 9 hospitals in 5 Spanish regions and 1 hospital in Belgrade (Serbia). Five patients were identified as familial cases (families A and B; 26% of cases; 95% confidence interval [95%CI], 9.1%–51.2%), and the rest were considered sporadic.

Table 1
Clinical and Molecular Characteristics of 19 Patients With LEOPARD Syndrome

Patient	Family	Age, years	Sex	Heart disease	Facies	Stature, SD	Skin	Gene	Mutation	PMR	Other anomalies
<i>Complete LEOPARD phenotype with genetic confirmation</i>											
1		3	F	Pulmonary stenosis	Typical	-2.09	Multiple lentigines. Café au lait spots	<i>PTPN11</i>	T468M	No	Broad chest
2	A	4	M	Hypertrophic cardiomyopathy	Suggestive	-1.45	Multiple lentigines. Café au lait spots	<i>PTPN11</i>	T468M	No	Wolf-Parkinson-White
3	A	9	M	Hypertrophic cardiomyopathy	Suggestive	-0.91	Multiple lentigines. Café au lait spots	<i>PTPN11</i>	T468M	No	
4	A	49	M	Hypertrophic cardiomyopathy	Suggestive	-0.1	Multiple lentigines.	<i>PTPN11</i>	T468M	No	
5	B	1	M	Pulmonary stenosis	Suggestive	-2.6	Multiple lentigines. Café au lait spots	<i>PTPN11</i>	Y279C	Mild	Mixed hearing loss
6	B	NA, adult	F	NA	Suggestive	-1.36	Multiple lentigines. Café au lait spots	<i>PTPN11</i>	Y279C	No	
7		11	M	Hypertrophic cardiomyopathy	Typical	-1.63	Multiple lentigines. Café au lait spots	<i>PTPN11</i>	T468M	Mild	
8		3	M	NA	Typical	-2.82	Multiple lentigines.	<i>PTPN11</i>	Q510R	No	
9		8	F	Hypertrophic cardiomyopathy	Suggestive	-2.61	Multiple lentigines. Café au lait spots	<i>RAF1</i>	S257L	Mild	SVT. <i>Pectus excavatum</i>
10		4	M	Hypertrophic cardiomyopathy	Suggestive	-0.96	Multiple lentigines.	<i>PTPN11</i>	T468M	No	<i>Pectus excavatum</i>
11		2	M	Hypertrophic cardiomyopathy. Pulmonary stenosis	Suggestive	-5.02	Multiple lentigines. Café au lait spots	<i>RAF1</i>	S257L	Mild	Cryptorchidism, <i>pectus excavatum</i>
12		3	F	Cardiological evaluation normal	Suggestive	-1.36	Multiple lentigines. Café au lait spots	<i>PTPN11</i>	Y279C	No	
13		24	M	Hypertrophic cardiomyopathy	Suggestive	-2.14	Multiple lentigines.	<i>BRAF</i>	Q257R	Mild	Cryptorchidism
14		2	M	Hypertrophic cardiomyopathy, Pulmonary stenosis	Typical	-3.44	Multiple lentigines. Café au lait spots	<i>PTPN11</i>	Y279C	No	<i>Pectus excavatum</i>
15		2	M	Hypertrophic cardiomyopathy	Suggestive	-1.71	Multiple lentigines. Café au lait spots	<i>PTPN11</i>	Y279C	No	
<i>Partial LEOPARD phenotype with characteristic mutation</i>											
16		1.11	M	Pulmonary stenosis	Suggestive	-0.9	Normal	<i>PTPN11</i>	T468M	No	
17		0.8	F	Pulmonary stenosis, Hypertrophic cardiomyopathy	Suggestive	-0.82	Café au lait spots	<i>PTPN11</i>	T468M	Mild	
18		2	F	Cardiological evaluation normal	Suggestive	0.04	Normal	<i>PTPN11</i>	T468M	No	
19		14	M	Hypertrophic cardiomyopathy	Suggestive	-1	Normal	<i>PTPN11</i>	T468M	Mild	Cryptorchidism, <i>pectus excavatum</i> and <i>carinatum</i>

F, female; M, male; NA, not available; PMR, psychomotor retardation; SD, standard deviation; SVT, supraventricular tachycardias. Familial cases are marked with letters (A and B). Cases 2 and 5 are the index cases of families A and B, respectively.

Table 1 summarizes the phenotypic and molecular findings. Of the total, 15 met Voron's clinical criteria and 4 were considered to have a "partial form of LS". The latter had clinical features typical of LS but did not have multiple lentigine syndrome or a family history of LS. All four were carriers of the p.Thr468Met mutation in *PTPN11*, which is typical of LS, and were of pediatric age at the time of the evaluation. The cutaneous features of the syndrome may therefore appear over time as the patients develop. Craniofacial (100% when typical and suggestive phenotypes were included; 95%CI, 82.4%-100%) and cardiac (88%; 95%CI, 63.6%-98.5%) anomalies, and skin lesions (84%; 95%CI, 60.4%-96.6%) were the most frequently reported characteristics, followed by short stature (37%; 95%CI, 16.3%-61.6%) and genital abnormalities (cryptorchidism in 3 patients, representing 16% of the total and 23% of men, 95%CI, 5%-53.8%). Three patients were diagnosed with hearing loss, but a sensorineural component was only observed in 1 individual (5%; 95%CI, 0.1%-26%); 7 patients had psychomotor retardation

(37%; 95%CI, 16.3%-61.6%), although it was only mild in all cases. The 15 patients with multiple lentigines had a complete phenotype (79%; 95%CI, 54.4%-93.9%) and 11 of them also had café-au-lait spots (58%; 95%CI, 33.5%-79.7%). One patient with a partial phenotype also had coffee stains, while the other 3, aged between 10 months and 14 years, had no skin lesions. Two unrelated patients (patient numbers 1 and 8, with mutations p.Thr468Met and p.Gln510Arg, respectively) showed no skin manifestations at the initial assessment but developed the characteristic multiple lentigines during follow-up, which highlights the condition's evolving nature.

The most frequent congenital heart disease was hypertrophic cardiomyopathy (71%; 95%CI, 44%-89.7%), followed by pulmonary valve stenosis (35%; 95%CI, 14.2%-61.7%). Three patients (18%; 95%CI, 3.8%-43.4%) had both disorders. The only other congenital heart disease observed was aortic coarctation in 1 patient who also had hypertrophic cardiomyopathy. Coarctation in this patient

Table 2

Comparison of Some Phenotypic Traits Among Patients With LEOPARD Syndrome and Patients With Other Neurocardiofaciocutaneous Syndromes

	LS	NS	<i>P</i> ^a	CFCS	CS	Other NCFCS	<i>P</i> ^b
Patients, n	19	87		5	1	93	
Mutated genes (<i>PTPN11</i> , <i>SOS1</i> , <i>RAF1</i> , <i>BRAF</i> , <i>HRAS</i>)	16/0/2/1/0	68/15/4/0/0		0/0/0/5/0	0/0/0/0/1	68/15/4/5/1	
Sex, females/males	6/13	34/53	.60	2/3	0/1	36/57	.61
Age (years), mean (range)	7.4 (0.92–49)	9.5 (0–48.7)	.23	4.1 (2.62–5.54)	0.25	9.21 (0–48.7)	.3
Indices/familial	14/5	81/6	.18	5/0	1/0	87/66	.16
Stature, SD	–1.82±1.17	–2.59±1.69	.009	–2.96±0.99	–2.48	–2.61±1.65	.017
Weight, SD	–1.36±0.6	–1.84±1.03	.073	–2.84±1.32	–2.18	–1.88±1.03	.052
Short stature, ≤–2 SD	37%	67%	.018	5/5	1/1	69.7%	.009
Head circumference, SD	–0.35±1.64	–1.55±1.47	.1	NA	0	–1.47±1.46	.12
Typical/suggestive facies	26%	23%	.77	1/5	0/1	22.5%	.77
Pulmonary stenosis	35%	70.4%	.009	2/5	0/1	68%	.021
Hypertrophic cardiomyopathy	71%	12.3%	<.001	2/5	1/1	14%	<.001
Other heart diseases	0%	11.1%	.352	0/5	0/1	10.3%	.35
No heart disease	11.7%	6.2%	.601	1/5	0/1	6.9%	.39
Sensorineural hearing loss	5%	2.7%	.552	0/4	NE	2%	.328
Cryptorchidism, males	23%	62.5%	.077	3/3	0/1	63.3%	.066
Multiple lentigines	79%	0%	<.001	0/5	0/1	0%	<.001
<i>Café au lait</i> spots	57.9%	8.1%	<.001	0/5	0/1	7.1%	<.001
<i>Pectus excavatum</i>	26.3%	19.5%	.538	1/5	0/1	19.4%	.536
<i>Pectus carinatum</i>	5.2%	11.5%	.684	0/5	0/1	10.6%	.687
Barrel chest	15.8%	10.3%	.447	1/5	0/1	10.8%	.46
Mental retardation	37%	47.6%	.331	3/4	NE	51.1%	.76

CFCS, cardiofaciocutaneous syndrome; CS, Costello syndrome; LS, LEOPARD syndrome; NA, not available; NCFCS, neurocardiofaciocutaneous syndromes; NE, not evaluable; NS, Noonan syndrome; SD, standard deviations.

LS: 15 patients with full LEOPARD phenotype and 4 patients with partial LEOPARD phenotype and T468 M mutation in *PTPN11* (data expressed as a percentage).

NS: 87 patients with genetically confirmed NS.

CFCS: 5 patients with genetically confirmed CFCS (data expressed in ratios).

CS: 1 case of genetically confirmed CS (data expressed in ratios).

Other NCFCS: patients with NCFCS other than LEOPARD (NS+CFCS+CS; data expressed as a percentage).

^a Statistical comparison between patients with LS and NS patients.

^b Statistical comparison between patients with LS and other NCFCS.

resolved without corrective surgery, which would challenge the diagnosis of hypertrophic cardiomyopathy, although cardiomyopathy persisted several years after coarctation resolved. Only 2 (12%; 95%CI, 1.5%–36.4%) of the patients tested had regular cardiac testing. One patient was diagnosed at 2 months of age with Wolf-Parkinson-White syndrome following an episode of supraventricular tachycardia. One other patient also suffered supraventricular tachycardias. No patient experienced sudden death or required defibrillator implantation.

Molecular analysis of the *PTPN11*, *RAF1*, and *BRAF* genes detected mutations in 19 patients. The most frequent mutation was p.Thr468Met (10 patients, 53%; 95%CI 28.9%–75.6%). The p.Tyr279Cys amino acid change was identified in 2 related patients (mother and son, family B) and 3 unrelated patients (26% of the total series; 95%CI, 9.2%–51.2%). The p.Ser257Leu variant in *RAF1* was detected in 2 other unrelated patients. Patients with mutations in *RAF1* showed hypertrophic cardiomyopathy and some of the smallest statures in the series. Finally, we detected a change in the *BRAF* gene sequence in 1 patient.

To compare patients with LS and patients with other NCFCS, we included 87 patients with NS (*PTPN11* mutation, 68 patients, 78%; *SOS1* mutation, n=15, 17%; *RAF1* mutation, n=4, 5%), 5 with cardiofaciocutaneous syndrome with a *BRAF* mutation, and 1 patient with Costello syndrome due to a mutation in *HRAS*. These patients came from 31 hospitals in 11 Spanish regions, 1 hospital in Belgrade (Serbia), and 1 hospital in Buenos Aires (Argentina). Table 2 shows the clinical features of each of these patient groups, and as compared to the LS patients. LS is related to the presence of

multiple lentigines and *café au lait spots* ($P<.001$). Similarly, there is evidence of a strong association between LS and hypertrophic cardiomyopathy and greater height ($P<.05$).

DISCUSSION

As some authors have suggested, a classification of cardiomyopathies that takes into account their underlying molecular characteristics could contribute to more appropriate management.¹⁹ In the case of hypertrophic cardiomyopathy, the relevance of both NS and LS should be borne in mind.²⁰ This is particularly true when, from a cardiological perspective, the accompanying phenotype can vary from fatal cases to completely asymptomatic patients. Only a high level of suspicion will allow the clinician to consider this diagnostic option when there is little evidence.

In recent years, advances in molecular biology have allowed us to elucidate many aspects of the etiology of NS and other entities with overlapping phenotypes (LS, Costello syndrome, cardiofaciocutaneous syndrome, neurofibromatosis type 1, and Legius syndrome). Some authors group these disorders under the name of NCFCS,²¹ RAS-MAPK syndromes, or rasopathies, as it appears that Ras/MAPK pathway dysregulation lies at the root of all of them (Figure). In NS, *PTPN11* mutations have been identified in approximately 50% of patients, and mutations have been described in other genes of the RAS-MAPK pathway (*SOS1*,²² *RAF1*,⁸ *KRAS*,²³ *MAP2K1*,²⁴ *BRAF*,⁹ *NRAS*,²⁵ and *SHOC2*²⁶). Even today, there is no defined genetic cause in about 30% of patients diagnosed with NS.

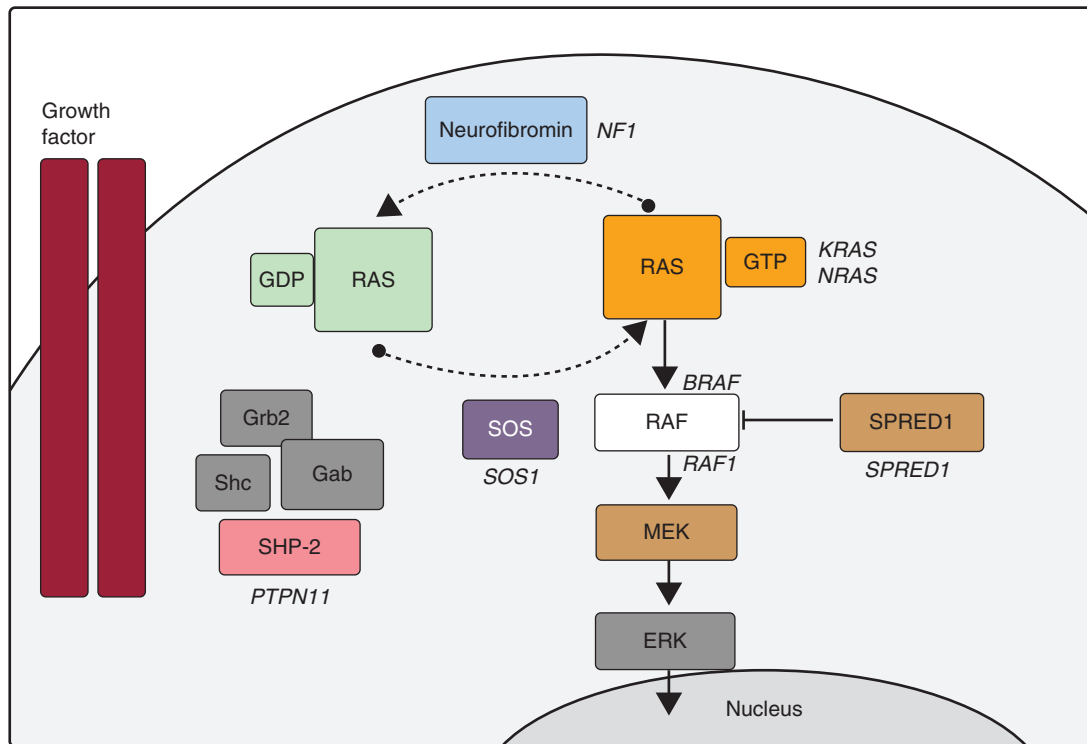


Figure. Ras-MAPK cascade. The binding of a growth factor to a tyrosine kinase receptor activates intracellular effectors such as SHP2, which in turn recruit guanine nucleotide exchange factors such as SOS1 that promote GDP/GTP exchange in RAS proteins. The latter are activated by phosphorylation. Consequently, Ras-GTP activates the different RAF isoforms (RAF1, BRAF), MEK (MEK1, MEK2) and, finally, ERK.

In LS, about 85% of patients have mutations in *PTPN11*. Eleven mutations have been described in *PTPN11* but, of those, 65% correspond to 2 highly recurrent mutations (p.Thr468Met7 and p.Tyr279Cys). In approximately one third of *PTPN11* negative patients, mutations have been identified in *RAF1*,⁸ another gene in the RAS-MAPK cascade. Finally, mutations have been reported in *BRAF*,^{9,27} a gene whose mutations were primarily associated with cardiofaciocutaneous syndrome.

In recent decades, molecular studies have proven useful in providing differential diagnoses between these overlapping entities, as illustrated by several cases in our series. Among our patients, p.Thr468Met was the most common mutation in *PTPN11*, followed by p.Tyr279Cys. During evolutionary monitoring of patients with the p.Thr468Met mutation, the appearance of multiple lentiginos led to a modification of the diagnosis in 2 cases. For that reason, and following previous authors,⁷ we considered pediatric patients with NS due to p.Thr468Met to be a partial phenotype of LS. Mutations with changes in amino-acid Gln510 have been associated with both NS and LS²⁸; in our series, there were patients diagnosed with NS who showed sequence changes that predicted amino acid changes due to other residues (p.Gln510Glu, p.Gln510Pro). As these were adult patients, no change in diagnosis was expected and they were not included in the study. Patient 8, on the other hand, had the p.Gln510Arg variant and developed lentiginos during pediatric clinical monitoring, a development which led to a modification of the diagnosis. In the case of *RAF1*, the p.Ser257Leu mutation was identified in 2 cases. In one patient who was negative for *PTPN11* and *RAF1*, the *BRAF* mutation was identified, a finding which shows the relevance of studying this gene in patients with LS. Our study confirms the substantial benefits of carrying out genetic studies in patients with LS, and illustrates its close association with the *PTPN11* gene and, to a lesser extent, *RAF1* and *BRAF*.

The main diagnostic features of this syndrome are its cutaneous manifestations, which sometimes do not fully develop until after puberty^{29,30}; deafness, which is not as common as in the initial descriptions of the syndrome; and congenital heart disease. Although pulmonary valve stenosis was initially described as the most common heart disease observed, hypertrophic cardiomyopathy is now more frequently identified.^{7,11,31} In our series, this congenital heart condition was more significantly associated with LS than were other NCFCS. In our setting, congenital heart disease has led to the definitive diagnosis in a large proportion of cases, and remains the most dangerous comorbidity in these patients.³² Pulmonary valve stenosis was identified in 6 of our 19 patients, making it the second most common cardiac diagnosis. Three patients had both conditions simultaneously. Both diagnoses should lead us to consider the possibility of a broader malformation. The 3-year-old patient in whom no congenital heart disease was found remains under observation in order to rule out the evolutionary occurrence of structural heart abnormalities, as described previously.³³ Although in our series there were no fatal events and defibrillator use was not required in any of the patients, the oldest in the series was referred to a cardiac unit for further study because of syncope. In fact, it has been reported that LS patients with hypertrophic cardiomyopathy appear to be at increased risk of adverse events during follow-up.³² Among the cardiac disorders, although conduction defects are frequent, the Wolf-Parkinson-White syndrome described in one of our patients is not a common manifestation.

The phenotypic overlap between LS, NS, and neurofibromatosis type 1 makes it difficult to correctly classify these patients. Noonan syndrome-neurofibromatosis syndrome, which is related to mutations in the *NF1* gene³⁴ and characterized by the association between neurofibromatosis type 1 and NS manifestations, presents characteristics that are very similar to LS. The diagnosis of a

congenital heart condition such as hypertrophic cardiomyopathy in patients with Noonan syndrome-neurofibromatosis makes it advisable to start with a genetic study of *PTPN11* rather than with *NF1*.³⁵ Multiple lentiginos and *café au lait* spots are common in all 3 entities. Just as *café au lait* spots increase in number and size with age in these entities, multiple lentiginos are rare in younger children. For this reason, some authors recommend evaluating for LS when diagnosing a patient younger than 1 year of age with NS associated with *café au lait* spots.²⁹ Distinguishing between multiple lentiginos and nevi may be particularly complex in some patients, and some authors propose including melanocytic lesions in the LS spectrum.³⁶ In our series, the diagnosis was limited, whenever possible, to patients with lentiginous lesions. This is illustrated by a case described in Ezquieta et al.¹³ The patient suffered NS stemming from the p.Asn308Asp amino acid change in *PTPN11* and had multiple hyperpigmented lesions, as did his mother, who had tested negative in the mutation study. These results indicated that the multiple nevus lesions observed in mother and child were due to a cause other than mutations in *PTPN11*. As indicated in earlier observations, we have demonstrated that LS is associated with a taller stature than other NCFCS.

CONCLUSIONS

Pulmonary valve stenosis and particularly hypertrophic cardiomyopathy are cardiological findings which may provide the key to identifying the syndrome. Given the potential clinical implications of hypertrophic cardiomyopathy, patients within the clinical spectrum of NS and particularly those with LS should be actively evaluated for this disease. The criteria originally described by Voron et al. in 1976 are still helpful in classifying these patients in terms of diagnosis. Nevertheless, the carriers of LS-associated anomalies that do not meet these criteria should be monitored over time because some skin manifestations, particularly multiple lentiginos, may be delayed until late puberty.

ACKNOWLEDGEMENTS

The authors would like to thank the patients and their families for collaborating on the study as well as the clinicians who could not be included as authors. They include Drs. López-Siguero (*Hospital Carlos Haya*, Málaga), Barrio, and García-Sagredo (*Hospital Ramón y Cajal*, Madrid), Kuburovic (Mother and Child Healthcare Institute, Serbia), Gracia (*Hospital Universitario La Paz*, Madrid), Gener Querol (*Hospital Universitario de Cruces*, Barakaldo, Vizcaya), González-Meneses (*Hospital Virgen del Rocío*, Sevilla) and Aleixandre Blanquer (*Hospital General Universitario de Elda*, Alicante). Begoña Ezquieta is a researcher attached to U753 of the CIBER de *Enfermedades Raras*.

FUNDING

Fondo de Investigaciones Sanitarias (PI 06/1179).

CONFLICTS OF INTEREST

None declared.

REFERENCES

- Gorlin RJ, Anderson RC, Moller JH. The LEOPARD (multiple lentiginos) syndrome revisited. *Birth Defects Orig Artic Ser*. 1971;7:110–5.
- Noonan JA. Hypertelorism with Turner phenotype. A new syndrome with associated congenital heart disease. *Am J Dis Child*. 1968;116:373–80.
- Tartaglia M, Martinelli S, Stella L, Bocchinfuso G, Flex E, Cordeddu V. Diversity and functional consequences of germline and somatic *PTPN11* mutations in human disease. *Am J Hum Genet*. 2006;78:279–90.
- Tartaglia M, Mehler EL, Goldberg R, Zampino G, Brunner HG, Kremer H. Mutations in *PTPN11*, encoding the protein tyrosine phosphatase SHP-2, cause Noonan syndrome. *Nat Genet*. 2001;29:465–8.
- Kosaki K, Suzuki T, Muroya K, Hasegawa T, Sato S, Matsuo N. *PTPN11* (protein-tyrosine phosphatase, nonreceptor-type 11) mutations in seven Japanese patients with Noonan syndrome. *J Clin Endocrinol Metab*. 2002;87:3529–33.
- Ogata T, Yoshida R. *PTPN11* mutations and genotype-phenotype correlations in Noonan and LEOPARD syndromes. *Pediatr Endocrinol Rev*. 2005;2:669–74.
- Sarkozy A, Conti E, Digilio MC, Marino B, Morini E, Pacileo G. Clinical and molecular analysis of 30 patients with multiple lentiginos LEOPARD syndrome. *J Med Genet*. 2004;41:e68.
- Pandit B, Sarkozy A, Pennacchio LA, Carta C, Oishi K, Martinelli S. Gain-of-function *RAF1* mutations cause Noonan and LEOPARD syndromes with hypertrophic cardiomyopathy. *Nat Genet*. 2007;39:1007–12.
- Sarkozy A, Carta C, Moretti S, Zampino G, Digilio MC, Pantaleoni F. Germline *BRAF* mutations in Noonan, LEOPARD, and cardiofaciocutaneous syndromes: molecular diversity and associated phenotypic spectrum. *Hum Mutat*. 2009;30:695–702.
- Van der Burgt I. Noonan syndrome. *Orphanet J Rare Dis*. 2007;14:2–4.
- Sarkozy A, Digilio MC, Dallapiccola B. LEOPARD syndrome. *Orphanet J Rare Dis*. 2008;3:13.
- Voron DA, Hatfield HH, Kalkhoff RK. Multiple lentiginos syndrome: case report and review of the literature. *Am J Med*. 1976;60:447–56.
- Ezquieta B, Santomé JL, Carcavilla A, Guillén-Navarro E, Pérez-Aytés A, Sánchez del Pozo J, et al. Alteraciones de los genes de la vía RAS-MAPK en 200 pacientes españoles con síndrome de Noonan y otros síndromes neurocardiofaciocutáneos, Genotipo y cardiopatía. *Rev Esp Cardiol*. 2012;65:447–55.
- Carrascosa Lezcano A, Fernández García JM, Fernández Ramos C, Ferrández Longás A, López-Siguero JP, Sánchez E, et al. Estudio transversal español de crecimiento 2008, Parte II: valores de talla, peso e índice de masa corporal desde el nacimiento a la talla adulta. *An Pediatr (Barc)*. 2008;68:552–69.
- Carcavilla A, Santomé JL, Galbis L, Ezquieta B. Síndrome de Noonan: aspectos genéticos. In: XVIII Curso Postgrado SEEP. Actualización en Endocrinología pediátrica. Madrid: Sociedad de Española de Endocrinología Pediátrica; 2012. p. 41–61.
- Kavamura MI, Peres CA, Alchorne MM, Brunoni D. CFC index for the diagnosis of cardiofaciocutaneous syndrome. *Am J Med Genet*. 2002;112:12–6.
- Gripp KW, Lin AE. Costello syndrome: a Ras/mitogen activated protein kinase pathway syndrome (rasopathy) resulting from *HRAS* germline mutations. *Genet Med*. 2012;14:285–92.
- Tartaglia M, Kalidas K, Shaw A, Song X, Musat DL, Van der Burgt I, et al. *PTPN11* mutations in Noonan syndrome: molecular spectrum, genotype–phenotype correlation, and phenotypic heterogeneity. *Am J Hum Genet*. 2002;70:1555–63.
- Marín-García J. Avances en genética molecular de las cardiopatías congénitas. *Rev Esp Cardiol*. 2009;62:242–5.
- Sánchez Andrés A, Moriano Gutiérrez A, Carrasco Moreno JI. Miocardiopatía hipertrófica intraútero y síndrome de Noonan neonatal: una asociación a recordar. *Rev Esp Cardiol*. 2011;64:537–8.
- Denayer E, Legius E. What's new in the neuro-cardio-facial-cutaneous syndromes? *Eur J Pediatr*. 2007;166:1091–8.
- Roberts AE, Araki T, Swanson KD, Montgomery KT, Schiripo TA, Joshi VA, et al. Germline gain-of-function mutations in *SOS1* cause Noonan syndrome. *Nat Genet*. 2007;39:70–4.
- Carta C, Pantaleoni F, Bocchinfuso G, Stella L, Vasta I, Sarkozy A, et al. Germline missense mutations affecting *KRAS* isoform B are associated with a severe Noonan syndrome phenotype. *Am J Hum Genet*. 2006;79:129–35.
- Nyström AM, Ekvall S, Berglund E, Björkqvist M, Braathen G, Duchon K. Noonan and cardio-facio-cutaneous syndromes: two clinically and genetically overlapping disorders. *J Med Genet*. 2008;45:500–6.
- Cirstea IC, Kutsche K, Dvorsky R, Gremer L, Carta C, Horn D, et al. A restricted spectrum of *NRAS* mutations causes Noonan syndrome. *Nat Genet*. 2010;42:27–9.
- Cordeddu V, Di Schiavi E, Pennacchio LA, Ma'ayan A, Sarkozy A, Fodale V, et al. Mutation of *SHOC2* promotes aberrant protein N-myristoylation and causes Noonan-like syndrome with loose anagen hair. *Nat Genet*. 2009;41:1022–6.
- Koudova M, Seemanova E, Zenker M. Novel *BRAF* mutation in a patient with LEOPARD syndrome and normal intelligence. *Eur J Med Genet*. 2009;52:337–40.
- Aoki Y, Niihori T, Narumi Y, Kure S, Matsubara Y. The RAS/MAPK syndromes: novel roles of the RAS pathway in human genetic disorders. *Hum Mutat*. 2008;29:992–1006.
- Digilio MC, Sarkozy A, De Zorzi A, Pacileo G, Limongelli G, Mingarelli R, et al. LEOPARD syndrome: clinical diagnosis in the first year of life. *Am J Med Genet*. 2006;140:740–6.
- Sarkozy A, Schirinzì A, Lepri F, Bottillo I, De Luca A, Pizzuti A, et al. Clinical lumping and molecular splitting of LEOPARD and NF1/NF1-Noonan syndromes. *Am J Med Genet A*. 2007;143A:1009–11.
- Sutton MJ, Tajik AJ, Giuliani ER, Gordon H, Daniel WF. Hypertrophic obstructive cardiomyopathy and lentiginos: a little known neuroectodermal syndrome. *Am J Cardiol*. 1981;47:214–7.
- Woywodt A, Welzel J, Haase H, Duerholz A, Wiegand U, Potratz J, et al. Cardiomyopathic lentiginos/LEOPARD syndrome presenting as sudden cardiac arrest. *Chest*. 1998;113:1415–7.

33. Limongelli G, Pacileo G, Marino B, Digilio MC, Sarkozy A, Elliott P, et al. Prevalence and clinical significance of cardiovascular abnormalities in patients with the LEOPARD syndrome. *Am J Cardiol.* 2007;100:736-41.
34. De Luca A, Bottillo I, Sarkozy A, Carta C, Neri C, Bellacchio A, et al. *NF1* gene mutations represent the major molecular event underlying neurofibromatosis-Noonan syndrome. *Am J Hum Genet.* 2005;77:1092-101.
35. Carcavilla A, Pinto I, Muñoz-Pacheco R, Barrio R, Martín-Frías M, Ezquieta B. LEOPARD syndrome (*PTPN11*, T468M) in three boys fulfilling neurofibromatosis type 1 clinical criteria. *Eur J Pediatr.* 2011;170:1069-74.
36. Rodríguez-Bujaldón A, Vázquez-Bayo C, Jiménez-Puya R, Galán-Gutiérrez M, Moreno-Giménez J, Rodríguez-García A, et al. LEOPARD syndrome: what are café noir spots? *Pediatr Dermatol.* 2008;25:444-8.