

Left Ventricular Dysfunction Induced by Monomorphic Ventricular Arrhythmias: Large Improvement in Ventricular Function After Radiofrequency Ablation of the Arrhythmic Source

Juan C. Fernández-Guerrero, Luis Tercedor, Miguel Álvarez, José M. Lozano, Mercedes González-Molina and José Azpitarte

Servicio de Cardiología, Hospital Universitario Virgen de las Nieves, Granada, Spain.

Left ventricular systolic dysfunction related to ventricular arrhythmias is a relatively poorly understood entity. To increase our knowledge base, we describe 5 patients in whom the link between ventricular dysfunction and ventricular arrhythmia was unequivocally established. All patients had repetitive monomorphic ventricular arrhythmias and left ventricular systolic dysfunction (ejection fraction $\leq 40\%$ and end-diastolic size ≥ 55 mm). The arrhythmogenic source was identified by electrophysiological study (right ventricle in 2 patients, left ventricle in 2, and left sinus of Valsalva in one), and was eliminated in all patients by radiofrequency catheter ablation. At 7 ± 2 months post-ablation, large improvements were seen in left ventricular function and remodeling (ejection fraction $\geq 50\%$ and end-diastolic size ≤ 51 mm in all cases), with no recurrence of arrhythmia during follow-up (10-69 months). This finding confirms that recurring ventricular arrhythmias can induce left ventricular dysfunction which may be reversible after ablation.

Key words: Tachycardia. Catheter ablation. Heart failure. Cardiomyopathy.

Disfunción ventricular izquierda inducida por arritmias ventriculares monomórficas: gran mejoría de la función ventricular tras ablación con radiofrecuencia del foco arrítmico

La disfunción ventricular izquierda ocasionada por arritmias ventriculares es una entidad poco conocida. Para contribuir a su difusión presentamos los casos de 5 pacientes en los que se pudo establecer de forma inequívoca la conexión arritmia-disfunción ventricular. Todos tenían arritmias ventriculares monomórficas repetitivas y disfunción ventricular izquierda (fracción de eyección $\leq 40\%$ y dimensión telediastólica ≥ 55 mm). En el estudio electrofisiológico se detectó un foco arritmogénico intraventricular localizado en el ventrículo derecho en 2 casos, en el ventrículo izquierdo en otros 2 y en el seno de Valsalva izquierdo en el quinto; en todos fue suprimido mediante ablación con catéter. A los 7 ± 2 meses postablación se observó una gran mejoría de la función sistólica y el remodelado ventricular izquierdo (fracción de eyección $\geq 50\%$ y dimensión telediastólica ≤ 51 mm en los 5 enfermos), sin recurrencia de la arritmia durante el seguimiento (10-69 meses). Estos hallazgos confirman que las arritmias ventriculares repetitivas pueden causar disfunción ventricular, reversible tras ablación con radiofrecuencia.

Palabras clave: Taquicardia. Ablación con catéter. Insuficiencia cardíaca. Miocardiopatía.

INTRODUCTION

Left ventricular systolic dysfunction as a cause of arrhythmia is a well-recognized clinical entity that was initially reported in association with incessant supraventricular tachycardia in children and adolescents,¹ and later with atrial fibrillation.² Less commonly

known is the fact that ventricular arrhythmia can induce ventricular dysfunction.³⁻¹¹ In this article we describe 5 clinical cases of repetitive monomorphic ventricular arrhythmia in patients with no structural heart disease, except for left ventricular systolic dysfunction. Ventricular function improved considerably after radiofrequency ablation was performed.

PATIENTS AND METHODS

Between November 1997 and November 2003 in our unit, 37 patients with ventricular tachycardia and no known underlying pathology were studied. Five of these patients, whose main characteristics are shown in the

Correspondence: Dr. L. Tercedor Sánchez.
Servicio de Cardiología. Hospital Universitario Virgen de las Nieves.
Avda. de las Fuerzas Armadas, 2. 18014 Granada. España.
E-mail: luis.tercedor.sspa@juntadeandalucia.es

Received May 18, 2004.
Accepted for publication September 8, 2004.

Figure 1. Panoramic view of electrocardiographic monitoring of Patient 2 in the left panel. Constant ventricular bigeminy and a run of ventricular tachycardia are evident. The enlarged tachycardia tracing (A) shows that the complexes have the same morphology as the bigeminal beats. The right panel (B) shows the morphology of the premature beats in the 12-lead ECG.

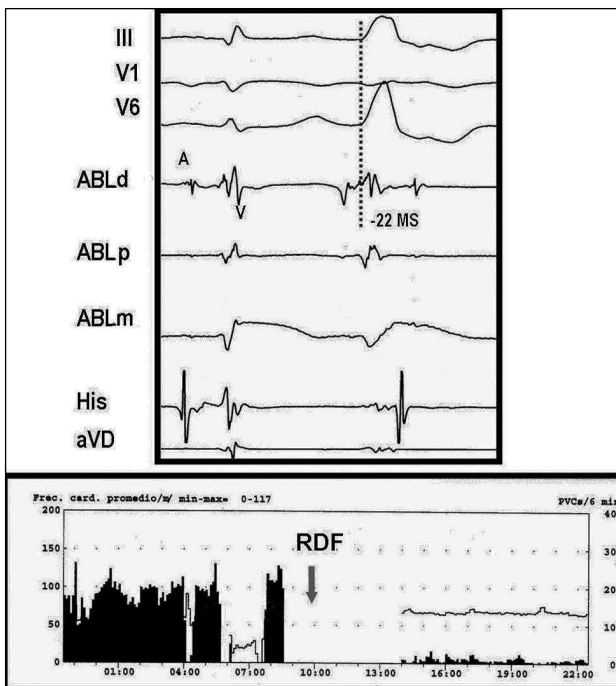
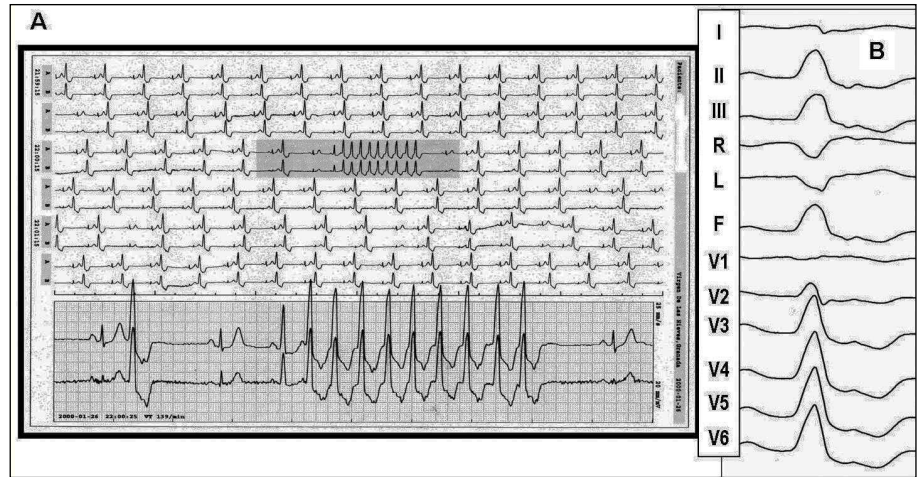


Figure 2. Tracing of the same patient as in Figure 1. The upper panel shows the intra-atrial electrograms of a premature ventricular beat recorded at the point of successful ablation in the left ventricular outflow tract. In the bipolar electrode (ABLd), early activation (-22 ms) with respect to the QRS pattern of the surface leads is apparent; in the monopolar electrode (ABLm) a QS pattern can be seen. The lower panel shows suppression of the premature beats after radiofrequency ablation.

Table, had left ventricular systolic dysfunction. The clinical diagnosis was dilated cardiomyopathy in 4 cases and myocarditis in 1. The ventricular arrhythmia consisted of high-density ventricular ectopic activity associated with runs of repetitive nonsustained ventricular tachycardia in 4 cases (Figure 1). Ablation was indicated on the basis of palpitations in four patients, and was further supported in one of them (Case 1) by the fact that the patient's ventricular function showed evidence

of deterioration 11 months after the arrhythmia was detected. In Case 4 there were no palpitations and ablation was performed for suspected tachycardia-induced cardiomyopathy, based on our previous experience. In all cases coronary disease was excluded by angiography.

After the diagnostic electrophysiological study, activation mapping was performed starting with the right ventricle in all patients except Case 5. In this patient the initial approach in the left ventricle suggested by the electrocardiographic pattern (RS in V2), was ineffective; hence an irrigated catheter was successfully inserted in the proximity of the tricuspid ring.

After ablation, M-mode echocardiography was used to measure the dimensions of the left ventricle, and the ejection fraction was calculated with the Teichholz formula. Follow-up echocardiography was performed 7 ± 2 months later. Long-term follow-up (4-69 months) included Holter monitoring in addition to the usual examinations.

RESULTS

Ablation with a mean of 5.4 radiofrequency applications (range, 2-10) was performed without complications (Figure 2). No recurrence of the primitive ventricular arrhythmia was detected during follow-up. In 2 cases isolated ventricular premature beats with a different morphology were detected. All patients were asymptomatic at the most recent follow-up visit and were not receiving medication, except for 2 patients who were taking antihypertensive drugs. Post-ablation echocardiography showed an evident increase in the ejection fraction and a decrease in the left-ventricular end-systolic dimension in all 5 cases (Figure 3).

DISCUSSION

The main interest of the cases presented resides in the fact that ventricular dysfunction induced by ventri-

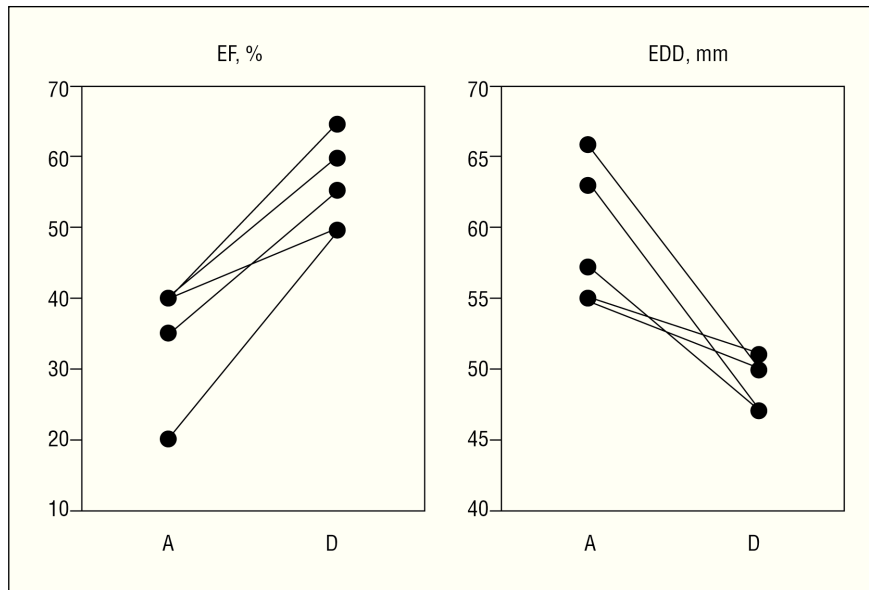


Figure 3. The left ventricular ejection fraction (EF) increased dramatically in all patients after suppressing the arrhythmia, and the end-diastolic dimension (EDD) decreased, indicating favorable ventricular remodeling. Baseline data (left in both panels) were obtained within the first 48 hours post-ablation. Data on the right were obtained several months after.

cular arrhythmia substantially improved with abolition of the arrhythmogenic source. All the previous publications on this subject are individual case reports, with the exception of the study by Grimm et al,¹⁰ which included four patients. The first of the case reports was published in 1989 and the treatment consisted of anti-tachycardia pacemaker placement.³ In the remaining cases, radiofrequency ablation resolved the repetitive tachycardia^{4,5,7,10} or the frequent ventricular premature beats^{8,11} originating in the right ventricular outflow tract, except in 2 cases.^{6,9} The patients in our series had nonsustained monomorphic arrhythmia, but with a repetitive, incessant character. The location of the source

varied, but did not impede successful ablation in all 5 cases.

It is more difficult to establish suspicion of this entity than when dealing with tachycardia-induced cardiomyopathy due to supraventricular arrhythmia. With the weight of convention, it is logical that concurrent ventricular systolic dysfunction and arrhythmia would be interpreted as a result of dilated cardiomyopathy. Therefore, it is necessary to wait until ventricular function improves after abolishing the arrhythmia to establish the definitive diagnosis. This condition may be more frequent than has been suspected up to now. In one study, in 12 of 14 patients with dilated cardiomyopathy

TABLE. Profile of Demographic, Clinical and Arrhythmia Factors in the 5 Patients*

	Case 1	Case 2	Case 3	Case 4	Case 5
Age, years	49	71	21	59	47
Sex	M	M	M	F	M
Addiction	Alcohol	-	Cocaine	-	-
NYHA class	II	II	I	III	I
Palpitations	Yes	No	Yes	No	Yes
Left ventricular EDD, mm	63	55	57	66	55
Left ventricular EF, %	40	40	35	20	40
Evolution time of LVSD, months	27	2/3	2	30	108
Evolution time of arrhythmia, months	108	2/3	13	30	108
Ventricular complexes in 24 h, %	57	53	69	40	47
Morphology of ventricular complexes	Complete LBBB, inferior axis	Complete RBBB, inferior axis	Complete LBBB, inferior axis	Complete LBBB, inferior axis	Complete LBBB, superior axis
Repetitive VT	Yes	Yes	Yes	No	Yes
Mean 24-h HR, bpm	89	68	78	100	83
Atrioventricular conduction	No	No	Yes	Yes	No
Location of arrhythmic focus	RVot	LVot	Left sinus of Valsalva	LVot	Paraseptal RV base

*RBBB indicates right bundle branch block; LBBB, left bundle branch block; LVSD, left ventricular systolic dysfunction; EDD, end-diastolic dimension; HR, heart rate; EF, ejection fraction; NYHA, New York Heart Association; VT, ventricular tachycardia; RVot, right ventricular outflow tract; LVot, left ventricular outflow tract; RV, right ventricle.

yopathy and frequent premature beats, considerable improvement in left ventricular function was observed in 4 of the 5 patients who experienced a notable drug-induced decrease in ventricular ectopic activity. This suggests that some patients diagnosed with ventricular arrhythmia secondary to dilated cardiomyopathy may actually have had the opposite problem: primitive ventricular arrhythmia—frequent premature beats in this case—able to induce ventricular dysfunction in a healthy heart.

With regard to the causative mechanism, we cannot invoke tachycardia as the determinant pathogenic factor in our patients, since the mean 24-hour heart rate was only slightly elevated. Thus, we must look to other mechanisms to explain the ventricular dysfunction. One such factor, atrioventricular asynchrony, can reduce the atrial contribution to ventricular filling and produce an increase in pressure through the baroreceptors that could trigger neurohumoral mechanisms typical of heart failure. Anomalous ventricular activation, common in ventricular ectopy, makes diastolic mitral regurgitation, and mechanical asynchrony (both inter-ventricular and intraventricular) possible during contraction. The mechanism we propose for our cases is that an intraventricular conduction disturbance together with atrioventricular asynchrony and mild tachycardia led to the development of left ventricular dysfunction.

CLINICAL IMPLICATIONS

In the guidelines of the Spanish Society of Cardiology,¹³ the indication for ablation in monomorphic ventricular premature beats is considered exceptional. The recommendation for ablation in repetitive ventricular tachycardia is contemplated in patients with symptoms and those who fail to respond to or cannot tolerate drug therapy; tachycardia-induced cardiomyopathy is not mentioned. Considering that ablation in these tachycardia patients has a success rate of nearly 80% and a complication rate similar to that of other more common origins,¹⁴ the indication for this procedure should be assessed when there is frequent monomorphic ventricular arrhythmia (premature beats, whether isolated or associated with repetitive tachycardia) together with apparently idiopathic left-ventricular dysfunction.

REFERENCES

1. Shinbane JS, Wood MA, Jensen DN, Ellenbogen KA, Fitzpatrick AP, Scheinman MM. Tachycardia-induced cardiomyopathy: a review of animal models and clinical studies. *J Am Coll Cardiol*. 1997;29:709-15.
2. Azpitarte J, Baun O, Moreno E, García-Orta R, Sánchez-Ramos J, Tercedor L. In patients with chronic atrial fibrillation and left ventricular systolic dysfunction, restoration of sinus rhythm confers substantial benefit. *Chest*. 2001;120:132-8.
3. Rakovec P, Lajovic J, Dolenc M. Reversible congestive cardiomyopathy due to chronic ventricular tachycardia. *Pacing Clin Electrophysiol*. 1989;12:542-5.
4. Kim YH, Goldberger J, Kadish A. Treatment of ventricular tachycardia-induced cardiomyopathy by transcatheter radiofrequency ablation. *Heart*. 1996;76:550-2.
5. Jaggarao NS, Nanda AS, Daubert JP. Ventricular tachycardia induced cardiomyopathy: improvement with radiofrequency ablation. *Pacing Clin Electrophysiol*. 1996;19:505-8.
6. Singh B, Kaul U, Talwar KK, Wasir HS. Reversibility of "tachycardia induced cardiomyopathy" following the cure of idiopathic left ventricular tachycardia using radiofrequency energy. *Pacing Clin Electrophysiol*. 1996;19:1391-2.
7. Vijgen J, Hill P, Biblo LA, Carlson MD. Tachycardia-induced cardiomyopathy secondary to right ventricular outflow tract ventricular tachycardia: improvement of left ventricular systolic function after radiofrequency catheter ablation of the arrhythmia. *J Cardiovasc Electrophysiol*. 1997;8:445-50.
8. Chugh SS, Shen WK, Luria DM, Smith HC. First evidence of premature ventricular complex-induced cardiomyopathy: a potentially reversible cause of heart failure. *J Cardiovasc Electrophysiol*. 2000;11:328-9.
9. Benito Bartolomé F, Sánchez Fernández-Bernal C. Reversibilidad de la miocardiopatía tras curación de la taquicardia ventricular incesante mediante ablación con radiofrecuencia en el lactante. *An Esp Pediatr*. 2000;53:156-8.
10. Grimm W, Menz V, Hoffmann J, Maisch B. Reversal of tachycardia induced cardiomyopathy following ablation of repetitive monomorphic right ventricular outflow tract tachycardia. *Pacing Clin Electrophysiol*. 2001;24:166-71.
11. Shiraishi H, Ishibashi K, Urao N, Tsukamoto M, Hyogo M, Keira N, et al. A case of cardiomyopathy induced by premature ventricular complexes. *Circ J*. 2002;66:1065-7.
12. Duffee DF, Shen WK, Smith HC. Suppression of frequent premature ventricular contractions and improvement of left ventricular function in patients with presumed idiopathic dilated cardiomyopathy. *Mayo Clin Proc*. 1998;73:430-3.
13. Almendral Garrote J, Marín Huerta E, Medina Moreno O, Peinado Peinado R, Pérez Álvarez L, Ruiz Granell R, et al. Guías de práctica clínica de la Sociedad Española de Cardiología en arritmias cardíacas. *Rev Esp Cardiol*. 2001;54:307-67.
14. Rodríguez Font E, Álvarez López M. Registro español de ablación con catéter. II. Informe oficial de la Sección de Electrofisiología y Arritmias de la Sociedad Española de Cardiología (2002). *Rev Esp Cardiol*. 2003;56:1093-104.