

## Left Atrial Reduction. A New Concept in Surgery for Chronic Atrial Fibrillation

Ovidio A. García-Villarreal<sup>a</sup>, Amadeu B. Gouveia<sup>a</sup>, Roberto González<sup>b</sup> and Rubén Argüero<sup>c</sup>

Departamentos de <sup>a</sup>Cirugía Cardiorrástica y <sup>b</sup>Anestesiología. Hospital Regional N.º 34, IMSS. Monterrey. Nuevo León. México. <sup>c</sup>Departamento de Cirugía Cardíaca. Hospital de Cardiología. Centro Médico Nacional Siglo XXI, IMSS. México DF. México.

**Introduction and objectives.** Mitral valve disease often is accompanied by chronic atrial fibrillation, especially when the left atrium is enlarged. Mitral valve surgery alone cannot resolve the arrhythmia in most cases. Several surgical techniques have been proposed. We have used surgical left atrial reduction and pulmonary vein isolation to eliminate chronic atrial fibrillation associated with mitral valve disease. The aim of this paper is to report our experience with this new surgical concept.

**Patients and method.** Twenty-three patients (18 women and 5 men, mean age  $44.1 \pm 14.7$  years) with mitral valve disease and chronic atrial fibrillation for more than 3 months underwent surgery. Mitral valvuloplasty was performed in 11 cases, and mitral valve replacement in 12. Left atrial reduction was used to eliminate chronic atrial fibrillation in all cases.

**Results.** There was no operative mortality. Three patients (13%) had recurrent atrial fibrillation between postoperative days 6 and 8. No atrioventricular conduction disturbances were observed. An important reduction in left atrial size was evident on echocardiography ( $4.8 \pm 0.77$  vs.  $8.1 \pm 1.47$  cm,  $p < 0.01$ ). In 3 to 36 months of follow-up ( $13.9 \pm 11$  months), all patients preserved sinus rhythm.

**Conclusions.** Left atrial reduction seems to be an effective and easily applied alternative method for treating mitral valve disease with chronic atrial fibrillation.

### Reducción auricular izquierda. Un nuevo concepto en la cirugía para la fibrilación auricular crónica

**Introducción y objetivos.** La enfermedad valvular mitral se acompaña de fibrilación auricular crónica, especialmente cuando la aurícula izquierda está aumentada de tamaño. La cirugía valvular mitral no es suficiente por sí misma para la eliminación de esta arritmia en la gran mayoría de los casos y se han propuesto diversas técnicas quirúrgicas. Nosotros hemos empleado la reducción auricular izquierda y el aislamiento de las venas pulmonares como tratamiento quirúrgico para la eliminación de la fibrilación auricular crónica coexistente con enfermedad valvular mitral. El objetivo de este estudio es publicar nuestra experiencia en la aplicación de este nuevo concepto quirúrgico.

**Pacientes y método.** Se intervino quirúrgicamente a 23 pacientes que presentaban enfermedad valvular mitral y fibrilación auricular crónica de más de 3 meses de evolución. Se trataba de 18 mujeres y 5 varones, con una edad media de  $44,1 \pm 14,7$  años. Se realizó valvuloplastia mitral en 11 casos, y un reemplazo protésico mitral en 12. La reducción auricular izquierda y el aislamiento de las venas pulmonares fueron utilizados para la eliminación de la fibrilación auricular crónica en todos los casos.

**Resultados.** No hubo mortalidad operatoria. Tres casos (13%) tuvieron recidiva de fibrilación auricular, que revirtió a los 6 y 8 días postoperatorios. No se observaron problemas en la conducción atrioventricular. Se apreció una importante reducción en el tamaño de la aurícula izquierda mediante ecocardiografía ( $4,8 \pm 0,77$  frente a  $8,1 \pm 1,47$  cm;  $p < 0,01$ ). Tras un seguimiento de 3-36 meses ( $13,9 \pm 11$  meses) todos los pacientes permanecen en ritmo sinusal.

**Conclusiones.** La reducción auricular izquierda parece ser un método alternativo eficaz y de fácil aplicación en los casos de enfermedad valvular mitral que presentan fibrilación auricular crónica.

**Key words:** Atrial fibrillation. Arrhythmia. Surgery. Mitral valve. Atrium.

Full English text available at: [www.revespcardiol.org](http://www.revespcardiol.org)

**Palabras clave:** Fibrilación auricular. Arritmia. Cirugía. Válvula mitral. Aurícula.

Correspondence: Dr. O.A. García-Villarreal.  
Vista Florida 460, Col. Linda Vista, 67130; Guadalupe,  
Nuevo León, México.  
E-mail: ovidio@voila.fr

Received 9 March 2001.  
Accepted for publication 24 January 2002.

## ABBREVIATIONS

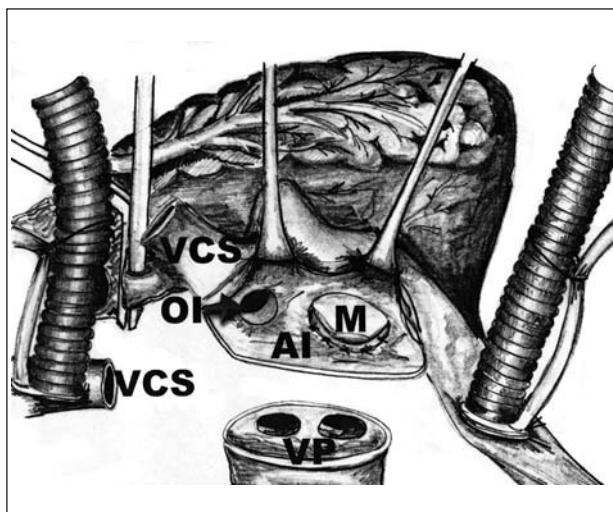
LA: left atrium  
 AF: atrial fibrillation.  
 LAP: left appendage  
 SVC: superior vena cava  
 PV: pulmonary veins

## INTRODUCTION

Chronic atrial fibrillation (AF) is frequently associated with mitral valve disease, especially when the left atrium (LA) is enlarged. Mitral surgery *per se* does not suffice to eliminate AF in the majority of cases. Although various techniques have been described for the elimination of chronic AF,<sup>1-6</sup> most of them are laborious and require prolonged surgery. Sankar et al<sup>7</sup> have described left atrial reduction as a surgical treatment for chronic AF. This technique consists of isolation of the pulmonary veins (PV) and the excision of a circumferential band of tissue of the LA, including the base of the left appendage (LAp). The result obtained is the isolation of probable macroreentrant circuits of AF in the LA, as well as an important reduction in atrial size. Nevertheless, it should be noted that the fundamental part of this surgical technique is the isolation of the PV. We have used this technique in 23 cases with excellent results, achieving a complete remission of chronic AF in all the patients.

## PATIENTS AND METHOD

Between August 1998 and June 2001, 23 patients, 18 women and 5 men, underwent surgery. The mean age of patients was  $44.9 \pm 15.2$  years (standard deviation) at the time of surgery. A total of 18 patients (78%) had double mitral lesion and 5 (22%) had mitral insufficiency. The etiology was rheumatic in 18 cases (78%), degenerative in 4 patients (17%), and congenital in one (5%). A total of 18 patients (78%) were functional class II of the New York Heart Association (NYHA) and 5 (22%) were functional class III. All the patients had an AF of more than 3 months of evolution. The duration of AF was  $3.9 \pm 2.9$  years (range, 1-14 years). The echocardiographic data obtained in each patient were the superoinferior and cross-sectional diameters in the 4-chamber apical axis view, and the anteroposterior diameter in the parasternal axis view. The echocardiographic studies were made in each patient preoperatively, transoperatively, and at 1 month and 6 months after surgery. The LA transport function was studied by



**Fig. 1.** This schematic illustration shows the first incision in the LA, which totally surrounds the cap of the PV.

transmitral flow echo-Doppler in which the reappearance of the «a» wave of atrial contraction was measured. In all the patients, the atrial «a» wave was absent in the Doppler transmitral flow study in before surgery. All the patients were taking one or more antiarrhythmic drugs ( $1.7 \pm 0.9$ ; range, 1-4). Pharmacological antiarrhythmia treatment was maintained until the third postoperative month. All patients received anticoagulant treatment before surgery. Oral anticoagulant treatment was used for 6 weeks after surgery; then it was discontinued in the patients who had undergone mitral plasty or implantation of a biological mitral prosthesis and exhibited sinus rhythm and an «a» wave in the echo-Doppler study of transmitral flow. Mitral valve surgery and left atrial reduction were performed in all patients.

## Statistical analysis

Values are expressed as percentages and the mean and standard deviation. Pre and postoperative LA values were compared with the Student *t* test for quantitative variables. A difference was considered statistically significant if  $P < .01$ .

## Surgical technique

Surgery was performed using medial sternotomy. The ascending aorta and vena cava were cannulated as usual. An angled cannula was placed in the superior vena cava (SVC), near its union with the vena anonymae and the right brachycephalic venous trunk, and cardiopulmonary bypass was begun. Once the aortic root was clamped, continuous retrograde cardioplegia was maintained with warm, high-

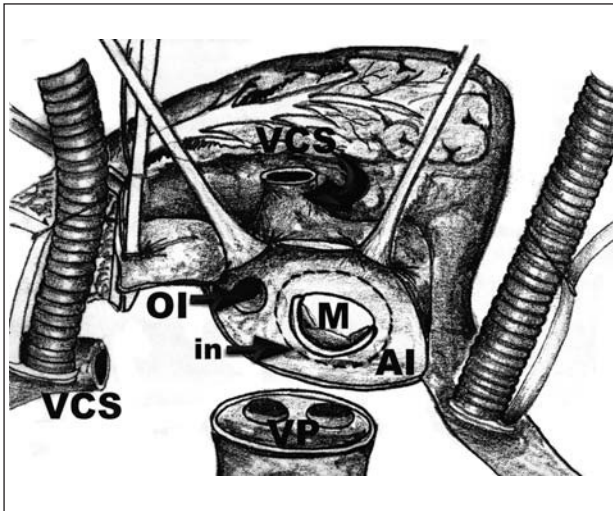


Fig. 2. In this figure the arrow indicates the line of dashes that represents the second incision in the LA.

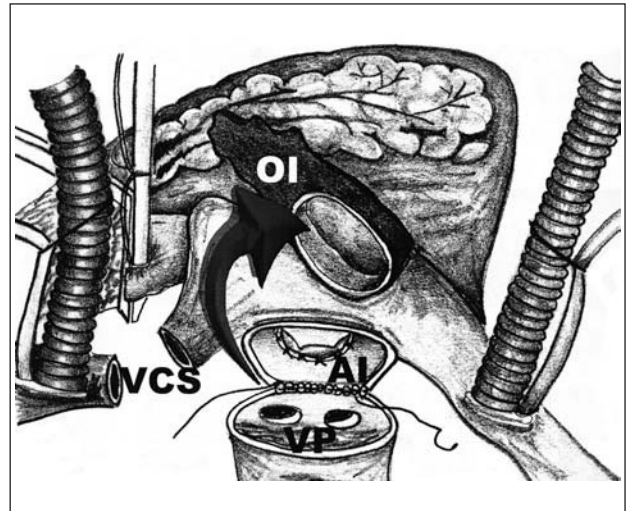


Fig. 3. Once both surgical incisions are made, a circumferential band of left atrial tissue is obtained with the LAP included (which is indicated by the arrow). The final step in this surgical technique is reanastomosis of the LA.

potassium solution infused through the coronary sinus. The SVC was completely sectioned about 3 cm above its opening on the right atrium to expose the roof of the LA. Two incisions were made in the LA. The first was made conventionally, parallel to the interatrial sulcus, and extended around the PV. The LA was sectioned completely (Figure 1). The second incision was made 1 to 3 cm inward, toward the mitral valve, and surrounded the LA (Figure 2). A circumferential band of LA tissue with the base of the LAP was obtained. Mitral valvuloplasty was performed in 11 cases (47.8%) and mitral valve replacement in 12 (52.2%). An anastomosis was made between the LA and SVC with continuous sutures of polypropylene 3-0 and 5-0, respectively (Figure 3). The cardiopulmonary bypass and aortic clamping times were  $156.6 \pm 24.4$  min and  $98.6 \pm 13.2$  min, respectively.

**RESULTS**

There was no operative mortality. Three patients (3/23; 13%) presented a recurrence of AF in the first hours after surgery, which was converted with medicational therapy between the sixth and eighth postoperative days. No patient was reintervened for bleeding. No problems in atrioventricular conduction were observed in any case. All patients were extubated in the first 12 h after surgery. The stay in the postoperative intensive care unit was  $1.7 \pm 0.5$  days, and the postoperative intrahospital stay was  $6.8 \pm 0.8$  days. An intraoperative echocardiographic study was made one and six months after surgery to evaluate the size of the LA, as well as the recovery of the atrial «a» wave. An important reduction was observed in the superoinferior diameter of the LA by

echocardiography after surgery ( $4.8 \pm 0.77$  versus  $8.1 \pm 1.47$  cm;  $P < .01$ ). Also the reappearance of the atrial «a» wave was demonstrated in the echo-Doppler transmitral flow study in 20 of the 23 patients operated

TABLE 1. LA values in the superoinferior diameter (by echocardiography)

Case	Preoperative (cm)	Postoperative (cm)	Postoperative atrial «a» wave
1	8.3	4.3	Yes
2	11	7	Yes
3	6	4.5	Yes
4	7	4.5	Yes
5	6.4	4.5	Yes
6	7.3	3.8	Yes
7	8.9	4.3	Yes
8	9.7	4.7	Yes
9	8.3	4.5	Yes
10	7.8	4	Yes
11	9.1	4.8	Yes
12	7	4.5	Yes
13	8.9	4.8	Yes
14	10.5	6.4	No
15	11	6	Yes
16	8.3	5.4	Yes
17	7.2	5.2	No
18	8.3	5.2	Yes
19	8.5	4.8	Yes
20	9.7	5.4	No
21	6.4	4.3	Yes
22	7.4	4.5	Yes
23	6.3	4.1	Yes
Mean and standard deviation	$8.1 \pm 1.47^*$	$4.8 \pm 0.77^*$	-

\* $P < .01$ .

(87%) (Table 1). In a follow-up of 3 to 36 months (13.9±11 months) after surgery, 22 patients (96%) were functional class I of the NYHA, and one (4%) was class II; in addition, all the patients maintained sinus rhythm. In all the patients antiarrhythmic treatment was eliminated after the third postoperative month. In the 23 patients who underwent surgery, oral anticoagulant treatment was discontinued suppressed in all cases in which mitral valvuloplasty was performed or a biological mitral prosthesis was implanted (14/23; 61%).

## DISCUSSION

Chronic AF usually accompanies mitral valve disease at the time of surgery, especially when the LA is enlarged, which is the main determinant factor in the appearance and maintenance of chronic AF.<sup>8,9</sup> LA size in excess of 45 mm is one of the independent predictive factors for the appearance and recurrence of AF. AF is rare in LA with a diameter of less than 40 mm.<sup>10</sup> The ability of LA to fibrillate is determined by the relation between the effective refractory period of the atrial myocardium and the atrial area available for the development of a macroreentrant circuit.<sup>11</sup> That is to say that a critical mass or critical area of atrial muscle is needed for the appearance of AF. It thus seems logical that a strategic part of surgery to eliminate AF must include the reduction in size of the LA.<sup>12</sup>

Several procedures have been described to eliminate chronic AF, from those designed to control ventricular response with digitalis,<sup>13</sup> ablation of the His bundle followed by implantation of a ventricular pacemaker surgically<sup>14</sup> or by transvenous catheter,<sup>15</sup> LA isolation,<sup>5</sup> the surgical corridor procedure,<sup>4</sup> and the Cox maze procedure with its modifications.<sup>1,2,6,16-18</sup>

The procedure described by Cox<sup>1</sup> has achieved successful results. Although a success rate of 98% has been reported with this procedure, it involves many surgical incisions in both atria, particularly in the posterior plane of the LA, and is technically demanding and has a high risk of lethal bleeding complications. At the same time, this technique involves the use of the cryoablation of two points of the coronary sinus, which restricts its use to hospital centers equipped with this technology. Hioki et al<sup>6</sup> have modified the Cox maze procedure in an attempt to simplify it with an incision between the right and left PV, instead of around them. Nevertheless, the percentage of recurrences of AF could be very high because complete isolation of the PV from the rest of the LA is not achieved, thus allowing the development of macroreentrant circuits from the PV. The deliberate use of cryolesion to eliminate surgical incisions<sup>16</sup> has not been shown to be sufficiently effective, since 51.8% of patients required antiarrhythmic drugs for

recurrent AF after surgery. The corridor procedure<sup>19</sup> has the drawback of only controlling the frequency of the atrioventricular electrical impulse, but the rest of the atrial tissue continues to fibrillate, thus losing the atrial transport function. In addition, the risk of thromboembolism is not eliminated and the use of permanent oral anticoagulation is required.<sup>4</sup> Sankar et al<sup>7</sup> have performed 6 left atrial reduction procedures to eliminate chronic AF concomitant with mitral valve surgery, with a success rate of 100%.

We have taken the model from Sankar et al<sup>7</sup> for the elimination of the associated chronic AF to mitral valve disease in 23 patients, with a success rate of 100%. We have found this technique to be extremely satisfactory because it manages several circumstances simultaneously: *a*) reduction of LA size as a crucial part of the procedure, eliminating mass that is critical for AF; *b*) the isolation of the PV along with amputation of the LAp, thus eliminating 3 of the 6 main macroreentrant circuits for the origin of AF (two in the PV and one in the base of the LAp; *c*) amputation of LAp suppresses the most important source of LA embolisms, since it has been demonstrated that 57% of rheumatic patients with AF have thrombi in the LAp that extend to the LA, and 9% of the cases of non-rheumatic AF present an isolated thrombus or a thrombus originating in the LAp.<sup>20</sup> In addition, since the LAp has a narrow base, defined and with a hollow body located peripherally to the main blood flow in the LA, it is logical to think that the excision of this appendage reduces the subsequent threat intracavitary thrombus formation in the LA; nonetheless, if the fact that in patients treated with warfarin approximately 50% of embolic events occur in individuals that had an inadvertent therapeutic lapse or required the partial or permanent discontinuation of therapy with oral anticoagulants is considered, and that most of these thrombi originated in the LAp,<sup>21</sup> it is imperative to amputate this anatomical structure during this type of procedures, and *d*) the excellent exposure of the mitral valve, which is essential when one of the goals is to reconstruct the valve, associated with the cure of AF.

Isolation of the PV is a fundamental part of surgery for the elimination of AF. Hasegüerre et al have demonstrated that the most frequent origin of ectopic electrical impulses that originate macroreentrant circuits of AF are the PV in up to 96% of cases,<sup>22-25</sup> above all in superior PV.<sup>23</sup> In fact, there is a direct relation between enlargement of the superior PV and the appearance of AF, as well as with muscular rings derived from the LA myocardium that penetrates to a variable degree the ostium and the most proximal portion of the superior PV. Structural changes in these portions of the atrial myocardium that invade the PV, perhaps due to its distention, can originate the chaotic rhythm that triggers AF.<sup>26</sup> This can also be due to the

fact that the duration of the refractory period inside these PV is very short and can as high-frequency sites of activation due to reentrant activation with small waves.<sup>27</sup> This has motivated ablation strategies by applying radiofrequency directly to the ectopic foci in the PV, with a success rate of up to 69% in a follow-up of 8±4 months.<sup>26,28</sup> Nevertheless, these techniques have the drawback of high rates of recurrence of AF due to the subsequent appearance of new arrhythmogenic foci in the same PV. Therapy must include linear incisions by application of radiofrequency or surgery to reduce atrial tissue and prevent the reentrant waves in the required number.<sup>29,30</sup>

Another important aspect is the depth and uniformity of tissue ablation by radiofrequency, since small residual isthmuses of atrial tissue could remain uninjured by the radiofrequency, allowing the conduction of chaotic electrical impulses from the PV to inside the LA, with the reappearance of AF. This has been observed in tissue isthmuses of 0.8 mm or more.<sup>31</sup> The discontinuity in the ablation lines used in radiofrequency can be a proarrhythmic factor. It is obvious that isolation of the PV by complete continuous surgical incisions offers the maximum guarantees for completely isolating the PV.

We have used the last premise to surgically isolate the chamber containing the 4 PV, with only 3 cases (13%) of recurrence of AF that responded to pharmacological therapy in the first 8 postoperative days. The rest of the patients recovered normal sinus rhythm from the moment in which the aorta was unclamped. Currently, All of the 23 patients have sinus rhythm without antiarrhythmic medications.

The echocardiographic study made in this series of patients demonstrated an important reduction in LA size in the superoinferior diameter of the LA, since this diameter is more directly affected by this type of surgical technique, in comparison with the anteroposterior and transversal diameters. In addition, the reappearance of the atrial «a» wave was observed in most of the cases (20/23), indicating the restoration of LA transport function.

Likewise, we found that this technique can be easily applied when the superoinferior diameter of the LA (by echocardiography) is more than 7 cm, given the distance between the plane of the PV and the coronary sinus, which is the guideline to follow to obtain the size of the LA reduction.<sup>12</sup>

## CONCLUSIONS

The technique of left atrial reduction proposed here is a safe surgical technique that is easily performed, can be implemented in every patient meeting the following conditions: *a)* to have undergone mitral valve surgery; *b)* have a LA superoinferior diameter of more than 7 cm (by echocardiography), and *c)* AF for

more than 3 months before surgery.<sup>32,33</sup>

Moreover, if the associated mitral procedure of choice is valvuloplasty or the implantation of a mitral biological prosthesis, it will be possible to achieve the endpoint: to maintain the patient free of anticoagulant use.<sup>34,35</sup>

## ACKNOWLEDGEMENTS

We thank Mrs. María del Carmen Colomer for her expert help in writing this document.

## REFERENCES

1. Cox JL. The surgical treatment of atrial fibrillation. IV. Surgical technique. *J Thorac Cardiovasc Surg* 1991;101:584-92.
2. Cox JL. Evolving applications of the maze procedure for atrial fibrillation. *Ann Thorac Surg* 1993;55:578-80.
3. Cox JL, Boineau JP, Schuessler RB, Canavan TE, Corr PB, Cain ME, et al. Modifications of the maze procedure for atrial flutter and atrial fibrillation. I. Rationale and surgical results. *J Thorac Cardiovasc Surg* 1995;110:473-84.
4. Van Hemel NM, Defauw JJ, Kingma JH, Jaarsma W, Vermeulen FE, de Bakker JM, et al. Long-term results of the corridor operation for atrial fibrillation. *Br Heart J* 1994;71:170-6.
5. Williams JM, Ungerleider RM, Lofland GK, Cox JL. Left atrial isolation. New technique for the treatment of supraventricular arrhythmias. *J Thorac Cardiovasc Surg* 1980;80:373-80.
6. Hioki M, Ikeshita M, Iedokoro Y, Nitta T, Harada A, Asano T, et al. Successful combined operation for mitral stenosis and atrial fibrillation. *Ann Thorac Surg* 1993;55:776-8.
7. Sankar NM, Farnsworth AE. Left atrial reduction for chronic atrial fibrillation associated with mitral valve disease. *Ann Thorac Surg* 1998;66:254-6.
8. Kawaguchi AT, Kosakai Y, Isobe F, Sasako Y, Eishi K, Kakano K, et al. Surgical stratification of patients with atrial fibrillation secondary to organic lesions. *Eur J Cardiothoracic Surg* 1996; 10:983-90.
9. Ortiz de Murúa JA, Ávila MC, Ochoa C, de la Fuente L, Moreno de Vega JC, del Campo F, et al. Factores predictores independientes del éxito agudo y al año de la cardioversión eléctrica en pacientes con fibrilación auricular crónica. *Rev Esp Cardiol* 2001;54:958-64.
10. Winlaw DS, Farnsworth AE, Macdonald PS, Munday JA, Spratt PM. Left atrial reduction: the forgotten Batista. *Lancet* 1998; 351:879-80.
11. Cox JL, Boineau JP, Schuessler RB, Kater KM, Lappas DG. Five-years experience with the maze procedure for atrial fibrillation. *Ann Thorac Surg* 1993;56:814-24.
12. García-Villarreal OA, Rodríguez H, Treviño A, Gouveia AB, Argüero R. Left atrial reduction and mitral valve surgery: the «functional-anatomic unit» concept. *Ann Thorac Surg* 2001;71:1044-5.
13. Josephson ME, Kastor JA. Supraventricular tachycardia. Mechanisms and management. *Ann Intern Med* 1977;87:346-58.
14. Klein GJ, Sealy WC, Pritchett EL, Harrison L, Hackel DB, Davis D, et al. Cryosurgical ablation of the atrioventricular node-His bundle. Long-term follow-up and properties of the junctional pacemaker. *Circulation* 1980;61:8-15.
15. Scheinman MM, Morady F, Hess DS, Gonzalez R. Catheter induced ablation of the atrio-ventricular junction to control refractory supraventricular arrhythmias. *JAMA* 1982;248:851-5.
16. Kosakai Y, Kawaguchi AT, Isobe F, Sasako Y, Nakano K, Eishi K, et al. Cox maze procedure for chronic atrial fibrillation with mitral valve disease. *J Thorac Cardiovasc Surg* 1994;108:1049-55.
17. Boineau JP, Canavan TE, Schuessler RB, Cain ME, Corr PB,

- Cox JL. Demonstration of a widely distributed atrial pacemaker complex in the human heart. *Circulation* 1988;77:1221-37.
18. Boineau JP, Schuessler RB, Canavan TE, Corr PB, Cain ME, Cox JL. The human atrial pacemaker complex. *J Electrocardiol* 1989;22(Suppl 1):189-97.
  19. Defauw JJ, Guiraudon GM, van Hemel NM, Vermeulen FE, Kingma JH, de Bakker JM. Surgical therapy of paroxysmal atrial fibrillation etih the «corridor» operation. *Ann Thorac Surg* 1992;53:564-71.
  20. Blackshear JL, Odell JA. Appendage obliteration to reduce stroke in cardiac surgical patients with atrial fibrillation. *Ann Thorac Surg* 1996;61:755-9.
  21. Atrial fibrillation investigators. Risk factors for stroke and efficacy of antithrombotic therapy in atrial fibrillation: analysis of pooled data from five randomized controlled trials. *Arch Intern Med* 1994;154:1449-57.
  22. Haissaguerre M, Jais P, Shah DC, Arentz T, Kalusche D, Takahashi A, et al. Catheter ablation of chronic atrial fibrillation targeting the reinitiating triggers. *J Cardiovasc Electrophysiol* 2000;11:2-10.
  23. Haissaguerre M, Jais P, Shah DC, Takahashi A, Hocini M, Quiniou G, et al. Spontaneous initiation of atrial fibrillation by ectopic beats originating in the pulmonary veins. *N Engl J Med* 1998;339:659-66.
  24. Shah DC, Haissaguerre M, Jais P. Catheter ablation of pulmonary vein foci for atrial fibrillation: PV foci ablation for atrial fibrillation. *Thorac Cardiovasc Surg* 1999;47(Suppl 3):352-6.
  25. Shah DC, Haissaguerre M, Jais P, Hocini M, Yamane T, Deisenhofer I, et al. Electrophysiologically guided ablation of the pulmonary veins for the curative treatment of atrial fibrillation. *Ann Med* 2000;32:408-16.
  26. Lin W-S, Prakash VS, Tai CT, Hsieh MH, Tsai CF, Yu WC, et al. Pulmonary Vein morphology in patients with paroxysmal atrial fibrillation initiated by ectopic beats originating form the pulmonary veins. Implications for catheher ablation. *Circulation* 2000;101:1274-81.
  27. Kay GN. Catheter ablation of atrial fibrillation: challenges and promise. *Am J Cardiol* 2000;86(Suppl 1):K25-K7.
  28. Haissaguerre M, Shah DC, Jais P, Hocini M, Yamane T, Deisenhofer I, et al. Mapping-guided ablation of pulmonary veins to cure atrial fibrillation. *Am J Cardiol* 2000;86(Suppl 1):K9-K19.
  29. Natale A. Radiofrequency ablation of the pulmonary veins: can it stop atrial fibrillation at its source? *Cleve Clin J Med* 2001;68:21-2.
  30. Scheinman MM. Mechanisms of atrial fibrillation: is a cure at hand? *J Am Coll Cardiol* 2000;35:1687-92.
  31. Thomas SP, Wallace EM, Ross DL. The effect of a residual isthmus of surviving tissue on conduction after linear ablation in atrial myocardium. *J Interv Card Electrophysiol* 2000;4:273-81.
  32. Cox JL, Schuessler RB, Lappas DG, Boineau JP. An 8 1/2 – year clinical experience with surgery for atrial fibrillation. *Ann Surg* 1996;224:267-75.
  33. Cosgrove DM, Stewart WJ. Mitral valvuloplasty. *Curr Probl Cardiol* 1989;14:355-415.
  34. Vazquez Ruiz de Castroviejo E, Martín Rubio A, Pousibet Sanfeliu H, Lozano Cabezas C, Guzman Herrera M, Tarabini Castellani A, et al. Utilización del tratamiento anticoagulante en los pacientes con fibrilación auricular no reumática. *Rev Esp Cardiol* 2000;53:200-4.
  35. Marin Ortuño F, Roldan Schilling V, Vera PM, Martínez Martínez JG, Toral Noguera A, García de Burgos Rico F, et al. Mejoría de la función fibrinolítica tras el tratamiento anticoagulante en la fibrilación auricular reumática crónica. *Rev Esp Cardiol* 1999;52:25-30.