

An analysis of the Spanish Heart Transplantation Registry. *Transpl Int.* 2015;28:305–313.

3. Harjola VP, Mebazaa A, Celutkienė J, et al. Contemporary management of acute right ventricular failure: a statement from the Heart Failure Association and the Working Group on Pulmonary Circulation and Right Ventricular Function of the European Society of Cardiology. *Eur J Heart Fail.* 2016;18:226–241.
4. Lee J, Lee K, Abidov A, Samson R, Lotun K. Endovascular stenting of suture line supra-avalvular pulmonic stenosis after orthotopic heart transplantation using rapid pacing stabilization. *JACC Cardiovasc Interv.* 2014;7:91–93.
5. Anaya-Ayala JE, Loebe M, Davies MG. Endovascular management of early lung transplant-related anastomotic pulmonary artery stenosis. *J Vasc Interv Radiol.* 2015;26:878–882.

6. Wolfsohn AL, Walley VM, Masters RG, Davies RA, Boone SA, Keon WJ. The surgical anastomoses after orthotopic heart transplantation: clinical complications and morphologic observations. *J Heart Lung Transplant.* 1994;13:455–465.

<http://dx.doi.org/10.1016/j.rec.2016.12.005>  
1885-5857/

© 2016 Sociedad Española de Cardiología. Published by Elsevier España, S.L.U. All rights reserved.

### Large Family With Marfan Syndrome Demonstrating the Pathogenicity of a “Synonymous” Variant (p.Ile2118=) in the Fibrillin-1 Gene



#### Extensa familia con síndrome de Marfan en la que se demuestra la patogenicidad de una variante «sinónima» (p.Ile2118=) en el gen de la fibrilina 1

#### To the Editor,

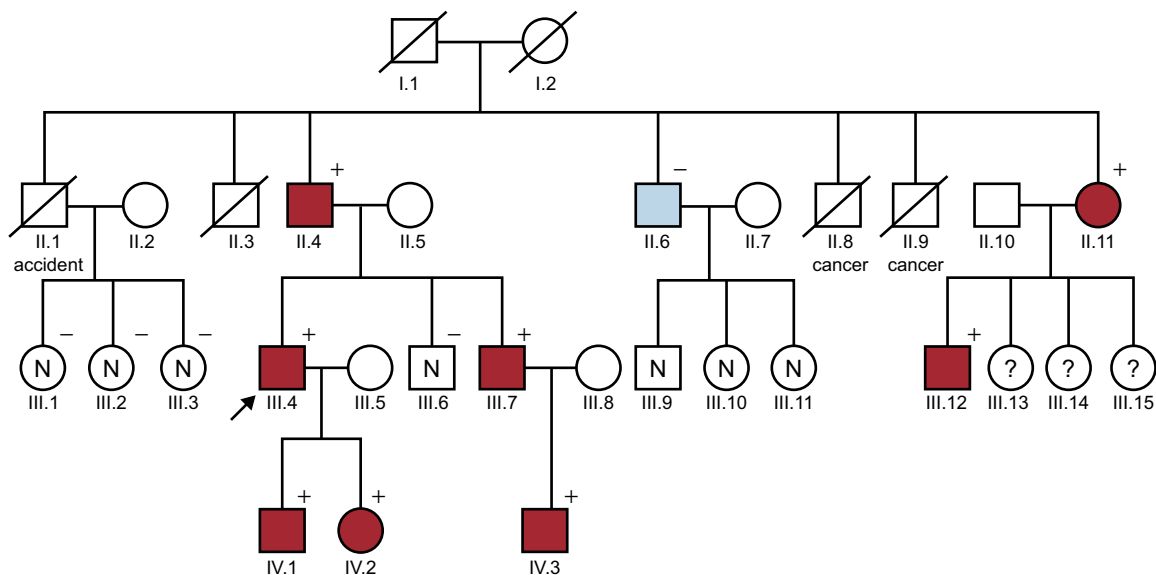
We present a family with 8 members from 3 generations with Marfan syndrome (MFS), in whom a complete familial genetic study confirmed the pathogenicity of a variant previously thought to be “synonymous”, identified on the fibrillin 1 gene (*FBN1*).

The proband is a 50-year-old Caucasian male who underwent emergency surgery for a type A aortic dissection. His 79-year-old father underwent surgery at age 56 years for dilatation of the ascending aorta with replacement of the aorta and aortic valve (Bentall procedure) and was operated on again at age 75 years for dilatation of the descending aorta. The proband had been diagnosed with ectopia lentis prior to his aortic dissection. In view of this and his father’s history, MFS was suspected. In 2008, he underwent a genetic study of the *FBN1* gene in another center,

using Sanger sequencing and multiplex ligation-dependent probe amplification (MLPA), but this was reported as negative. His 2 children were under follow-up as suspected MFS in a third center.

The familial study was centralized in our hospital. When the family tree was drawn (Figure), it identified other members with aortic dilatation or variable expression of features of MFS (Table).<sup>1</sup> The younger brother, who also had ectopia lentis, recently underwent surgery for a descending aortic aneurysm, and received a Bentall valved tube. This patient declined the aortic valve-sparing surgery offered (David procedure) due to the good outcomes in his father and brother, who had the Bentall procedure.

Given the obvious familial disease, the negative results of the previous genetic study were striking. In MFS, the percentage of patients with a positive genetic study has been reported as close to 90%.<sup>2</sup> Another genetic study was performed, this time using next generation sequencing with a panel that included 30 genes involved in aortic disease. This study identified only 1 “synonymous” variant (meaning that the change in nucleotide does not produce a change in the amino acid) in the *FBN1* gene (c.6354C>T, p.Ile2118=). The fact that this does not produce a change in the amino acid could indicate that this variant is nonpathogenic or of borderline pathogenicity. It is located in a coding region of the gene (at position 40 of exon 52, isoform



**Figure.** Family tree. Square, male; circle, female; arrow, proband; red, has MFS; blue, bicuspid aorta; diagonal line, deceased; N, assessed and healthy; ?, unknown; +, p.Ile2118= carrier; -, noncarrier.

**Table**  
Clinical Information on the Family Members Studied

Patient	Age at diagnosis, y	Sex	Clinical involvement			Surgical intervention, y	Genetic study	Diagnosis
			Musculoskeletal system	Ocular system	CV system			
II.4	56	M	+	–	AD	Bentall technique (56)	+	MFS
II.6	61	M	–	–	Bicuspid Ao	Mechanical prosthesis (63)	–	Bicuspid Ao
II.11	65	F	+	EL	AA	–	+	MFS
III.1	57	F	–	–	–	–	–	–
III.2	55	F	–	–	–	–	–	–
III.3	49	F	–	–	–	–	–	–
III.4	50	M	+	EL	AD	Bentall technique (50)	+	MFS
III.6	43	M	–	–	–	–	–	–
III.7	40	M	+	–	AA	Bentall technique (40)	+	MFS
III.12	34	M	+	EL	AA	–	+	MFS
IV.1	25	M	+	–	–	–	+	MFS
IV.2	17	F	+	–	–	–	+	MFS
IV.3	19	M	–	EL	–	–	+	MFS

–, negative; +, positive; AA, aortic aneurysm; AD, aortic dissection; Ao, aorta; CV, cardiovascular; EL, ectopia lentis; F, female; M, male; MFS, Marfan syndrome. Musculoskeletal system + if any of the following features were present: arachnodactyly, scoliosis, chest deformity, striae, acetabular protrusion, plat foot or foot deformity.

NM\_000138.4), a position that does not appear to affect any of the sites involved in the RNA cutting and splicing process. However, an RNA study, carried out by Liu et al.<sup>3</sup> in 1977, showed that this change induced skipping of exon 52 (absence of this exon in the RNA transcript). This may create a new reading frame, leading to a premature stop codon, in turn leading to a truncated protein. Alternatively, the FBN1 protein may not be expressed to the truncated protein because the cellular machinery breaks down the aberrant transcript. The fact that splicing is affected and that functional effects have been demonstrated is sufficient to demonstrate that the mutation is pathogenic.<sup>4</sup> Furthermore, this variant does not appear in databases that include information from the population used as a control. To definitively confirm its pathogenicity, however, cosegregation would need to be demonstrated in 1 of the families studied. Although 8 reports have been published of different families with suspected or clinically diagnosed MFS, these reports do not provide data from a familial study, only from the probands.<sup>5,6</sup>

In the family we present here, the cosegregation of this mutation with the disease has been demonstrated for the first time. All of the members studied meet the revised Ghent nosology<sup>4</sup> (Table). There was only 1 patient (II.6) in whom the variant was not identified, a paternal uncle of the proband. It was confirmed that he had an unrelated disease (bicuspid aorta) and had undergone surgery for aortic stenosis. Three daughters of an affected individual (III.13,14,15) could not be studied due to social reasons.

In conclusion, we have been able to establish cosegregation of the p.Ile2118= variant on the FBN1 gene for the first time through a complete clinical and genetic familial study, thus confirming its pathogenicity. We do not know if the negative genetic study performed years before failed to identify this variant (Sanger false negative) or if it was considered nonpathogenic.

It is important to have MFS reference centers or familial heart disease units that allow the performance of complete familial studies.<sup>2</sup> Performing a familial study and the correct interpretation of the variants identified in genetic studies allows a more accurate prognosis to be established, and helps ensure appropriate clinical management.

## FUNDING

This study was partly funded by the Cardiovascular Research Network, *Red de Investigación Cardiovascular* (RIC; RD12/0042/0069).

## CONFLICTS OF INTEREST

J.P. Trujillo-Quintero belongs to the clinical department of Health in Code.

Juan Pablo Trujillo-Quintero,<sup>a</sup> José María Herrera-Noreña,<sup>b</sup> Víctor X. Mosquera-Rodríguez,<sup>b</sup> Xusto Fernández-Fernández,<sup>c</sup> José Manuel Vázquez-Rodríguez,<sup>d</sup> and Roberto Barriales-Villa<sup>d,\*</sup>

<sup>a</sup>Departamento Clínico, Health in Code, A Coruña, Spain

<sup>b</sup>Servicio de Cirugía Cardíaca, Complejo Hospitalario Universitario de A Coruña, Instituto de Investigación Biomédica de A Coruña (INIBIC), Servizo Galego de Saúde (SERGAS), Universidade da Coruña, A Coruña, Spain

<sup>c</sup>Fundación Novoa Santos, Instituto de Investigación Biomédica de A Coruña (INIBIC), A Coruña, Spain

<sup>d</sup>Servicio de Cardiología, Complejo Hospitalario Universitario de A Coruña, Instituto de Investigación Biomédica de A Coruña (INIBIC), Servizo Galego de Saúde (SERGAS), Universidade da Coruña, A Coruña, Spain

\*Corresponding author:

E-mail address: rbarrialesv@gmail.com (R. Barriales-Villa).

Available online 20 January 2017

## REFERENCES

- Díaz de Bustamante A, Ruiz-Casares E, Darnaudé MT, Perucho T, Martínez-Quesada G. Variabilidad fenotípica del síndrome de Marfan en una familia con una nueva mutación en el gen FBN1. *Rev Esp Cardiol*. 2012;65:380–381.

2. Barriales-Villa R, Gimeno-Blanes JR, Zorio-Grima E, et al. Protocolo de actuación en las cardiopatías familiares: síntesis de recomendaciones y algoritmos de actuación. *Rev Esp Cardiol.* 2016;69:300-309.
3. Liu W, Qian C, Francke U. Silent mutation induces exon skipping of fibrillin-1 gene in Marfan syndrome. *Nat Genet.* 1997;16:328-329.
4. Loeys BL, Dietz HC, Braverman AC, et al. The revised Ghent nosology for the Marfan syndrome. *J Med Genet.* 2010;47:476-485.
5. Attanasio M, Lapini I, Evangelisti L, et al. FBN1 mutation screening of patients with Marfan syndrome and related disorders: detection of 46 novel *FBN1* mutations. *Clin Genet.* 2008;74:39-46.
6. Lerner-Ellis JP, Aldubayan SH, Hernandez AL, et al. The spectrum of FBN1, TGFbetaR1, TGFbetaR2 and ACTA2 variants in 594 individuals with suspected Marfan Syndrome, Loeys-Dietz Syndrome or Thoracic Aortic Aneurysms and Dissections (TAAD). *Mol Genet Metab.* 2014;112:171-176.

<http://dx.doi.org/10.1016/j.rec.2016.11.025>  
1885-5857/

© 2016 Sociedad Española de Cardiología. Published by Elsevier España, S.L.U. All rights reserved.