

Letters to the Editor

Isolated Pericardial Hydatid Cyst as a Casual Diagnosis

Quiste hidatídico pericárdico aislado como hallazgo casual

To the Editor,

We present a 54-year-old man who underwent chest radiography in the context of a respiratory infection. As an incidental finding, a well-defined cardiac contour deformity with smooth edges was detected in the right chambers (Fig. 1). Echocardiography was performed and showed a cystic appearance with partially calcified borders located on the underside of the cardiac silhouette. Function was not compromised. The study was continued using computed tomography of the thorax with contrast. The results showed a large cystic mass in the anterior mediastinum with a right para-cardiac and infracardiac location and extensive calcification of the wall, probably accompanied by pericardial calcification around the left ventricle (Fig. 2A). Magnetic resonance imaging revealed a large cystic intrapericardial image attached to the bottom of both ventricles without infiltration, with proteinaceous content and round images in the interior (Fig. 2B). We concluded that the image

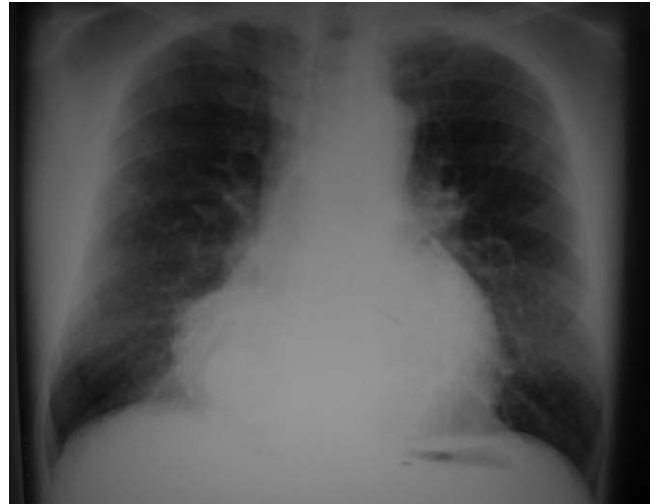

Figure 1. Chest X-ray: there is evident deformity of the cardiac silhouette, with well-defined smooth edges, in the right chambers.

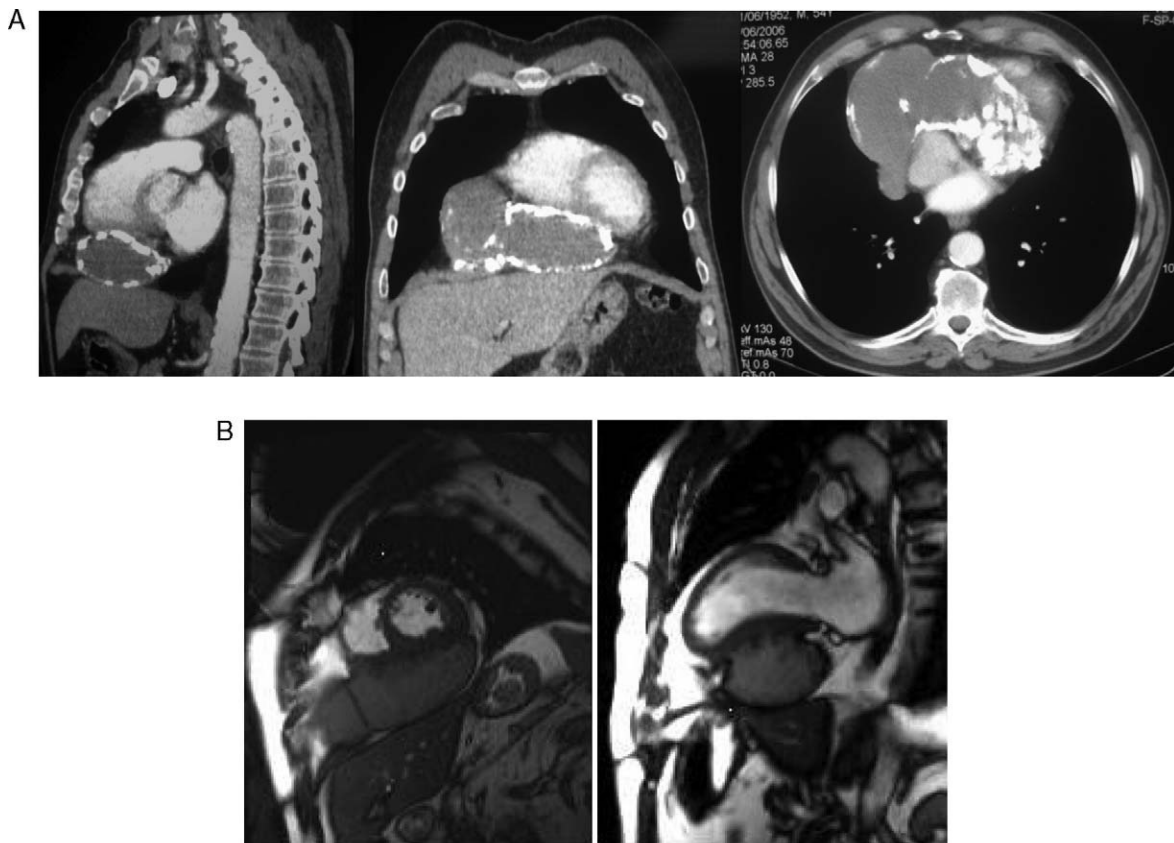


Figure 2. A: computed tomography scan of thorax shows the cystic mass in the anterior mediastinum, right paracardiac and infracardiac location, and extensive wall calcification. B: cardiac magnetic resonance; an image of the intrapericardial cyst attached to the underside of both ventricles can be observed, but without infiltration.

showed an intrapericardial hydatid cyst attached to the diaphragmatic surface of both ventricles without infiltrating them.

Exclusively cardiac hydatid disease is rare (less than 2%). *Echinococcus granulosus* reaches the heart structures through systemic circulation or by extension from adjacent structures. Clinical development depends on the size, location and integrity of the cyst, but in some cases it is asymptomatic.¹

Diagnosis can be complicated. It should be suspected from a chest radiography or echocardiography, which can easily detect deformities in the cardiac silhouette, and in the case of echocardiography, the possible existence of functional compromise. The study should subsequently be completed using computed tomography and/or high-resolution magnetic resonance imaging, which are superior to ultrasound tests in detecting structures within the mass and in defining their scope and relationship with adjacent tissues, with a view to possible surgery.²

The definitive treatment is surgical resection of the cyst, especially to avoid complications. It is sometimes used in association with medical treatment with antiparasitic drugs. In

this case, the patient was not operated on, as he was asymptomatic and rejected the intervention.

Ane Elorriaga,* Ainhoa Rubio, and Javier Bóveda
 Servicio de Cardiología, Hospital de Basurto, Bilbao, Vizcaya, Spain

*Corresponding author:
 E-mail address: aneelorriaga@yahoo.es (A. Elorriaga).

Available online 1 April 2011

REFERENCES

1. Murat V, Quian Z, Guo S, Qiao J. Cardiac and pericardial equinococcosis: report of 15 cases. *Asian Cardiovasc Thorac Ann.* 2007;15:278-9.
2. Vural M, Sayin B, Pasaoglu L, Koparal S, Elverici E, Dede D. Isolated pericardial hydatid cyst in an asymptomatic patient: a remark on its radiologic diagnosis. *Clin Imaging.* 2007;31:37-9.

doi:10.1016/j.rec.2010.10.021

Percutaneous Revascularization of Chronic Total Occlusion of the Left Main Coronary Artery

Revascularización percutánea de oclusión total crónica del tronco común izquierdo

To the Editor,

A 54-year-old, Caucasian, hypertensive, cigarette smoking man with hypercholesterolemia and without previous cardiovascular events or history of chest pain was hospitalized for dyspnea and

increased New York Heart Association (NYHA) scale. Both physical and electrocardiogram examination were within normal limits. Echocardiogram showed anterior-apical akinesia and hipokinesia of the remaining segments with severe left ventricular dysfunction: left ventricular ejection fraction (LVEF) 20%. Cardiac catheterization was then performed. Left main coronary artery (LMCA) was occluded at its very proximal portion (Fig. 1A). Right coronary artery (RCA) had a severe stenosis in the mid-distal segment (Fig. 1B). The collateral flow ran from septal branches to the left anterior descending (LAD) and from lateral branches to the left circumflex (LCX) showing a left coronary artery without stenotic lesions (Fig. 1C). A myocardial single photon emission

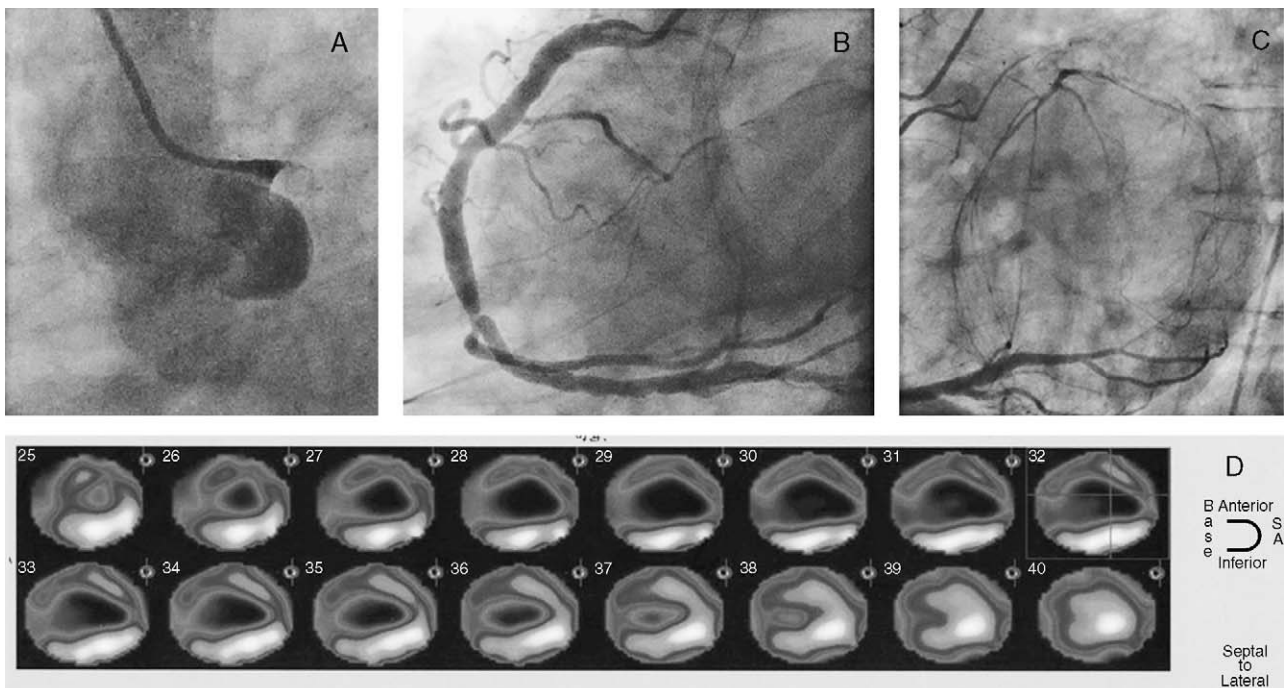


Figure 1. A-C: Admission angiography. D: Admission single photon emission tomography.