

Image in cardiology

Interventricular Septum Dissection: A Rare Complication



Diseción del septo interventricular: una complicación rara

Pedro Magalhães,* Sofia Carvalho, and J. Ilídio Moreira

Cardiology Department, Centro Hospitalar de Trás-os-Montes e Alto Douro, Hospital of Vila Real, Vila Real, Portugal

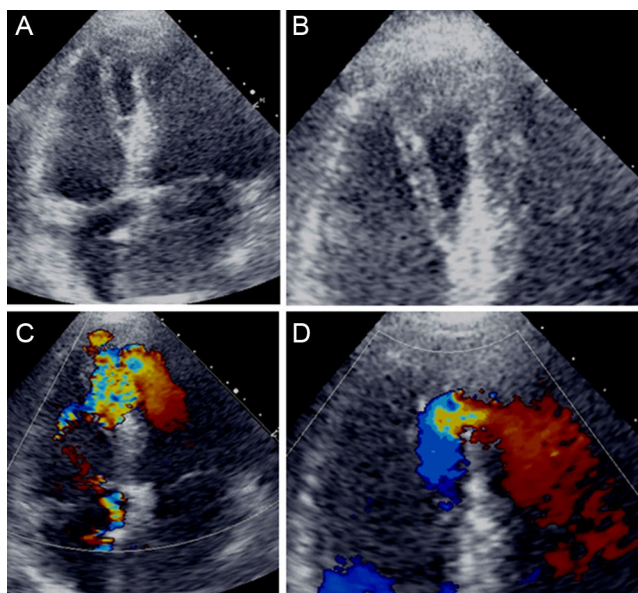


Figure.

An 81-year-old chronically hypertensive woman presented to our emergency department with a 4-day history of *crescendo* angina pectoris with associated nausea and vomiting. On admission she was anxious, hypotensive (94/68 mmHg), tachycardic (119 bpm) and had a loud holosystolic murmur, III/VI, best heard at the lower sternal border with no signs of pulmonary or peripheral congestion. The electrocardiogram showed sinus tachycardia (121 bpm), a QS pattern at leads V₁-V₂, and nonspecific repolarization abnormalities. Blood analysis revealed mildly elevated troponin T (1.3 ng/mL). After being admitted to the coronary unit, the patient underwent a transthoracic echocardiogram revealing akinesis of the apex and middle/distal interventricular septum with a large interventricular dissection and apical septum defect, through which a significant left-to-right shunt with a Qp/Qs of 2.6 and a pressure gradient of 40 mmHg could be observed (Figures A-D and videos 1-4 of the supplementary material). The coronary angiogram showed a total occlusion of the distal left anterior descending artery.

The patient remained relatively stable and 3 weeks after admission underwent successful corrective surgery of the interventricular septum defect with a bovine pericardial patch. She had an uneventful postoperative period, experiencing only mild cognitive impairment. She is now doing well after a prolonged period of recovery in a long-term care unit.

Dissection of the interventricular septum is a rare complication of acute myocardial infarction, most commonly associated with inferior wall infarcts. It is considered a subacute form of cardiac rupture, resulting from intramural hematoma formation and propagation between the spiral myocardial fibres.

SUPPLEMENTARY MATERIAL



Supplementary material associated with this article can be found in the online version available at [doi:10.1016/j.rec.2015.08.016](https://doi.org/10.1016/j.rec.2015.08.016).

* Corresponding author:

E-mail address: pedrogouveiamagalhaes@gmail.com (P. Magalhães).

Available online 25 November 2015