

## Indication for Defibrillator Implantation in a Patient With Prinzmetal's Angina and Syncope

### To the Editor:

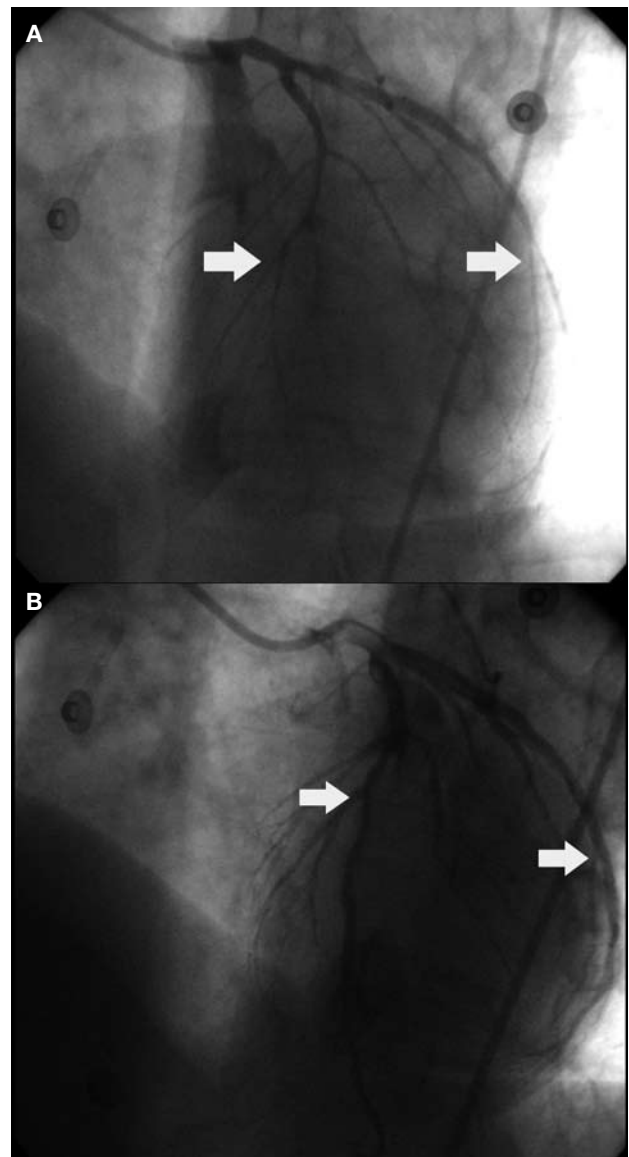
Coronary vasospasms are a possible cause of serious ventricular arrhythmias that should be taken into account in the differential diagnosis of syncope and sudden death.<sup>1,2</sup> The arrhythmias that appear in this clinical context are treated with specific vasospasm treatment. Clinical guidelines do not recommend the implantation of an anti-arrhythmic device as it is a condition that is secondary to an acute ischemia the cause of which is considered to be controllable.

We present a case of a patient with coronary vasospasms that were accompanied with potentially lethal arrhythmias that were initially controlled with medical treatment. We tested the effectiveness of the drugs using a pharmacological stress test with ergonovine and follow-up was carried out during 1 year.

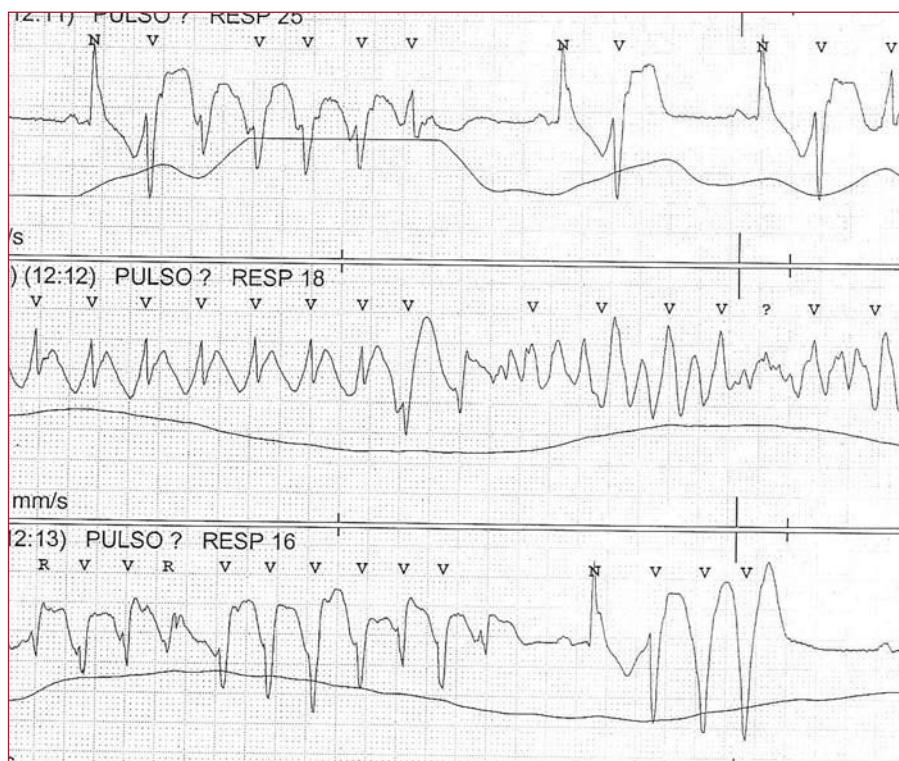
A 64-year-old male arrived at the emergency room reporting 2 syncopes preceded by retrosternal pressure. Once at the hospital, he complained of new chest pain. An electrocardiogram (ECG) was performed that showed ST elevation in II, III, and aVF. After administering intravenous nitro-glycerine, the symptoms disappeared and the ECG returned to normal. In spite of intensifying the medical treatment, this situation took place two more times. Coronary angiography demonstrated coronary spasm which resolved with intracoronary nitro-glycerine, a descending anterior artery occlusion and a moderate lesion in the circumflex artery (Figure 1). Finally, he suffered another episode associated with sinus tachycardia with a 2:1 atrioventricular block (AVB), and nonsustained polymorphic ventricular tachycardia (Figure 2). Once again, it was controlled using intravenous nitro-glycerine. We began treatment with increasing doses of diltiazem and oral nitrates, and after negative ergonovine and exercise stress tests, he was discharged.

Eight months later, and while on treatment, he suffered a new syncope. He went to the emergency room, where another syncope episode was confirmed that was accompanied by a complete AVB and ST elevation in inferior leads. Then, as a consequence of a ventricular tachycardia that evolved into a ventricular fibrillation, he needed cardiopulmonary resuscitation. A cardioverter defibrillator (ICD) was implanted and medical treatment was intensified. In the next 4 months, he did not experience any other episodes.

The most frequent form of coronary vasospasm is variant angina, or Prinzmetal's angina. Pharmacological treatment usually controls symptoms and the prognosis is generally good, with survival greater than 95% after 5 years. Less frequently, it may manifest itself as syncope or sudden death due to asystole, AVB or ventricular tachy-arrhythmia. In these cases, the prognosis could be worse if medical treatment does not ensure the elimination of episodes. Our case studies this very problem. The medication prescribed was the treatment of choice to control vasospasm. In the



**Figure 1.** A: total occlusion of the anterior descending artery at the mediodistal level and a moderate lesion in the proximal circumflex artery. B: the lesions disappear after injecting intra-coronary nitro-glycerine, and a non-significant lesion in the anterior descending artery remains.



**Figure 2.** Polymorphic ventricular tachycardia in the context of coronary vasospasm. Controlled using intravenous nitro-glycerine.

specific case of calcium antagonists, their possible use to control the *torsade de pointes* in AVB<sup>3</sup> has also been described. In order to try to provide a greater level of safety, we performed stress tests; as negative results were obtained, the implanting of a pacemaker or ICD was disregarded. However, 8 months later, 2 more episodes of potentially lethal arrhythmia took place, and therefore, the cardioverter defibrillator became necessary.

Previously, small studies<sup>4</sup> and similar clinical cases have been published that contradict other studies where no new episodes occurred once medical treatment was started.<sup>5</sup> Similarly, relapses and inefficient ICD treatments have been found most likely related with insufficient medical treatment and extensive ischemia.<sup>6</sup> Our patient presented a peculiarity that we would like to highlight: A relapse occurred while on medical treatment and presenting a negative ergonovine test.

From this case, we deduce that:

– Coronary vasospasm must be taken into account in the differential diagnosis of syncope.

– A negative ergonovine test after medical treatment does not exclude relapses. This is especially relevant in high risk contexts such as the one presented here.

– The detection of prognostic markers related to the risk of relapse is necessary.

– It is necessary to carry out studies that evaluate the indication criteria for ICD as secondary

prevention of potentially lethal arrhythmias due to coronary vasospasm.

Gonzalo Guzzo-Merello,<sup>a</sup> Claudio Romero-Tejero,<sup>a</sup> Francisco García-Cosío,<sup>b</sup> and Luis Martínez-Elbal<sup>a</sup>

<sup>a</sup>Servicio de Cardiología, Hospital Universitario de La Princesa, Madrid, Spain

<sup>b</sup>Servicio de Cardiología, Unidad de Arritmias, Hospital Universitario de Getafe, Madrid, Spain

#### BIBLIOGRAPHY

1. Myerburg RJ, Kessler KM, Mallon SM, Cox MM, De Marchena E, Interian AJ, et al. Life-threatening ventricular arrhythmias in patients with silent myocardial ischemia due to coronary-artery spasm. *N Engl J Med.* 1992;326:1451-5.
2. Peters RH J, Wever EFD, Hauer RNW, Robles de Medina EO. Low prevalence of coronary artery spasm in patients with normal coronary angiograms and unexplained ventricular fibrillation. *Eur Heart J.* 1998;19:1070-4.
3. García Cosío F, Goicolea A, López Gil M, Kallmeyer C, Barroso JL. Suppression of torsades de pointes with verapamil in patients with atrio-ventricular block. *Eur Heart J.* 1991;12:635-8.
4. Meisel SR, Mazur A, Chetboun I, Epshtein M, Canetti M, Gallimidi J, et al. Usefulness of implantable cardioverter-defibrillators in refractory angina pectoris complicated by ventricular fibrillation in patients with angiographically normal coronary arteries. *Am J Cardiol.* 2002;89:1114-6.
5. Chevalier P, Dacosta A, Defaye P, Chalvidan T, Bonnefoy E, Kirkorian G, et al. Arrhythmic cardiac arrest due to isolated coronary spasm: Long term outcome of seven resuscitated patients. *J Am Coll Cardiol.* 1998;31:57.
6. Letsas KP, Filippatos GS, Efremidis M, Sideris A, Kardaras F. Secondary prevention of sudden cardiac death in coronary artery spasm: Is implantable cardioverter defibrillator always efficient? *Int J Cardiol.* 2007;117:141-3.