

Incessant ventricular tachycardia as a manifestation of myocardial ischemia

Javier Sanz Salvo, Fernando Arribas, María López Gil, Regina Dalmau, Julio García Tejada and Santiago Jiménez Valero

Servicio de Cardiología. Unidad de Arritmias. Hospital Universitario 12 de Octubre. Madrid.

We describe four patients with incessant ventricular tachycardia after the acute phase of a myocardial infarction. Two of them had a slow heart rate, and myocardial revascularization resolved the arrhythmia after ischemia was demonstrated. In the other two cases, very fast tachycardias were interrupted by means of intravenous verapamil and clinical stabilization was achieved after failure of amiodarone and lidocaine. In one of them, revascularization prevented new recurrences, but it was not feasible in the second patient, who developed new arrhythmias. The possible mechanisms of these tachycardias and their clinical and therapeutic implications are discussed.

Key words: *Tachyarrhythmias. Ischemia. Calcium antagonists.*

Taquicardia ventricular incesante como manifestación de isquemia miocárdica

Se describen los casos de 4 pacientes con taquicardia ventricular de comportamiento incesante fuera de la fase aguda del infarto. En 2 casos la taquicardia era lenta y se resolvió con la revascularización miocárdica tras demostrar la presencia de isquemia. En los otros 2 pacientes con taquicardias muy rápidas el verapamilo intravenoso interrumpió la taquicardia y consiguió una situación clínica estable tras el fracaso de la amiodarona y la lidocaína. En uno de ellos, la revascularización miocárdica evitó nuevas recidivas y en el otro no fue posible realizarla, volviendo a presentar arritmias. Se discuten los posibles mecanismos de estas taquicardias y su enfoque clínico y terapéutico.

Palabras clave: *Taquiarritmias. Isquemia. Antagonistas del calcio.*

INTRODUCTION

Ventricular tachycardia (VT) in the chronic phase of myocardial infarction (MI) is generally due to a mechanism of intramyocardial reentry related with the infarction scar. Although in some cases ischemia can act as a trigger in this context, it normally does not have a primordial role in its appearance, which is why adequate revascularization or treatment with antianginal drugs does not control the risk of recurrence. In these cases, antiarrhythmic treatment is focused on modifying the electrophysiological properties of the reentry circuit pharmacologically (by acting on sodium or potassium channels) or by

radiofrequency ablation or surgical interruption. The administration of intravenous verapamil is contraindicated in the presence of VT, because it can produce hemodynamic deterioration. We report the cases of four patients with previous MI and VT who had a therapeutic response to verapamil administration and/or myocardial revascularization.

CLINICAL CASES

Case 1

A 66-year-old man was hospitalized for lateral MI, but not treated with fibrinolytics due to time constraints. After 72 h without complications, the patient was moved to the ward with nitrate treatment. On day 7 of admission, he presented syncopal polymorphic VT that required urgent electrical cardioversion. In the following hours, numerous episodes of sustained and non-sustained tachycardia were observed (Figure 1), with incessant behavior and occasional degeneration to ventricular fibrillation

Correspondence: Dr. F. Arribas.
Servicio de Cardiología. Unidad de Arritmias.
Hospital Universitario 12 de Octubre.
Avda. de Córdoba, s/n. 28041 Madrid.
e-mail: farribas@secardiologia.es

Received 26 February 2001.
Accepted for publication 18 June 2001.

ABBREVIATIONS

VT: ventricular tachycardia
 VF: ventricular fibrillation
 MI: myocardial infarction
 ECG: electrocardiogram

(VF), which required the application of several external shocks. These episodes were not preceded by significant bradycardia, abnormal prolongation of the QT interval, changes in the ST segment, or pain. The cardiac enzyme levels in plasma did not vary significantly. Treatment with lidocaine and intravenous amiodarone did not stabilize rhythm, rhythm stabilization was achieved only after the administration of verapamil, first intravenously, then orally.

Coronariography showed non-significant lesions in the anterior descending and right coronary arteries, as well as a subtotal lesion of the proximal circumflex, which was treated with angioplasty with good results. Thallium stress testing excluded myocardial ischemia, and visualized only posterolateral necrosis. A Holter study revealed only a few isolated extrasystoles. The patient was released with oral verapamil treatment. After 5 years of follow-up, no new clinical episodes of arrhythmia have occurred. Recently, the patient has required a new coronary angioplasty of the anterior descending artery for angina and disease progression.

Case 2

A 69 year-old man had a long history of multiple cardiovascular risk factors and ischemic heart disease.

Eighteen years before the present admission, he presented unstable angina and underwent surgical revascularization, including a descending mammary artery bypass to the anterior descending coronary artery. Since then, the patient has been hospitalized on two occasions for anteroseptal MI. Coronariography disclosed obstruction of the bypass to the anterior descending and right coronary arteries, as well as lesions in other sites that were not judged amenable to revascularization. Likewise, the patient had severe left ventricular dysfunction and had been hospitalized several times for heart failure. He followed a routine treatment with nitrates and his functional class was poor, with dyspnea and angina with minimal effort.

The patient was admitted to our hospital for rapid, sustained monomorphic VT with poor clinical and hemodynamic tolerance. After external cardioversion, electrocardiographic monitoring demonstrated an incessant arrhythmia that was organized as VT at the time of admission (Figure 2A), with continuous non-sustained and sustained episodes. Treatment with full-dose lidocaine was begun, but was not effective. Intravenous administration of 5 mg of verapamil managed to interrupt the VT, which was followed by clinical stabilization within a few minutes (Figure 2B). At no time did the patient complain of angina and the acute-phase ECG did not demonstrate ST segment or T wave changes, although electrical changes suggestive of anterolateral ischemia were apparent in the next few days. There were no enzyme changes. A new coronariography confirmed the impossibility of revascularization. The patient was released with amiodarone and diltiazem treatment.

After 2 months of follow-up, the patient was readmitted to another center for a new episode of VT in the context of anterior ischemia. Lidocaine elicited no response and he was treated with amiodarone and procainamide.

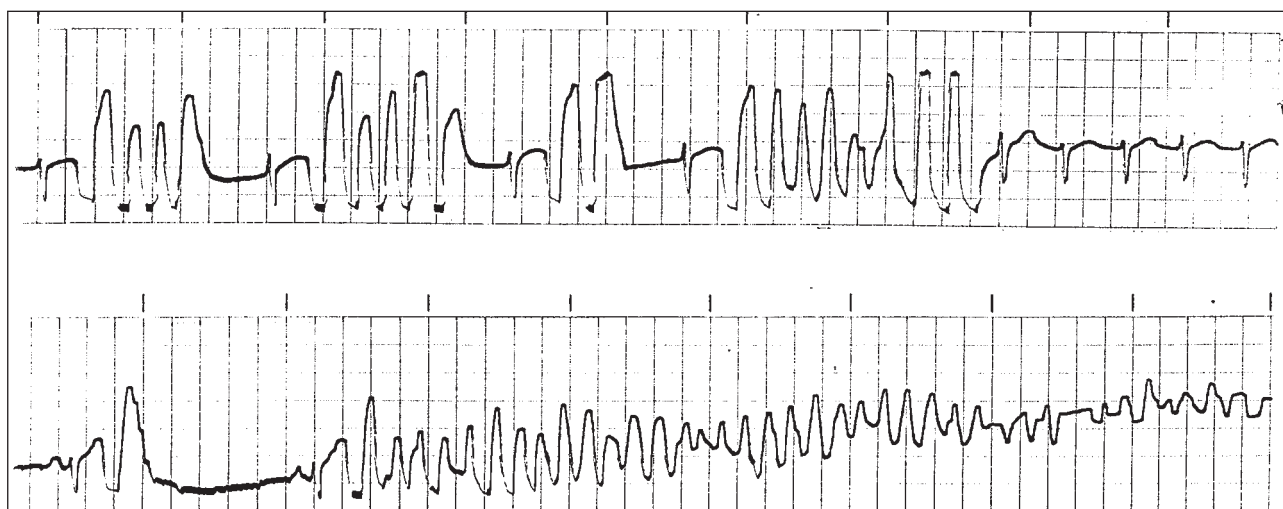


Fig. 1. Monitor recordings showing episodes of polymorphic VT with incessant behavior in case 1.

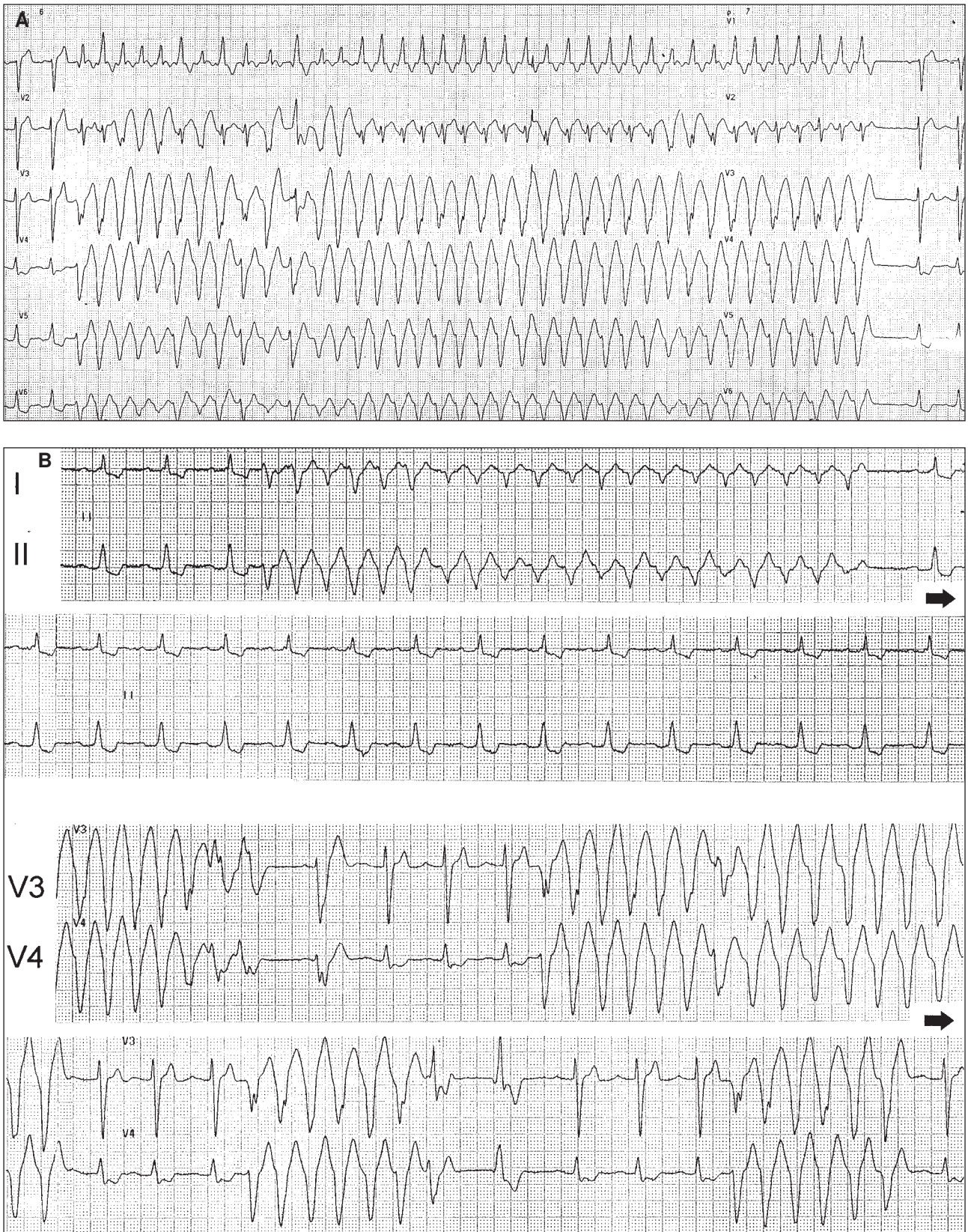


Fig. 2. A: A self-limited episode of fast, slightly irregular, particularly at the beginning, monomorphic VT (170 beats/min) in patient 2. B: The upper part shows simultaneous, continuous recordings (leads I and II) in which the end of the ventricular arrhythmia is visible after concluding the injection of verapamil 5 mg i.v. In the lower part of the Figure (leads V3 and V4), the baseline situation of the patient is stable after cardioversion at the time of admission.

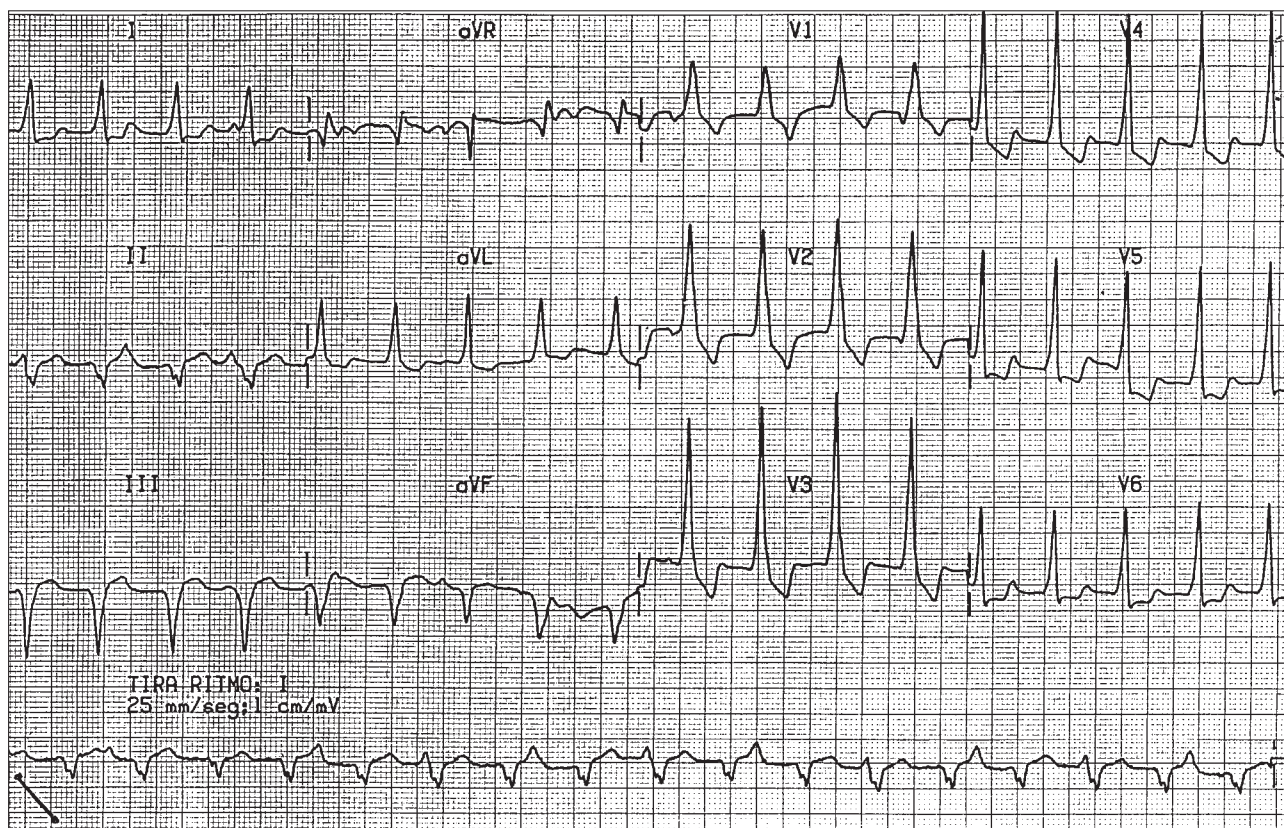


Fig. 3. Twelve-lead electrocardiogram and strip of slow, monomorphic VT rhythm (110 beats/min) in patient 3. Atrioventricular dissociation is clearly visible.

Case 3

A 46 year-old male smoker with no other medical history was hospitalized for inferior, posterior, and lateral MI. He was treated with fibrinolytics following questionable reperfusion criteria. The patient evolved without complications and a coronariography was performed, which disclosed obstruction of the medial segment of the right coronary artery with distal heterocoronary flow and conserved left ventricular systolic function. No intervention was performed on this lesion and a pre-discharge stress test was clinically negative for angina. The ECG showed late electrical positivity.

Five months later, in a routine follow-up, asymptomatic sustained slow monomorphic VT was detected in an ECG (Figure 3). Treatment with beta-blockers was begun and a Holter study was made, which demonstrated the incessant behavior of the arrhythmia, with alternating sinus and VT rhythm. A new stress test was clinically and electrically negative, and finally disclosed VT similar to the VT documented earlier. The thallium study demonstrated inferior and inferolateral ischemia with partial and total reperfusion, respectively. For this reason, angioplasty was performed on the lesion in the right coronary artery. It is interesting to note that at the beginning of

the procedure the ECG revealed VT, which disappeared during dilation.

After 11 months of follow-up, no recurrence has been documented. A stress test made 6 months after angioplasty was negative for angina or ischemia. Frequent ventricular extrasystoles appeared only with maximum effort.

Case 4

A 59-year-old man had cardiovascular risk factors and a history of postero-inferior MI that coursed with primary VF eight years before the present admission. In the intervening years he required several admissions and percutaneous interventions (angioplasty of the anterior descending coronary and second diagonal, double stent in the anterior descending coronary artery) for clinical angina. The last admission was to another center and took place 6 days before the present admission. A stress test was negative for angina but electrically positive for ischemia. Sustained monomorphic VT appeared post-effort and remitted with lidocaine. The coronariography showed patency of the two earlier stents and significant stenosis of the descending posterior coronary and medial branch (fine-caliber vessels), which were not intervened. The patient was released with diltiazem and nitrate

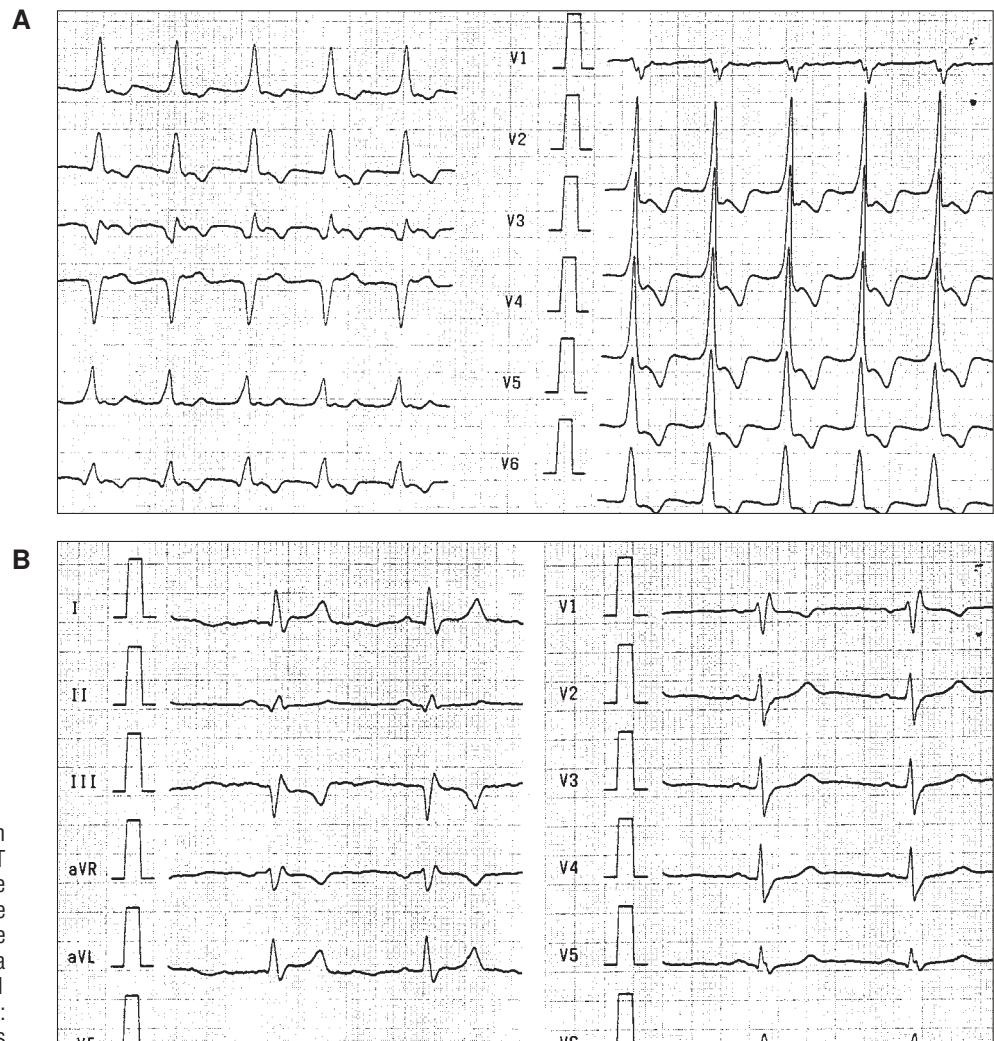


Fig. 4. A: Electrocardiogram during slow monomorphic VT (110 beats/min) in case 4. The presence of a retrograde P wave visible in the final portion of the QRS complex is appreciated as a manifestation of 1:1 ventriculoatrial conduction. 1. B: A recording of patient 4 in sinus

treatment.

Later he began to present self-limited episodes of dizziness and palpitations, and the ECG documented slow sustained monomorphic VT of incessant behavior (Figures 4A and B) that did not respond to lidocaine administration. There were no clinical manifestations of angina or electrocardiographic signs of ischemia. He was referred to our hospital for study, where he began treatment with beta-blockers, but the arrhythmic episodes continued.

Coronariography revealed an intrastent restenosis of the anterior descending coronary artery that was treated satisfactorily. The patient did not have further recurrences. A later stress test was negative for angina, ischemia or tachycardia, and an electrophysiological study failed to induce ventricular arrhythmia. In 10 months of follow-up, the patient has had no new recurrences.

DISCUSSION

These 4 cases of sustained VT in patients with MI

scar had different clinical presentations, but shared a history of myocardial ischemia added to an infarction scar and an incessant arrhythmia. Two of the patients (cases 3 and 4) presented «slow» VT (around 120 beats/min), with tendency to incessant behavior, that resembled the accelerated idioventricular rhythm that usually accompanies myocardial reperfusion. In both cases, myocardial revascularization by percutaneous angioplasty resolved the arrhythmia. In the other two patients (cases 1 and 2), the clinical course was violent, with very fast, poorly tolerated tachycardia, which in case 1 required several cardioversion interventions.

These two patients had an immediate therapeutic response to the administration of intravenous verapamil after failure of the intravenous administration of amiodarone in case 1 and lidocaine in both cases.

Some characteristics of the clinical presentation suggested a mechanism different from reentrant intramyocardial VT related to the infarction scar: a tendency to incessant behavior in the absence of antiarrhythmic drugs (type I or type III), the

ineffectiveness of conventional treatment and, finally, response to intravenous verapamil.

Patient 2 had a fast, sustained monomorphic VT, an infrequent variant in the context of acute ischemia. Peters et al. reported a case of monomorphic VT resistant to antiarrhythmic drugs that nonetheless responded to anti-ischemic therapy (beta-blockers, calcium antagonists, and nitrates). Three of our patients (cases 1, 2 and 4) were receiving nitrates before the arrhythmia appeared, but still developed tachycardia. In the other patient (case 3), treatment with beta-blockers began when the VT was detected, but it could not prevent persistence of the arrhythmia. Verapamil can abolish an arrhythmia triggered by ischemia by improving myocardial perfusion and reducing oxygen consumption. However, the resistance to certain anti-ischemic and antiarrhythmic pharmacological treatments, in contrast with the therapeutic response to verapamil, may suggest that calcium channels are involved in the genesis of these tachycardias and calcium antagonists can have a therapeutic effect independent of their purely anti-ischemic effects.

Calcium channels can intervene in the genesis of arrhythmias through diverse mechanisms. In ischemic or infarcted areas, the resting potential of cells may be disturbed, with partial or total inactivation of the sodium channels. In this situation, slow calcium channels may be activated that would give rise to arrhythmias through abnormal automaticity. The use of calcium antagonists could be hypothetically useful for the treatment of these cases, at least in experimental models. Patients 3 and 4 presented, as mentioned, a slow VT similar to the arrhythmias observed in the context of myocardial reperfusion. It is likely that these arrhythmias are due to enhanced automaticity, although they also have been related to post-potentials. Some studies have demonstrated that calcium antagonists can protect against the development of such arrhythmias.

In triggered activity, calcium channels and intracellular calcium loading may both contribute, since an occasional favorable effect of calcium antagonist drugs has been described. Postpotentials could also be important in the genesis of polymorphic VT in patients with long QT. Polymorphic VT are generally associated with the presence of long QT interval, whether of congenital or acquired origin, or to marked dispersion of repolarization. This unequal repolarization can occur in some clinical situations, such as ischemia, even with a normal QT interval in the ECG. Some authors have speculated about the possible role of M cells in the genesis of different arrhythmias. These cells constitute a cellular subpopulation located in the medial region of the ventricular myocardium, with electrophysiological characteristics that predispose them to prolongation of

the action potential and to the development of postpotentials in response to many stimuli, including agonists of the calcium channels. They could be involved above all in arrhythmias traditionally attributed to triggered activity, such as reperfusion or ischemia arrhythmias. In addition, they could constitute the substrate for a reentrant mechanism by causing dispersion of the refractory period and conduction blocks.

Patient 1 of our series developed a recurrent polymorphic VT with a normal QT interval. Wolfe et al. described the appearance of polymorphic postinfarction VT related with ischemia, in the absence of electrolyte disorders, changes in the QT interval, pauses, or bradycardia. As in our case, the use of type I antiarrhythmic drugs was ineffective, although amiodarone was useful in some cases, in contrast with our patient. In this series, revascularization also seemed to prevent recurrences.

The absence of recurrence after revascularization in patients 1, 3, and 4 confirms the important pathogenic role of ischemia acting on a propitious anatomic substrate. It is important to note that none of the patients presented previous clinical or electrocardiographic evidence of ischemia before the appearance of symptoms, although one patient later presented them. It also should be noted that the only patient who could not undergo an adequate myocardial revascularization procedure suffered a recurrence. For that reason, the main objective in these cases was to restore adequate coronary perfusion. Although calcium antagonists can be useful for stabilization in the acute phase, their long-term benefits are dubious. Patient 2 presented recurrences in spite of diltiazem treatment and patient 4 was taking it when his arrhythmia developed.

CONCLUSIONS

Myocardial ischemia can have an important role in monomorphic or polymorphic ventricular tachycardia of an incessant nature in patients with an infarction scar, even in the absence of angina or ischemic changes in the ECG. Conventional antiarrhythmic treatment can be ineffective, although it is sometimes possible to achieve stabilization in the acute phase with intravenous verapamil administration. For that reason, this therapeutic option must be considered if the usual drugs fail. Coronary revascularization must be the primordial goal and may constitute definitive therapy. Disturbances in automaticity and triggered activity secondary to myocardial ischemia could be involved in the mechanism of these arrhythmias.

REFERENCES

1. Callans DJ, Josephson ME. Ventricular tachycardia in patients with coronary artery disease. En: Zipes DP, Jalife J, editores. Cardiac electrophysiology: from cell to bedside. (3ª ed.). Filadelfia: W.B. Saunders Company, 2000; 530-536.
2. De Bakker JM, Van Capelle FJ, Janse MJ, Wilde AA, Coronel R, Becker AE et al. Reentry as a cause of ventricular tachycardia in patients with chronic ischemic heart disease: electrophysiologic and anatomic correlation. *Circulation* 1988; 77: 589-606.
3. Arenal A, Almendral J, Villacastín A, Pastor A, Martínez Alday J, Peinado R et al. Arritmias cardiacas (VII): Tratamiento farmacológico de las taquicardias ventriculares. *Rev Esp Cardiol* 1993; 46: 497-505.
4. Rankin AC, Rae AP, Cobbe SM. Misuse of intravenous verapamil in patients with ventricular tachycardia. *Lancet* 1987; 2: 472-474.
5. Peters RW, Kim HJ, Buser GA, Gold MR. Ischemically mediated sustained monomorphic ventricular tachycardia. Resolution with anti-ischemic therapy. *Chest* 1993; 104: 1613-1614.
6. Nguyen NX, Yang PT, Huycke E, Sung RJ. Verapamil and ventricular tachyarrhythmias. *Pacing Clin Electrophysiol* 1987; 10: 571-578.
7. Ducceschi V, Di Micco G, Sarubbi B, Russo B, Santangelo L, Iacono A. Ionic mechanisms of ischemia-related ventricular arrhythmias. *Clin Cardiol* 1996; 19: 325-331.
8. Mohabir R, Ferrier GR. Effects of verapamil and nifedipine on mechanisms of arrhythmia *in vivo in vitro* model of ischemia and reperfusion. *J Cardiovasc Pharmacol* 1991; 17: 74-82.
9. Priori SG, Mantica M, Napolitano C, Schwartz PJ. Early afterdepolarizations induced in vivo by reperfusion of ischemic myocardium. A possible mechanism for reperfusion arrhythmias. *Circulation* 1990; 81: 1911-1920.
10. Grimm W, Marchlinski FE. Accelerated idioventricular rhythm, bi-directional ventricular tachycardia. En: Zipes DP, Jalife J, editores. Cardiac electrophysiology: from cell to bedside. (3ª ed.). Filadelfia: W.B. Saunders Company, 2000; 673-677.
11. Sclarovsky S, Strasberg B, Fuchs J, Lewin RF, Arditi A, Klainman E et al. Multifocal accelerated idioventricular rhythm in acute myocardial infarction: electrocardiographic characteristics and response to verapamil. *Am J Cardiol* 1983; 52: 43-47.
12. Luo CH, Rudy Y. A dynamic model of the cardiac ventricular action potential. II. Afterdepolarizations, triggered activity and potentiation. *Circ Res* 1994; 74: 1097-1113.
13. Cosío FG, Goicolea A, López Gil M, Kallmeyer C, Barroso L. Suppression of torsades de pointes with verapamil in patients with atrio-ventricular block. *Eur Heart J* 1991; 12: 635-638.
14. Shimizu W, Ohe T, Kurita T, Kawade M, Arakaki Y, Aihara N et al. Effects of verapamil and propranolol on early afterdepolarizations and ventricular arrhythmias induced by epinephrine in congenital long QT syndrome. *J Am Coll Cardiol* 1995; 26: 1299-1309.
15. Antzelevitch C, Sicouri S. Clinical relevance of cardiac arrhythmias generated by afterdepolarizations. Role of M cells in the generation of U waves, triggered activity and torsade de pointes. *J Am Coll Cardiol* 1994; 23: 259-277.
16. Cranefield PF, Aronson R. Torsade de pointes and other pause-induced ventricular tachycardias: the short-long-short sequence and early afterdepolarizations. *Pacing Clin Electrophysiol* 1988; 11: 670-678.
17. Antzelevitch C, Sicouri S, Litovsky SH, Lukas A, Krishnan SC, Di Diego JM et al. Heterogeneity within the ventricular wall. Electrophysiology and pharmacology of epicardial, endocardial and M cells. *Circ Res* 1991; 69: 1427-1449.
18. Sicouri S, Antzelevitch C. Afterdepolarizations and triggered activity develop in a select population of cells (M cells) in canine ventricular myocardium: the effects of acetylcholine and Bay K 8644. *Pacing Clin Electrophysiol* 1991; 14: 1714-1720.
19. Wolfe CL, Nibley C, Bhandari A, Chatterjee K, Scheinman M. Polymorphous ventricular tachycardia associated with acute myocardial infarction. *Circulation* 1991; 84: 1543-1551.