

Idiopathic Chylopericardium. A Case in Point

To the Editor:

A 41-year-old man presented dyspnea on moderate to heavy exertion 1 month before hospitalization. The examination showed normal vital signs, with no jugular vein enlargement or paradoxical pulse, low-intensity heart sounds, and pericardial rub. The laboratory workup revealed hemoglobin 18 g/dL, leukocytes 6.4, glucose 73 mg/dL, creatinine 1.1 mg/dL, and C-reactive protein 62.2 mg/dL. The echocardiogram showed severe pericardial effusion. A pericardial window was created, obtaining 1100 mL of a milky, nonfetid fluid, and a drainage tube was inserted. Fluid culture was negative. Cytochemical analysis of the pericardial fluid showed cholesterol 88 mg/dL, triglycerides 1830 mg/dL, lactate dehydrogenase 334 U/L, proteins 5.69 g/dL, and albumin 3.17 g/dL. Nonspecific inflammatory changes were observed in the pericardial biopsy. Chylopericardium was diagnosed and a diet based on medium-chain fatty acids was initiated; however, the drainage output did not decrease (Figure 1). This required thoracic duct ligation through the right posterolateral

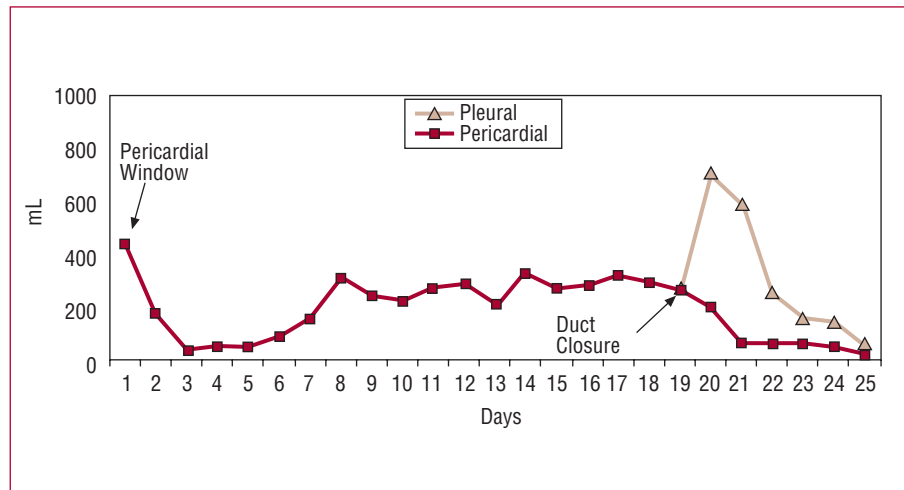


Figure 1. Drainage output.

thoracotomy 20 days after the pericardial window was created, which achieved a decrease in drainage output. The drains were removed 6 days after surgery and the patient was discharged on the 8th day with no complications. There was no recurrence at 10 months of follow-up.

Chylopericardium is a rare pathological entity. It can present in primary form, although this is uncommon, or secondary mainly to surgical procedures, thrombosis of the vena cava or subclavian vein, lymphangioma, mediastinal neoplasms, cystic hygromas, and radiation exposure.

Hasebrock¹ was the first to describe the presence of 22.6 mL of chyle in the pericardial cavity, detected during the autopsy of a man who had died from asphyxia secondary to constriction and tracheal ulceration.

The clinical entity "primary chylopericardium" was first described by Groves and Effler² in 1954 in association with a cystic hygroma of the mediastinum. In our opinion, we believe this case cannot be considered primary.

At the time of writing, approximately 61 cases had been described in the scientific literature, of which 31 were considered primary. The most recent was published by Yoon et al¹ in 1993.

Explaining the pathophysiology of primary chylopericardium is not simple. The factors implicated include microscopic connections between the pericardial sac and the thoracic duct and the presence of distal obstruction that leads to increased pressure and chyle leakage to the pericardium. Other authors attempt to explain the entity by chyle reflux through incompetent valves of the lymphatic vessels which, for some reason, drain into the pericardium, or by an incapacity to form new collaterals that should direct the lymphatic flow toward the established lymphatic-venous connections.

The diagnosis requires analysis of the fluid obtained. A milky fluid that contains fat, high levels of triglycerides, and proteins, and an elevated lymphocyte concentration confirms the diagnosis of chyle.

These patients should be treated primarily to prevent cardiac tamponade, avoid metabolic, nutritional, and immunological

compromise, and eliminate lymphatic fluid losses through medical and/or surgical treatment. A dietary approach based on medium-chain fatty acids is able to decrease chylous fluid losses and, on occasions, may even eliminate this loss completely. Nevertheless, this objective is not always achieved. In such cases, surgery should be considered, whether pericardiectomy or thoracic duct ligation, either as an open procedure, or using a thoracoscopy. If these options fail, pericardium-peritoneal Denver shunting remains as a therapeutic option.³

In addition to treating the underlying cause in secondary cases, the definitive treatment for chylopericardium is thoracic duct ligation. Both thoracoscopy and open thoracotomy have similar outcomes, although thoracoscopy has lower associated morbidity and better postoperative recovery.

Jorge L. Cervantes-Salazar,
Juan E. Calderón-Colmenero,
and Samuel Ramírez-Marroquín

Servicio de Cirugía de Cardiopatías Congénitas,
Instituto Nacional de Cardiología Ignacio Chávez,
México DF, Mexico

REFERENCES

1. Yoon YS, Shim WH, Cheng TS, Lee YS. Primary idiopathic chylopericardium: report of a case and review of the literature. *Yonsei Med J.* 1993;34:98-108.
2. Groves LK, Effler DB. Primary chylopericardium. *N Engl J Med.* 1954;250:520-3.
3. Barry BK, Murphy MC, Rodgers BM. Management of chylopericardium. *J Pediatr Surg.* 1990;25:1185-9.