

Hypoxemia and Stroke in a Patient With a Pacemaker

Rosa M. Jiménez, Francisco Martín, Maximiliano Diego, José L. Santos, Antonio Arribas, and Cándido Martín Luengo

Servicio de Cardiología, Hospital Universitario de Salamanca, Salamanca, Spain.

We report a woman with a VVI pacemaker and a history of stroke and severe hypoxemia due to a right-to-left shunt. Anomalous blood flow was through a patent foramen ovale, and was related directly with severe tricuspid regurgitation because the ventricular pacemaker electrode was adhered to the tricuspid valve. She was treated successfully with surgery. We review the role of patent foramen ovale from a clinical point of view, and current therapeutic options.

Key words: *Stroke. Patent foramen ovale. Tricuspid valve regurgitation. Pacemaker.*

Full English text available at: www.revespcardiol.org

Cianosis y accidente cerebrovascular en una paciente con marcapasos

Mostramos el caso de una paciente portadora de marcapasos VVI que presentó un accidente cerebrovascular e hipoxemia severa por un cortocircuito derecha-izquierda. Éste se generaba a través del foramen oval permeable, en relación con una regurgitación tricuspíde grave originada por la adhesión del electrodo de estimulación ventricular al endocardio valvular. Fue corregido satisfactoriamente mediante técnica quirúrgica. Revisamos el papel que desempeña el foramen oval permeable desde el punto de vista clínico y las opciones terapéuticas de las que se dispone en la actualidad.

Palabras clave: *Accidente cerebrovascular. Foramen oval permeable. Insuficiencia tricuspíde. Marcapasos.*

INTRODUCTION

The presence of patent foramen ovale (PFO) has been related to several diseases, such as cryptogenic stroke in young patients, decompression sickness in divers and astronauts, and right-to-left shunt, both persistent or induced by upright position.

Currently, the development of new non-invasive diagnostic techniques, such as transesophageal Doppler echocardiography and the use of contrast echocardiography, has facilitated its diagnosis.

The best treatment is still subject to debate. Therapeutic options include closing the PFO by percutaneous or surgical intervention, and pharmacological treatment with platelet aggregation inhibitors and/or oral anticoagulants in cases of paradoxical embolism.

CLINICAL CASE

A 70-year-old woman with no known cardiovascular risk factors had a VVI pacemaker inserted 20 years previously for prolonged sinus arrest with syncope. Two years before the current admission, she suffered a stroke in the right middle cerebral artery territory from which she fully recovered. During admission, all supplementary tests (including cranial computed tomography [CT], and Doppler echocardiography of the supra-aortic trunks and clotting screen) were normal. After the stroke, the patient experienced dyspnea on mild effort. Physical examination revealed central and peripheral cyanosis, bilateral palpable carotid pulse without bruits, and sinus rhythm at 80 beats/min with a new grade III/VI systolic murmur at the left sternal edge that increased on inspiration. The remaining physical examination was normal. Hematological evaluation revealed hemoglobin of 18 g/dL, a hematocrit of 56% and normal leukocyte and platelet counts. Basal arterial blood gases yielded pH 7.45, pCO₂ and pO₂ of 38 mm Hg and 45 mm Hg, respectively, HCO₃ of 34, and O₂ saturation of 83%. The electrocardiogram showed atrial flutter with an atrial rate of 300 beats/min and a mean ventricular rate of 100 beats/min, QRS

Correspondence: Dra. R.M. Jiménez Hernández
Padre Astete, 16, 3.º G.
37004 Salamanca, España.
E-mail: rosamj@eresmas.com

Received 13 December, 2002.
Accepted 20 November, 2003.

ABBREVIATIONS

PFO: patent foramen ovale.

axis at 90°, and complete right bundle branch block. A chest x-ray showed grade I cardiomegaly, as well as the electrode adhering to the right atrium.

Due to the hypoxemia, the respiratory function was evaluated with spirometry, plethysmography, and CO transfer factor, and yielded normal values. These results, together with the refractory nature of the hypoxemia after administration of 100% oxygen, led us to suspect intracardiac shunt. Thus, a transthoracic echocardiogram was performed which revealed severe tricuspid regurgitation. Transesophageal echocardiography showed that blood flowed mainly towards the interatrial septum and crossed to the left atrium through the PFO. The passage of microbubbles into the left atrium after intravenous administration of agitated saline serum confirmed the presence of a shunt (Figure). The calculated systolic pulmonary arterial pressure was 40 mm Hg, and all other echocardiographic parameters were normal.

We decided to close the PFO surgically given that it was necessary to extract the pacemaker electrode and repair the tricuspid valve. Closure was done without complications. During the extraction of the electrode we detected a large loop adhering to the tricuspid valve by abundant fibrinous material causing its anatomical breakdown.

The postoperative period was without complications, sinus rate went back to normal values and there was arterial oxygen saturation of 83% to 97% without oxygen support. A control echocardiogram showed trivial tricuspid regurgitation and the absence of microbubbles passing through the interatrial septum on contrast echocardiography.

Several weeks after the intervention, the patient presented a pulmonary thromboembolism, from which she recovered satisfactorily. The consequences of this might have been dramatic had the foramen ovale been patent.

DISCUSSION

The foramen ovale is a vestige of the fetal circulation which supplies oxygenated blood from the placenta to the systemic arterial circulation of the fetus without involving the lung circuit. Its closure usually happens spontaneously during the first 2 years of life.

Depending on the series, the incidence of PFO in the general population varies from 6% to 29%. The clinical relevance of PFO lies in its connection to several events: stroke and peripheral arterial embolism

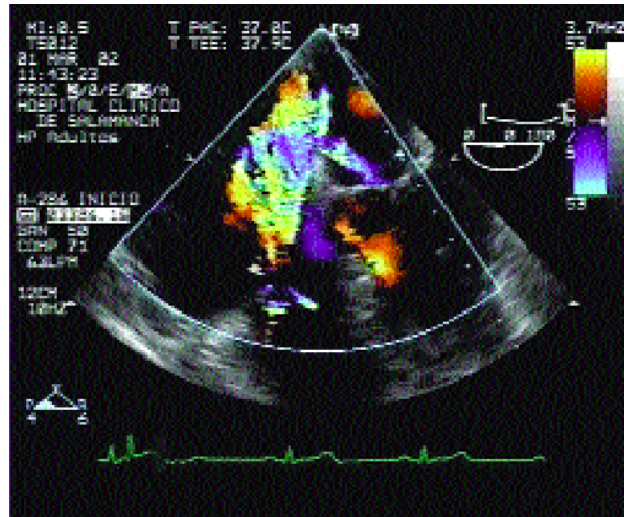


Figure. Transesophageal echocardiography of patent foramen ovale. A color Doppler echocardiography shows tricuspid regurgitation flowing toward the interatrial septum passing to the left atrium via the patent foramen ovale.

in young patients,^{1,2} brain abscess, decompression sickness in divers and astronauts³ and, less frequently, right-to-left shunt² either persistent or only occurring in a standing position. The latter is called platypnoea-orthodeoxia syndrome because it is position-dependent, i.e. dyspnea is experienced in the upright position but disappears upon adopting a recumbent position. A persistent shunt causing serious hypoxemia is quite rare and tends to be related to a pressure increase in the right chambers induced by the Valsalva maneuver, reduction of right ventricle contractility, mechanical compression of right atrium,⁴ etc. In our case, the hypoxemia was secondary to a serious right-to-left shunt which persisted both in the recumbent and upright position.

The existence of PFO should be suspected in young patients with no cardiovascular risk factors who present a stroke without apparent cause, and in patients with hypoxemia without an associated lung disease.

There has to be strong clinical suspicion of PFO, since physical examination, electrocardiograms, and chest x-rays do not provide conclusive data. The diagnostic technique of choice is transesophageal echocardiogram, whose effectiveness increases with the use of contrast echocardiography⁵ and provocation maneuvers to increase the pressure in the right atrium and facilitate the passage of microbubbles toward the left atrium.

The best treatment to be adopted in patients with PFO and stroke is still currently a matter of debate. The alternatives range from percutaneous closing of the PFO⁶ to surgical intervention,⁷ as well as pharmacological treatment with platelet aggregation inhibitors or oral anticoagulants⁸ in case of paradoxical embolism.

In our case, the hypoxemia was caused by a serious right-to-left shunt through the PFO due to severe tricuspid regurgitation with the flow mainly toward the PFO. The tricuspid insufficiency was possibly caused by the pacemaker electrode making contact with the tricuspid valve which, together with an inflammatory process that had not been clinically detected due to silent endocarditis, would have caused the deterioration and breakdown of the tricuspid valve. The organic dysfunction of the valve kept the shunt persistent through the foramen ovale causing the hypoxemia.

The stroke that the patient experienced 2 years earlier was probably caused by paradoxical embolism, since the most frequent causes had been ruled out after doing the usual supplementary tests (Doppler echocardiography of the supra-aortic trunks, cranial computed tomography and clotting screen).

Our decision to proceed with the surgical closure of the PFO was based on the need to extract the electrode and repair the tricuspid valve which seemed to be directly responsible for the clinical symptoms.

The interest of this case rests on the fact that a pacemaker electrode caused severe tricuspid regurgitation with blood flow toward the PFO leading to right-left shunt with cyanosis and symptomatology requiring surgical intervention.

REFERENCES

1. Webster MW, Smith HJ, Sharpe WN, Chancellor AM, Swift DL, Bass NM, et al. Patent foramen ovale in young stroke patients. *Lancet* 1988;2:11-2.
2. Lechat P, Mas JL, Lascault G, Loron P, Therad M, Kilmczac M, et al. Prevalence of patent foramen ovale in patients with stroke. *N Engl J Med* 1998;318:1148-52.
3. Kerut EK, Truax WD, Borreson TE, van Meter KW, Given MB, Giles TD. Detection of right to left shunts in decompression sickness in divers. *Am J Cardiol* 1997;79:377-8.
4. Sánchez N, Ruano J, Celemín I, Magureri J, Martín R. Foramen oval permeable como causa de hipoxia severa en el postoperatorio inmediato de trasplante cardíaco. *Rev Esp Cardiol* 2001;54:522-4.
5. Comess KA, DeRook FA, Beach KW, Lytle NJ, Golby AJ, Albers GW. Transesophageal echocardiography and carotid ultrasound in patients with cerebral ischemia: prevalence of findings and recurrent stroke. *J Am Coll Cardiol* 1994;23:1598-603.
6. Martín F, Sánchez PL, Doherty MD, Colón Hernández PJ. Percutaneous transcatheter closure of patent foramen ovale in patients with paradoxical embolism. *Circulation* 2002;106:1121-6.
7. Dearani JA, Ugurlu BS, Danielson GK, Daly RC, McGregor CG, Mullany CJ, et al. Surgical patent foramen ovale closure for prevention of paradoxical embolism-related cerebrovascular ischemic events. *Circulation* 1999;100:III171-5.
8. Mas JL, Arquizan C, Lamy C, Zúber M, Cabanes L, Derumeaux G, et al. Recurrent cerebrovascular events associated with patent foramen ovale, atrial septal, aneurysm or both. *N Engl J Med* 2001;345:1740-6.