

Hybrid Procedures for Complex Aortic Pathology: Initial Single Center Experience

Marcio F. Maciel Da Rocha, Salvador Miranda, Domingo Adriani, Francesca Ugnani, Vicente A. Rimbau, and Jaime Mulet

División de Cirugía Vascul, Instituto del Tórax, Hospital Clínic, Universidad de Barcelona, Barcelona, Spain

Introduction and objectives. To review experience at our center with the use of hybrid techniques for treating complex aneurysms of the thoracic aorta.

Methods. The medical records of 41 patients (40 male) with complex aortic aneurysms affecting supra-aortic or visceral vessels who underwent hybrid procedures between 1998 and 2007 were reviewed retrospectively. All patients were in American Society of Anesthesiologists category IV. They were divided in 2 groups: group A comprised 32 patients with aneurysms involving the aortic arch and its branches (2 ascending aorta replacements, 1 arch repair, 13 carotid-carotid bypasses, 12 carotid-subclavian bypasses, and 4 with total arch debranching); and group B comprised 9 patients with thoracoabdominal aneurysms and visceral vessel transpositions (4 partial and 5 total debranching). The mean age in group A was 69.3 (1.3) (range, 62-73) years and in group B, 71.5 (5.0) (range, 68-74) years.

Results. The mean hospital stay was 18 (7.1) days (range, 5-35) and 12 (8.2) days (range, 2-15) in groups A and B, respectively. Overall mortality was 12.2% (3.4% and 44.4% in groups A and B, respectively) and neurological morbidity was 3.4% and 11.1% in the 2 groups, respectively.

Conclusions. The results obtained with hybrid treatment of the aortic arch area were comparable with those of conventional surgery. However, thoracoabdominal repair with complete revascularization of the visceral branches was associated with high mortality. Consequently, hybrid treatment is a valid option for high-risk patients who do not require complete revascularization in the visceral area.

Key words: *Thoracic aneurysm. Endovascular. Complex aneurysm. Aortic arch. Thoracoabdominal. Hybrid surgery.*

Procedimientos híbridos para patología aórtica compleja. Experiencia inicial de un centro

Introducción y objetivos. Revisar la experiencia de nuestro centro con técnicas híbridas para tratamiento de aneurismas complejos de la aorta torácica.

Métodos. Se revisaron retrospectivamente los registros prospectivos de 41 pacientes (40 varones) con aneurismas torácicos que comprometían ramas supraaórticas o viscerales sometidos a procedimientos híbridos, en el periodo 1998-2007. Todos los pacientes fueron clasificados como ASA IV. Éstos fueron divididos en 2 grupos: grupo A, 32 pacientes con aneurismas que involucraban el arco aórtico y sus ramas (2 sustituciones de aorta ascendente, 1 reparación de arco, 13 derivaciones carótido-carotídeas, 12 derivaciones carótido-subclavias y 4 transposiciones totales de troncos supraaórticos); grupo B, 9 pacientes con aneurismas toracoabdominales (4 transposiciones parciales y 5 totales de troncos viscerales). En el grupo A la media de edad fue 69,3 ± 1,3 (intervalo, 62-73) años, y en el grupo B fue 71,5 ± 5,0 (intervalo, 68-74) años.

Resultados. La media de estancia hospitalaria fue 18 ± 7,1 días (intervalo, 5-35) y 12 ± 8,2 días (intervalo, 2-15) para los grupos A y B, respectivamente. La mortalidad global fue del 12,2% (el 3,4 y el 44,4% para los grupos A y B, respectivamente), con morbilidad neurológica del 3,4 y el 11,1%, respectivamente.

Conclusiones. Los resultados de nuestros tratamientos híbridos en la zona del arco aórtico son comparables con los de la cirugía convencional. Las reparaciones toracoabdominales con revascularización completa de las ramas viscerales se asocian a mortalidad elevada. Así, la cirugía híbrida es una alternativa válida para pacientes de alto riesgo que no precisen la revascularización completa del área visceral.

Palabras clave: *Aneurisma torácico. Endovascular. Aneurisma complejo. Arco aórtico. Toracoabdominal. Cirugía híbrida.*

Correspondence: Dr. V.A. Rimbau.
División de Cirugía Vascul. Instituto del Tórax. Hospital Clínic.
Villarroel, 170. 08036 Barcelona. España.
E-mail: vriambau@clinic.ub.es

Received April 6, 2008.
Accepted for publication May 20, 2009.

INTRODUCTION

Standard surgical treatment for aneurysms of the thoracic aorta (TAA) entails high morbidity and mortality.^{1,2} In the last 10 years, endovascular treatment of TAA has emerged as a new option, offering several advantages over the traditional approach³ as it is less invasive, and avoids thoracotomy and aortic clamping, and their consequences.

With the new technique, new challenges in the treatment of TAA have arisen that we need to overcome. The endoprosthesis has certain limitations due to the anatomy of the aortic arch itself, its curved geometry and calcification of the aorta and its points of access, adequate fixation and deployment of the endoprosthesis in the arch different diseases may affect the aortic wall finally, the durability of materials.

In some cases, endovascular treatment of thoracic aneurysms can prove challenging. The techniques used in hybrid surgery, used in hybrid surgery, that is the combination of open surgery with endovascular techniques, were developed in order to treat complex cases. Broadly speaking, hybrid surgery has 2 forms: one involves the aortic arch and its branches, and the other involves the thoracoabdominal segment and its visceral branches. Theoretically, the principal advantage of this new technique is the fact it avoids complete aortic clamping and its morbid consequences. The objective of the present study is to review initial experience of hybrid techniques in the treatment of complex TAA involving supra-aortic or visceral branches at our center.

METHODS

From March 1998 thru March 2007, our experience of endovascular treatment of TAA involved 158 patients; 41 of these had genuine aneurysms affecting supra-aortic or visceral branches and underwent hybrid procedures. We excluded transient iliac access, patients receiving hybrid prostheses ("frozen elephant trunk"),⁴ or aortic conditions other than aneurysms. In the same period, 183 patients with TAA underwent conventional open-heart surgery.

Retrospectively, we analyzed the prospective data corresponding to this cohort. The anesthesiologist classified all patients as ASA IV on a pre-operative visit. We therefore considered them not apt for traditional surgical treatment due to severe medical comorbidities. The comorbidities recorded were: type 2 diabetes mellitus (12.2%), coronary heart disease (24.4%), chronic obstructive pulmonary disease (73.1%), congestive heart failure (9.7%),

hostile thorax (4.8%), terminal kidney failure (7.3%), and kidney transplantation (4.8%). Patients were assessed through their case history, physical examination, blood and urine tests, chest x-ray, effort spirometry, and echocardiography. We defined aneurysms as complex if they fully involved the supra-aortic or visceral branch ostium, presented a <2 cm center-luminal distance between the ostium and the start of the aneurysm, or had a <2 cm endoprosthesis neck seal. For endoprosthesis implantation, the proximal and distal neck had to measure ≥ 2 cm along the central axis of the aorta.

To analyze data, we divided the patients in 2 groups: group A, patients with aneurysms involving the aortic arch; and group B, patients with aneurysms involving the descending aorta and visceral vessels.

Group A comprised 32 patients, 31 men, with mean age 69.3 (1.3) years (range, 62-73); group B consisted of 9 patients, with mean age 71.5 (5.0) years (range, 68-74). Aneurysm size was 6.8 (2.0) cm (range, 5.9-8.2) and 6.8 (2.1) cm (range, 6.4-10.1), respectively. The 32 group A patients received 2-stage treatment with a 6.2 day (range, 2-30) mean time lapse between procedures. Three had been operated previously for aneurysm of the ascending aorta (3 anterior semi-arch reconstructions); 13 patients underwent pretracheal carotid-carotid bypasses; 12 underwent carotid-subclavian bypasses; and the remaining 4 underwent total supra-aortic debranching. In group B, 4 patients underwent partial debranching of the visceral vessels and 2-stage endoprosthesis implantation (mean time lapse, 4.5 days; range, 2-7). The remaining 5 patients required total visceral debranching and thoracic endoprosthesis implantation in a single procedure.

All surgical interventions were programmed and took place under general anesthetic. Conventional surgery took place in the vascular surgery operating theater as did the simultaneous repairs. For endoprosthesis implantation, we used a BV300 mobile x-ray system (Philips, Eindhoven, The Netherlands). Second stage endoprosthesis implantations were performed in the angio-radiology department's designated, fully-equipped endovascular room and a high-quality, stationary Axiom-Artis x-ray system was used (Siemens, Erlangen, Germany). Endoprostheses diameters were 15%-20% oversized in all patients. The exclusion criteria were presenting diseases of connective tissue, severely calcified aorta, and comorbidities leading to probable <2-year life expectancy.

All patients gave informed consent. This study is part of the integrated endovascular treatment of the aorta project approved by the Ethics Committee of our center in 1997.

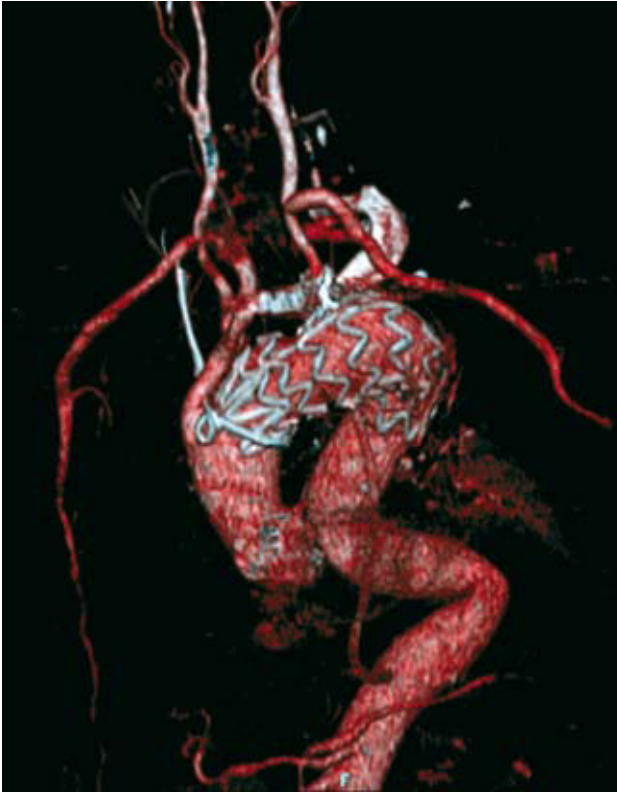


Figure 1. Total debranching of supra-aortic trunks. Donor graft from ascending aorta.

RESULTS

Exclusion of aneurysms without endoleaks was achieved in all programmed interventions, representing a technical success rate of 100%.

According to the Classification of thoracic aorta by zones⁵, in the group A patients, 4 endoprostheses were implanted in zone 0 (Figure 1), 13 in zone 1, 12 in zone 2, and 3 in zone 3. In the 9 group B patients, 5 underwent revascularization of the 4 visceral branches (2 renal, celiac trunk, and superior mesenteric) as they presented type II (2 patients) and type III (3 patients) thoracoabdominal aneurysms. Of the remaining patients, 3 presented type IV and 1, type V thoracoabdominal aneurysms. These only required partial revascularization of the branches: 2, by way of a retrograde aorto-supraceliac trunk bypass; 1 received 3 retrograde bypasses from the aorta to the right renal, superior mesenteric, and 1 celiac trunk (Figure 2). One received a double bypass from the abdominal aorta to the celiac trunk and superior mesenteric artery.

The mean intensive care unit stay was 5 (6) days (range, 2-28) in group A and 4 (3.2) days (range, 1-10) in group B. The mean hospital stay was 18

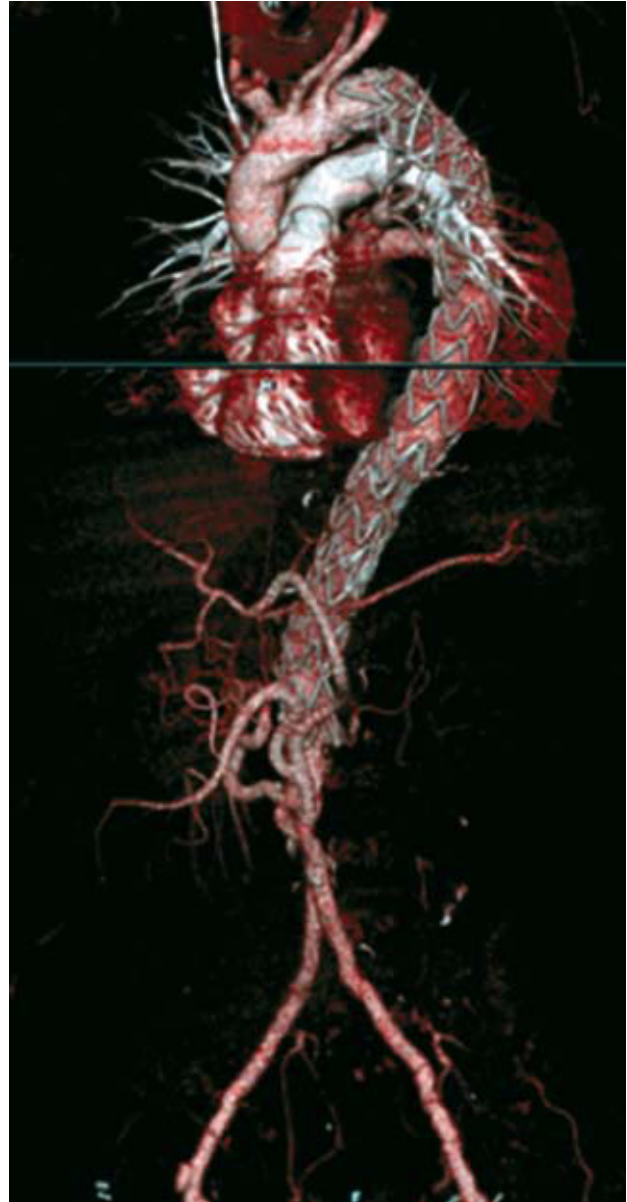

Figure 2. Debranching of right renal arteries, superior mesenteric and celiac trunk in a patient with only 1 kidney and a prior bifurcated graft.

(7.1) days (range, 5-35) in group A and 12 (8.2) days (range, 2-15) in group B.

Post-operatively, 2 group A patients presented pneumonia and 1 developed cervical lymphorrhagia following a carotid-subclavian bypass. In group B, 1 had kidney failure and 3 presented severe gastrointestinal complications (2 pancreatitis and 1 mesenteric infarction). In 2 patients we recorded general neurologic morbidity, representing total incidence of 4.8% (3.4% and 11.1% for A and B, respectively): 1 group A patient had multiple embolia in cerebral and bilateral cerebellum territories in the

TABLE 1. Immediate Results According to Adjuvant Surgical Technique

	In-hospital Mortality	Neurologic Morbidity	Major Morbidity
Grupo Group A	3.4%	3.4%	12.5%
Ascending aorta	0/3	0/3	
Carotid-carotid	0/13	1/13	
Carotid-subclavian	0/12	0/12	
Total debranching	1/4	0/4	
Group B	44.4%	11.1%	56.5%
Partial revascularization	0/4	0/4	
Total revascularization	4/5	1/5	
Total	12.2%	4.8%	21.9%

context of an arch with atherothrombosis and severe calcification⁶ and 1 group B patient had paraplegia, without recovering, followed by multiorgan failure and death. Total morbidity was 21.9% (12.5% and 55.5% for groups A and B, respectively). General 30-day mortality was 12.2% (Table 1). We recorded 1 (3.4%) death in group A and 4 (44.4%) deaths in group B. During the 6.2-year (range, 1-10) mean follow-up, 1 decubitus ulcer of a carotid-carotid bypass at 1 year postimplantation was successfully corrected with sternomastoid myoplasty.⁷ We found no other complications and performed no reinterventions of the aorta. We did not find bypass occlusions in the postoperative period.

DISCUSSION

Prevalence of TAA in the western world is on an upward trend due to the aging of the population and the widespread use of diagnostic imaging techniques.⁸ Since the last decade, surgical treatment, which traditionally entails high rates of mortality and morbidity, has been able to draw on new therapeutic strategies.³ Surgical mortality is as high as 34% in some centers.⁹ In a retrospective study, Rigberg et al¹⁰ showed that the 30-day mortality of open repair of thoracoabdominal aortic aneurysms in California was 19%, increasing to 31% at 365 days. Major complications were spinal cord ischemia, pulmonary problems, and kidney damage.

However, the risk of thoracic aorta aneurysm lesions rupturing is high if they go untreated.¹¹ Eleftheriades¹² identified thoracic aneurysm size as a predictor of complication (rupture or dissection). At the critical dimensions— ≥ 6 cm diameter for the ascending aorta and 7 cm for the descending aorta—the probability of rupture or dissection is 31% and 43%, respectively. Of 94 patients without

surgical treatment, Crawford et al¹³ found 76% died after 2 years; half died due to a rupture.

Recently, endovascular treatment has burst onto the therapeutic scene as a way to reduce mortality and perioperative complications. With the endovascular approach, we eliminate aortic clamping and thoracotomy and avoid excessive blood loss, the use of extracorporeal circulation and/or circulatory arrest, and the consequent hemodynamic instability and coagulation disorders. Difficulties, like the inadequate adaptation of the endoprosthesis to the internal curvature of the aortic arch or the presence of supra-aortic or visceral branches in the sealing and fixation zone, do exist. However, hybrid techniques represent a solution in the treatment of aneurysms involving these critical areas, without the need for complete aortic clamping.

In this retrospective study, our limited experience describes a special group of patients with severe comorbidities. In this context, we excluded aortic conditions other than aneurysm, like pseudoaneurysms or dissections of the aorta. In these patients, treatment strategies varied according to the anatomic conditions they presented. Patients with aortic arch conditions treated with hybrid techniques achieved highly acceptable results: 3.4% mortality, 12.5% morbidity, and only 1 requiring reintervention for carotid-carotid graft exteriorization. The scenario was clearly worse for patients needing revascularization of the visceral vessels, with 44.4% mortality and 55.5% morbidity. In particular, in patients undergoing total revascularization of the 4 branches and simultaneous endoprosthesis implantation we recorded an unacceptable 80% mortality (4 of 5 patients died in the immediate postoperative). These differences in results derive from the surgical part of the hybrid treatment. Most supra-aortic bypasses are extra-anatomic and sternotomy is not needed. Visceral

revascularizations require laparotomy with substantial dissections and lengthy intervention times. To this, is added the implantation of very extensive endoprostheses with iodine contrast, which worsens the renal function of patients with renal parenchyma who have suffered recent ischemia during their respective bypasses. With greater surgical experience and the use of technical resources like VORTEC (*Viabahn, Open, Rebranching, TEChnique*, described by Lachat, presented at SITE 2007, Barcelona), we will probably be able to improve on these results.

Other modest experiences of applying hybrid techniques to solve the pathologic processes of the arch appear in the literature. For example, in a series of 15 patients with aneurysms of the aortic arch treated with hybrid procedures, in the perioperative period, Saleh et al¹⁴ recorded 26% of adverse results like thrombosis of the artery at the site of access, "postimplantation syndrome" (back pain, high temperature, leucocytosis, and reduced platelet count), cervical lymphorrhagia following left subclavian tranposition and pulmonary complications (pneumonia) leading to the death of 1 patient at 2 months. In 22 patients requiring an "elephant trunk" complemented by an endovascular procedure, Greenberg et al¹⁵ recorded transient neurologic events in 13.6%. In 27 patients undergoing supra-aortic debranching, Czerny et al¹⁶ reported 2 deaths, 1 due to myocardial infarction and 1 to rupture of the aneurysm while awaiting the endovascular procedure.

In the near future we will be able to avail ourselves of technologic advances that will facilitate the management of aneurysms of the arch in the form of the development of single-branch endoprostheses. These will enable us to avoid sternotomy when debranching of all supra-aortic trunks is necessary by being able to direct the branch towards the brachiocephalic trunk and complete the cervical extra-anatomic revascularization towards the rest of the supra-aortic trunks. In this context, the experience of Chuter et al is of note.¹⁷ They described the modular branched endoprosthesis developed initially in a rubber model for use in the treatment of aortic arch aneurysms. Schneider et al¹⁸ report a case of correction of a pseudoaneurismatic aortic arch with this procedure. Another proposal is to resort to the use of stents parallel to the endoprosthesis, between the aorta and the corresponding branch. This still-controversial approach is known internationally as the "chimney technique" (presented by Malina at SITE 2007, Barcelona).

On this point, it is worth commenting on the still controversial need for left subclavian artery revascularization.¹⁹ Our group currently performs

selective revascularization. That is, in the presence of an aberrant right vertebral artery, a dominant left vertebral artery, a permeable mammary-coronary bypass, a functional arteriovenous fistula in the upper left extremity, the antecedent of abdominal aortic vascular surgery, faced with planning extensive endoprosthetic coverage of the descending thoracic aorta, or in left-handed professionals. The most-feared consequence of deliberate occlusion of the left subclavian artery is the appearance of paraplegia.²⁰ Therefore, strictly applied selection criteria are needed in these cases.

In the literature, we find experiences that demystify left subclavian occlusion. Palma et al²¹ reported a series of 14 patients undergoing deliberate subclavian occlusion by an endoprosthesis and found no adverse effect. In a 24-patient series, Riesenman et al²² reported only 1 required reintervention, to treat a left extremity with claudication. Also, in our experience, in 12 selected cases we were able to achieve left subclavian artery occlusion without prior revascularization and with no clinical consequences.²³

Furthermore, experiences of hybrid treatment of thoracoabdominal aneurysms appear in the literature. In a series of 32 patients, Chiesa et al²⁴ found 30.8% morbidity and 23% mortality. In 29 procedures, Black et al⁹ reported 21 major complications including prolonged respiratory support, inotropic support, kidney failure requiring some or no temporary support, prolonged ileum, left hemisphere stroke, and ischemic left colon resection. If we look at open conventional surgery series in centers of excellence, authors such as Achouh et al²⁵ report 7% incidence of gastrointestinal complications in 1159 thoracic aneurysms. In this group of complex patients mortality rose to 39.9%; intestinal infarction (62%) was the most frequent cause of death.

A recent review of experience of hybrid repair of thoracoabdominal aneurysms stresses the fact that published series are very small, which means firm conclusions cannot be drawn. However, it is proposed as an alternative for patients at high surgical risk.²⁶ In our experience, we reserve this hybrid technique for partial revascularization, preferably, in 2-stage interventions.

Other options for treating thoracoabdominal aneurysms are branched endoprostheses. In an initial series of 9 patients with thoracoabdominal aneurysms and treated with branched endovascular grafts, Greenberg et al²⁷ recorded 1 dissection of the superior mesenteric artery, 1 reintervention to perform a fenestration of the celiac, and 2 patient deaths in the immediate postoperative. The future development of endoprostheses with more manageable branches and increased clinical

experience will make this technique the preferred alternative in selected patients.

CONCLUSIONS

Provisionally, we conclude that while recognizing that endovascular treatment is less aggressive than traditional open surgery, until long-term follow-up results are available, hybrid techniques should be reserved for patients at high surgical risk. In our experience, results show hybrid treatments in the aortic arch zone are acceptable and comparable with conventional surgery in lower risk patients in centers of excellence. However, thoracoabdominal repairs with total revascularization of visceral branches entail high mortality. Therefore, hybrid repair is a valid alternative for high-risk patients who do not require total revascularization of the visceral area. Greater experience in these techniques would improve current results. We hope endovascular technology continues to develop new ideas to simplify procedures in the near future.

REFERENCES

- Cambria RP, Clouse WD, Davison JK, Dunn PF, Corey M, Dorer D. Thoracoabdominal aneurysm repair: results with 337 operations performed over a 15-year interval. *Ann Surg.* 2002;4:417-9.
- Derrow AE, Seeger JM, Dame DA, Carter RL, Ozaki CK, Flynn TC, et al. The outcome in the United States after thoracoabdominal aortic aneurysm repair, renal artery bypass, and mesenteric revascularization. *J Vasc Surg.* 2001;34:54-61.
- Dake MD, Miller DC, Semba CP, Mitchell RS, Walker PJ, Liddell RP. Transluminal placement of endovascular stent-grafts for the treatment of descending thoracic aortic aneurysms. *N Engl J Med.* 1994;331:1729-34.
- Karch M, Chavan A, Hagl C, Friedrich H, Galanski M, Haverich A. The frozen elephant trunk technique: a new treatment for thoracic aortic aneurysms. *J Thoracic Cardiovasc Surg.* 2003;125:1550-3.
- Criado FJ, Barnatan MF, Rizk Y, Clark NS, Wang CF. Technical strategies to expand stent-graft applicability in the aortic arch and proximal descending thoracic aorta. *J Endovasc Ther.* 2002;9 Suppl 2:32-8.
- Murillo I, Martins J, Rivadeneira M, Riambau V. Amaurosis post-tratamiento híbrido en aneurisma de aorta torácica. *Tech Endovasc.* 2005;8:1523.
- Pontes C, Riambau V. Mioplastia cervical en derivación carótido-carotídea adyuvante a endoprótesis torácica. *Tech Endovasc.* 2004;7:1232.
- Clouse WD, Hallett JW Jr, Schaff HV, Gayari MM, Ilstrup DM, Melton LJ 3rd. Improved prognosis of thoracic aortic aneurysms: A population-based study. *JAMA.* 1998;280:1926-9.
- Black AS, Wolfe JHN, Clark M, Hamady M, Cheshire N JW, Jenkins MP. Complex thoracoabdominal aortic aneurysms: Endovascular exclusion with visceral revascularization *J Vasc Surg.* 2006;43:1081-9.
- Rigberg DA, McGory ML, Zingmond DS, Maggard MA, Agustin M, Lawrence PF, et al. Thirty-day mortality statistics underestimate the risk of repair of thoracoabdominal aortic aneurysms: A statewide experience. *J Vasc Surg.* 2006;43:217-23.
- Perko MJ, Norgaard M, Herzog TM, Olsen PS, Schroeder TV, Pettersson G. Unoperated aortic aneurysms: a survey of 170 patients. *Ann Thorac Surg.* 1995;59:1204-9.
- Elefteriades JA. Natural history of thoracic aortic aneurysms: indications for surgery, and surgical versus nonsurgical risks. *Ann Thorac Surg.* 2002;74:S1877.
- Crawford ES, DeNatale RW. Thoracoabdominal aortic aneurysm: Observations regarding the natural course the disease. *J Vasc Surg.* 1986;3:578-82.
- Saleh HM, Inglese L. Combined surgical and endovascular treatment of aortic arch aneurysms. *J Vasc Surg.* 2006;44:460-6.
- Greenberg RK, Haddad F, Svensson L, O'Neill S, Walker E, Lyden SP, et al. Hybrid approaches to thoracic aortic aneurysms the role of endovascular elephant trunk completion. *Circulation.* 2005;112:2619-26.
- Czerny M, Gottardi R, Zimpfer D, Schoder M, Grabenwoger M, Lammer M, et al. Mid-term results of supraaortic transpositions for extended endovascular repair of aortic arch pathologies. *Eur J Cardiothorac Surg.* 2007;31:623-7.
- Chuter TAM, Schneider DB, Reilly LM, Lobo EP, Messina LM. Modular branched stent graft for endovascular repair of aortic arch aneurysm and dissection. *J Vasc Surg.* 2003;38:859-63.
- Schneider DB, Curry TK, Reilly LM, Kang JW, Messina LM, Chuter TAM. Branched endovascular repair of aortic arch aneurysm with a modular stent-graft system. *J Vasc Surg.* 2003;38:855.
- Peterson BG, Eskandari MK, Thomas GG, Morasch MD. Utility of left subclavian artery revascularization in association with endoluminal repair of acute and chronic thoracic aortic pathology. *J Vasc Surg.* 2006;43:433-9.
- Buth J, Harris PL, Hobo R, Van Eps R, Cuyper P, Duijm L, et al. Neurologic complications associated with endovascular repair of thoracic aortic pathology: Incidence and risk factors. a study from the European Collaborators on Stent/Graft Techniques for Aortic Aneurysm Repair (EUROSTAR) registry. *J Vasc Surg.* 2007;46:1103-10.
- Palma JH, Souza JAM, Alves CMR, Carvalho AC, Buffolo E. Self-expandable aortic stent-grafts for treatment of descending aortic dissections. *Ann Thorac Surg.* 2002;73:1138-42.
- Riesenman PJ, Farber MA, Mendes RR, Marston WA, Fulton JJ, Keagy BA. Coverage of the left subclavian artery during thoracic endovascular aortic repair. *J Vasc Surg.* 2007;45:90-5.
- Riambau V. Indications for subclavian revascularization prior intentional occlusion by thoracic endografting. En: Brancherau A, Jacobs M, editores. *Hybrid vascular procedures.* New York: Futura-Blackwell Publishing; 2004. p. 85-9.

24. Chiesa R, Tshomba Y, Melissano G, Marone EM, Bertoglio L, Setacci F, et al. Hybrid approach to thoracoabdominal aortic aneurysms in patients with prior aortic surgery. *J Vasc Surg.* 2007;45:1128-35.
25. Achouh PE, Madsen K, Miller III CC, Estrera AL, Azizzadeh A, Dhareshwar J. Gastrointestinal complications after descending thoracic and thoracoabdominal aortic repairs: A 14-year experience. *J Vasc Surg.* 2006;44:442-6.
26. Donas KP, Czerny M, Guber I, Teufelsbauer H, Nanobachvili J. Hybrid open-endovascular repair for thoracoabdominal aortic aneurysms: current status and level of evidence. *Eur J Vasc Endovasc Surg.* 2007;34:528-33.
27. Greenberg RK, West K, Pfaff K, Foster J, Skender D, Haulon S, et al. Beyond the aortic bifurcation: Branched endovascular grafts for thoracoabdominal and aortoiliac aneurysms. *J Vasc Surg.* 2006;43:879-86.