

Our results, even with the limitation of the small number of patients, confirm the benefits of OAC in patients in routine clinical practice with NVAf and a CHA₂DS₂-VASc score of 2 or higher, but not in those with a CHA₂DS₂-VASc score of 1. In our opinion, the benefit of anticoagulation therapy in the latter group is questionable and, in any case, small.

Martín Ruiz-Ortiz,* Elías Romo, Dolores Mesa, Mónica Delgado, Cristina López-Ibáñez, and José Suárez de Lezo

Servicio de Cardiología, Hospital Reina Sofía, Córdoba, Spain

* Corresponding author:

E-mail address: maruor@gmail.com (M. Ruiz-Ortiz).

Available online 12 August 2011

REFERENCES

1. Camm AJ, Kirchhof P, Lip GY, Schotten U, Savelieva I, Ernst S, et al. Guías de práctica clínica para el manejo de la fibrilación auricular. 2nd ed. revised April 8, 2011. Rev Esp Cardiol. 2010;63:1483.e1-83.
2. Ruiz Ortiz M, Romo Peñas E, Franco Zapata M, Mesa Rubio D, Anguita Sánchez M, Delgado Ortega M, et al. Anticoagulación oral en la fibrilación auricular no valvular: ¿son efectivas y seguras las recomendaciones científicas en la práctica clínica diaria? Rev Esp Cardiol. 2006;59:688-95.
3. Ruiz Ortiz M, Romo E, Mesa D, Delgado M, Anguita M, Castillo JC, et al. Oral anticoagulation in nonvalvular atrial fibrillation in clinical practice: impact of CHADS₂ score on outcome. Cardiology. 2010;115:200-4.
4. Lip GY, Nieuwlaat R, Pisters R, Lane DA, Crijns HJ. Refining clinical risk stratification for predicting stroke and thromboembolism in atrial fibrillation using a novel risk factor-based approach: the Euro Heart Survey on atrial fibrillation. Chest. 2010;137:263-72.
5. Lip GY, Frison L, Halperin J, Lane D. Identifying patients at risk of stroke despite anticoagulation. Stroke. 2010;41:2731-8.

doi: 10.1016/j.rec.2011.05.025

High Risk Anomalous Origin of the Right Coronary Artery

Variante maligna del origen de la coronaria derecha

To the Editor,

We present the case of a 31-year-old female native of Colombia, with no cardiovascular risk factors or relevant medical history, who was referred to a cardiologist for oppressive chest pain on effort of possible coronary origin and of 5 years of evolution. On physical examination there were no pathological findings of interest. ECG

showed a sinus rhythm of 50 bpm, without repolarization alterations; chest X-ray was normal; transthoracic echocardiogram showed a normal sized left ventricle with preserved function, without any changes in general and segmental contractility. A maximum stress test was performed according to the Bruce protocol, which resulted in positive clinical signs and negative electrical signs for ischemic heart disease.

With these findings and given the patient's low risk of ischemic heart disease, a cardiac computed tomography (CT) angiography was requested. This is a non invasive anatomical imaging study which makes it possible to assess the coronary arteries and

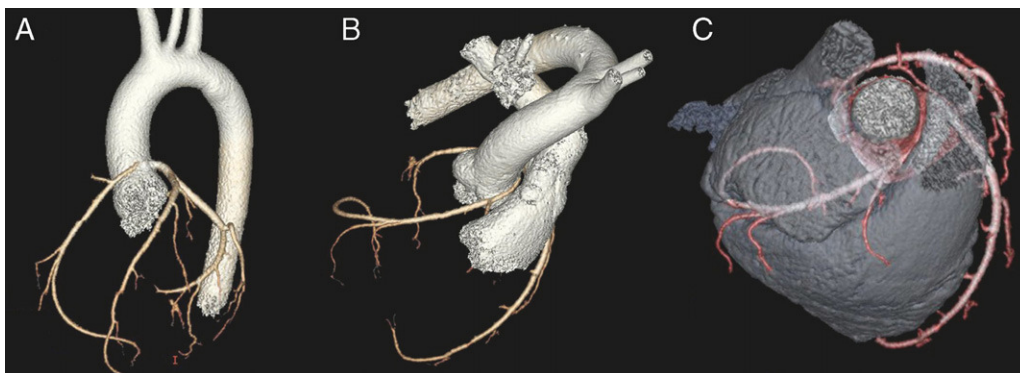


Figure 1. 64-slice coronary computed tomography (prospective acquisition) with volume reconstruction: an anomalous right coronary artery arising from the left sinus of Valsalva, decreased caliber and interarterial course.

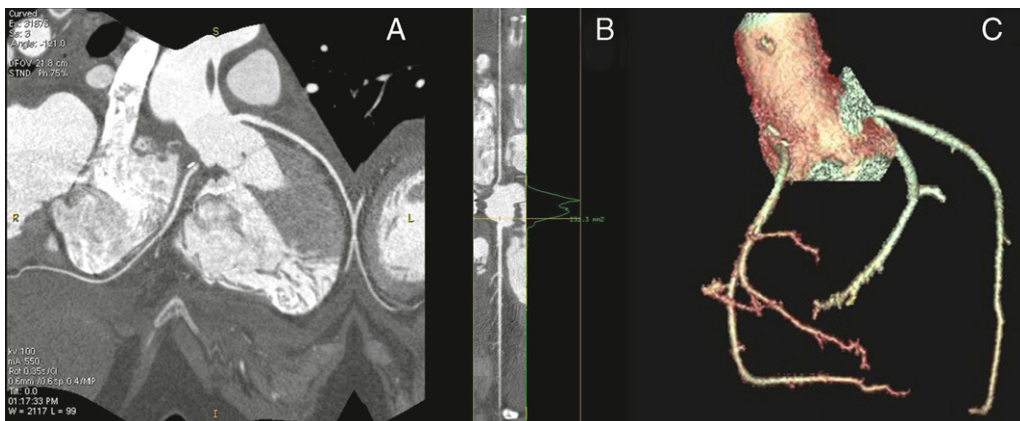


Figure 2. Right coronary artery reimplemented in the non-coronary sinus, without residual stenosis.

characterise atherosclerotic plaque¹ (it must be kept in mind that it does not provide functional coronary information.) The feasibility and diagnostic accuracy of this study have improved due to widespread use of 64-slice multidetector CT scanners. Current systems provide a clear view of the main coronary arteries and their branches, with a spatial resolution similar to that of conventional angiography.² The usefulness of this technique is that it provides a maximum negative predictive value (99%-100%) to rule out coronary disease.³ Thus, this technique significantly influences the stratification of selected patients with low or intermediate risk who come to the emergency department with chest pain.²

A triple rule-out study was performed after informing patients and obtaining their informed consent for inclusion in an institutional protocol. It was negative for pulmonary thromboembolism and acute aortic syndrome, while non-invasive coronary angiography (64-slice helical CT in prospective acquisition with volume reconstruction performed in sinus rhythm and calcium score 0) showed codominance; normal circumflex artery and left anterior descending artery and its branches; and an anomalous right coronary artery arising from the left sinus of Valsalva (Fig. 1A) with decreased calibre due to hypoplasia of the ostium and a sharp angled origin in the aorta. Furthermore, its course ran between the pulmonary artery and the ascending aorta (Figs. 1B and C). All these findings indicate a high risk anomalous origin of the right coronary artery.

Congenital anomalous origin of coronary arteries is seen in 1% to 1.2% of all coronary angiograms. 0.5% of them show high-risk lesions of the left main trunk or anterior descending branch with their origin in the opposite sinus of Valsalva. Coronary anomalies are the cause of 15% of sudden deaths in athletes. In 80% of the autopsies of athletes after sudden death with coronary arteries of anomalous origin, the affected coronary artery runs between the aorta and the pulmonary artery. Currently, the anatomical description of a coronary artery that passes between the aorta

and pulmonary artery in a young person (under 50) is a major risk factor for an adverse event, with or without symptoms.⁴ In this instance, after diagnostic confirmation by invasive coronary angiography, we opted for surgical revascularization by coronary reimplantation (AHA/ACC³ class I indication). It is worth noting that we were able to confirm the anomalous origin and interarterial course of the coronary artery, and furthermore, we found a 2 cm intramural course beginning at the mid-surface of the right sinus. We reimplanted the right coronary artery in the non-coronary sinus, without complications and with a good outcome (Figs. 2A-C).

Cristina Goena,* Amaia Ibarra, Marta Campaña, Rubén Natividad, Koldobika García, and Pedro M. Montes

Servicio de Cardiología, Hospital de Cruces, Barakaldo, Bizkaia, Spain

* Corresponding author:

E-mail address: M.CRISTINA.GOENAVIVES@osakidetza.net (C. Goena).

Available online 12 August 2011

REFERENCES

1. Min J, Shaw L, Berman D. The present state of coronary computed tomography angiography. *J Am Coll Cardiol.* 2010;55:957-65.
2. Michael C. Kontos, Exploraciones de imagen no invasivas para la evaluación de los pacientes de bajo riesgo en unidades de dolor torácico: disponibilidad, utilidad e inconvenientes en la práctica clínica real. *Rev Esp Cardiol.* 2011;64:92-5.
3. Roberts WT, Bax JJ, Davies LC. Cardiac CT and CT coronary angiography: technology and application. *Heart.* 2008;94:781-92.
4. Warnes C, Williams R, Bashore T, Child S, Connolly H, Dearani J, et al. 2008 ACC/AHA Guidelines for adults with CHD. *Circulation.* 2008;118:714-833.

doi: 10.1016/j.rec.2011.05.032

Parameters of Arterial Stiffness: Hypertensive and Diabetic Patients vs Controls

Parámetros de rigidez arterial en sujetos hipertensos y diabéticos comparados con controles

To the Editor,

Arterial stiffness predicts cardiovascular morbidity and mortality, and can be evaluated with: pulse wave velocity (PWV),¹ ambulatory arterial stiffness index (AASI),^{2,3} and augmentation index (AI).⁴

There are studies in Spain on arterial stiffness in various subpopulations,⁵ but there are no studies that have jointly analyzed PWV, AASI, and AI in diabetic and hypertensive patients. The aim of this study is to report average values for these parameters in diabetic and hypertensive patients compared to controls, and to analyze determining factors.

From 2006 to 2010, we recruited 373 patients from consultations in 2 health centers. Those who had medical histories of cardiovascular disease were excluded. The sample size was estimated for detecting differences of 1 m/s in PWV between groups. By assuming an alpha risk of 0.05, a beta risk of 0.2 and a standard deviation of 2.12 m/s, 95 subjects per group were needed.

The protocol was approved by the research ethics committee and all patients signed an informed consent form.

The PWV and AI were estimated with the SphyngoCor System. We performed the aortic pulse wave analysis with a sensor on the

radial artery with the patient seated. Using mathematical transformation based on the radial wave, we estimated the central blood pressure and the central and peripheral AI. We evaluated reliability by intraclass correlation ($r=0.974$; 95% confidence interval [CI], 0.936-0.989) in repeated measurements of 22 subjects. Carotid-femoral PWV was determined with the patient lying down, estimating the pulse wave delay at the carotid and femoral level with respect to the electrocardiogram. We defined AASI as $1 - \text{the regression slope for the diastolic blood pressure (DBP) and the systolic blood pressure (SBP) of 24-hour readings, and the Sym-AASI as } 1 - (1 - \text{AASI}) / r$.

We assessed the association between qualitative variables with the χ^2 test, and the difference of the means with ANOVA. We controlled for age with ANCOVA. We analyzed the variables related to the parameters of arterial stiffness with stepwise multiple regression analysis, adjusted for age and sex. PWV, AASI and central augmentation index (cAI) were used as dependent variables. The independent variables were smoking, SBP, DBP, heart rate (HR), body mass index, total cholesterol, low-density lipoprotein cholesterol, high-density lipoprotein cholesterol, triglycerides, baseline glycemia, C-reactive protein and fibrinogen. We used the SPSS/PC+18.0 statistical program.

Table 1 shows the cardiovascular risk factors, average values of the stiffness parameters, and average antihypertensive and lipid-lowering drugs per group. After adjusting for age, the differences between diabetic patients and controls were: PWV, 1.13m/s (95% CI, 0.51-1.74) ($P < .01$); AASI, 0.01 (95% CI, -0.01- 0.03); and cAI, 2.87 (95% CI, -0.82-6.56). Differences between hypertensive