

Image in cardiology

Giant Intrapericardial Cyst Causing Compression of the Left Ventricle



Quiste intrapericárdico gigante con compresión del ventrículo izquierdo

Carlos A. Pardo-Pardo,* Charles Eric Juvin, and Encarnación Gutiérrez-Carretero

Servicio de Cirugía Cardiovascular, Hospital Universitario Virgen del Rocío, Seville, Spain

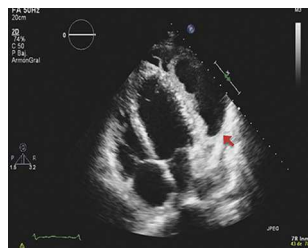


Figure 1.

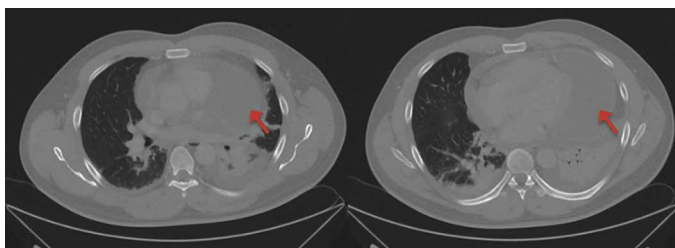


Figure 2.

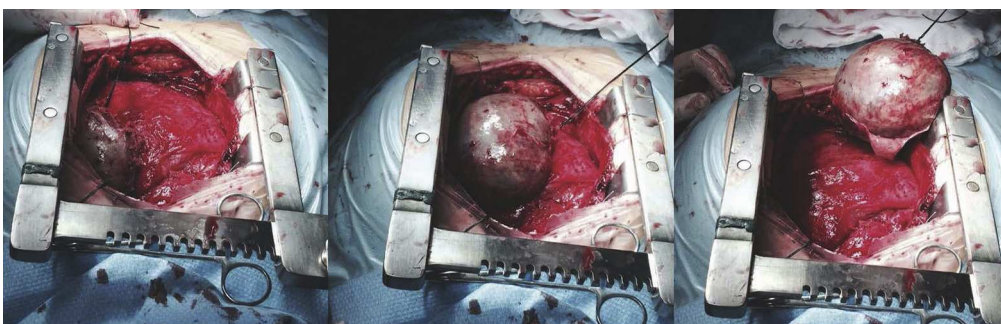


Figure 3.

A 38-year-old male with uneventful past history presented with progressive effort dyspnoea, accompanied by fever and nocturnal sweating for the past 10 days. The physical examination was normal and the additional tests showed: leukocytosis and neutrophilia in the laboratory tests; negative series of blood cultures; transthoracic echocardiography showed an image of a cyst measuring 9×4 cm in diameter, with thick and irregular walls that compressed the lateral wall of the left ventricle (Figure 1, arrow); haemagglutination for hydatid disease was negative. Treatment with broad spectrum antibiotics (levofloxacin and imipenem) was started.

The tomography of the chest showed a large pericardial cyst in the left paracardiac area with a diameter of 9×5 cm, with increased signal uptake in its wall, indicative of superinfection (Figure 2, arrows).

Despite clinical improvement and remission of the fever after 10 days of antibiotic treatment, we decided to operate via median sternotomy, which revealed a large intrapericardial cyst of 10×5 cm in diameter, very closely adherent to the lateral wall of the left ventricle. We managed to release it with careful blunt dissection, with no need for extracorporeal circulation (Figure 3).

The pathological anatomy results diagnosed a pericardial pseudocyst with acute, non-specific chronic inflammation and blood content. However, the sample sent for microbiological analysis gave negative culture results. The patient had a favourable postoperative course and complete remission of symptoms.

* Corresponding author:

E-mail address: drcarlospardo@gmail.com (C.A. Pardo-Pardo).

Available online 2 March 2015