

## AUTHORS' CONTRIBUTIONS

C.A. Vázquez Antona contributed to the study conception and design, data analysis and interpretation, writing the article, and approval of the final article for publication. M.R. Álvarez Macedo contributed to obtaining and interpreting data and review and approval of the final version of the article.

## CONFLICTS OF INTEREST

None.

## APPENDIX. SUPPLEMENTARY DATA

Supplementary data associated with this article can be found in the online version available at <https://doi.org/10.1016/j.rec.2021.01.013>

Marcos Ramón Álvarez Macedo and Clara A. Vázquez Antona\*

Departamento de Ecocardiografía Pediátrica, Instituto Nacional de Cardiología Ignacio Chávez, Mexico City, Mexico

\* Corresponding author:

E-mail address: [vazquezantona@gmail.com](mailto:vazquezantona@gmail.com) (C.A. Vázquez Antona).

Available online 27 de marzo de 2021

## REFERENCES

1. Celermajer DS, Bull MA, Till J, et al. Ebstein's anomaly: presentation and outcome from de fetus to adult. *J Am Coll Cardiol.* 1994;23:170–176.
2. Attie F, Rosas M, Rijlaardam M, et al. The adult with Ebstein's anomaly. Outcome in 72 unoperated patients. *Medicine.* 2000;79:27–36.
3. Sekelj P, Benfey BG. Historic landmarks: Ebstein's anomaly of the tricuspid valve. *Am Heart J.* 1974;88:108–114.
4. Gerlis LM, Ho SY, Sweeney AE, et al. Mitral valve anomalies associated with Ebstein's malformation of the tricuspid valve. *Am J Cardiovasc Pathol.* 1993;4:294–301.
5. Attenhoferjost CH, Connolly HM, O'Leary PW, Warnes CA, Tajik AM, Seward JB. Left heart lesions in patients with Ebstein anomaly. *Mayo Clin Proc.* 2005;80:361–368.
6. Ali LA, Lunardini A, Festa P. Double-orifice mitral valve in Ebstein's anomaly. *Eur Heart J Cardiovasc Imaging.* 2015;16:1410.

<https://doi.org/10.1016/j.rec.2021.01.013>

1885-5857/© 2021 Sociedad Española de Cardiología. Published by Elsevier España, S.L.U. All rights reserved.

## First experience of percutaneous Bi-Pella in Spain



### Primera experiencia con Bi-Pella percutáneo en España

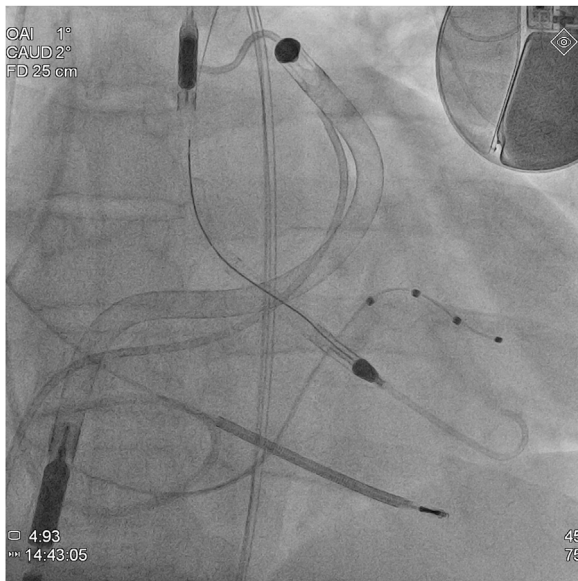
#### To the Editor,

Refractory cardiogenic shock in patients with severe biventricular dysfunction is a therapeutic challenge, as it often requires short-term mechanical circulatory support (ST-MCS) devices as a bridge to heart transplant (HT). Choosing the type of ST-MCS to use is a complex process. Univentricular ST-MCS devices enhance antegrade flow, leading to increased contralateral venous return, which can cause dysfunction of the ventricle due to lack of contractile reserve. Therefore, ideally these patients benefit from biventricular ST-MCS or extracorporeal life support systems such as the venoarterial extracorporeal membrane oxygenator (VA-ECMO), which performs the function of both ventricles simultaneously. However, these devices complicate transplant surgery and clinical course. Until now, central biventricular ST-MCS has been used most commonly. The cannulas are placed directly into the heart chambers or great vessels, which means that further surgery for heart transplant can prolong graft ischemia time and encourage bleeding. Moreover, VA-ECMO is usually inserted percutaneously into central vessels and, therefore, is less invasive but entails risks, such as increased afterload of the left ventricle (LV), complications related to vascular accesses (eg, limb ischemia), and high red blood cell and platelet destruction, which must be replaced with transfusions, thereby promoting cytotoxic antibody production. The recent development of percutaneous ST-MCS for the right ventricle (RV) combined with percutaneous ST-MCS for the LV offers an alternative. We describe the first case in Spain of percutaneous implantation of the biventricular Impella (Bi-Pella) as a bridge to HT, using the Impella CP and Impella RP catheters

(Abiomed Inc, United States) to partially carry out LV and RV function, respectively.

A 47-year-old man with familial dilated cardiomyopathy, severe biventricular dysfunction, and severe mitral and tricuspid regurgitation listed for HT was admitted to the Acute Cardiology Care Unit for cardiogenic shock, systemic congestion, and stage 3 acute kidney injury (AKIN). Due to poor tolerance of dobutamine therapy (sustained ventricular tachycardia) and progressive impairment of kidney function (INTERMACS 2), ST-MCS was considered necessary. In the preliminary assessment, echocardiographic predictors (tricuspid annular plane systolic excursion [TAPSE], 10 mm; S', 5 cm/s; RV/LV ratio, 0.9; shortening fraction, 25%) and hemodynamic predictors (filling pressure ratio, 1.6; pulmonary artery pulsatility index, 0.8; RV stroke work index, 0.3 mmHg/L/m<sup>2</sup>) indicated a high risk of RV dysfunction and, therefore, percutaneous biventricular ST-MCS was performed as a bridge to HT. The devices were implanted in the catheterization lab under conscious sedation and analgesia. The Impella CP device was inserted through the left femoral artery (14 Fr) and the Impella RP, through the right femoral vein (23 Fr) (figure 1). Assist was initially set to levels P8 and P6, which provided flow at 3.4 and 3.1 L/min, respectively. The patient gave written consent for publication of his case and the respective images in a scientific journal, with a commitment to avoid disclosing identifying information.

Following implantation, the patient's clinical progress was favorable (table 1), with immediate hemodynamic improvement, reduced filling volumes and pressures of both ventricles, and improved tissue perfusion and kidney function. This allowed inotropic support to be reduced with no new arrhythmic events. ST-MCS was maintained for 5 days until HT, which was successful, with early extubation and withdrawal of vasoactive support (24 hours) and a subsequent 11-day stay in the postoperative cardiology care unit and 30-day hospital stay. Several complications emerged during the ST-MCS period. First, initial bleeding at



**Figure 1.** Fluoroscopy image after implantation of both Impella catheters (Bi-Pella), showing the Impella CP catheter inserted from the aorta into the left ventricle and the Impella RP catheter crossing the right ventricle from the inferior vena cava to the pulmonary artery.

the venous access site (hemoglobin loss of 2.2 mg/dL) in the context of thrombocytopenia (platelets,  $102 \times 10^3/\mu\text{L}$ ) and anti-coagulant therapy required local suture. Second, hemolytic anemia was treated with periodic transfusions (4 units of packed red cells) and reduction of left-sided MCS to level P6 on the fourth day, with

no significant hemodynamic repercussions. Last, progressive thrombocytopenia (nadir  $46 \times 10^3$  platelets/ $\mu\text{L}$ ) with no related hemorrhage required a single unit of platelet concentrate to optimize hemostasis before transplantation.

Three aspects of the treatment were more complex than with the univentricular Impella device. The first was coagulation control: unfractionated heparin was administered to obtain an activated clotting time (ACT) of 160 to 180 s. All anticoagulation received by the patient was provided by assist purge flows plus supplemental systemic heparin to achieve this target. The purge fluids were set to 10 IU/mL, for amounts of 110 IU/h through the Impella CP (flow rate, 11 mL/h) and 140 IU/h through the Impella RP (flow rate, 14 mL/h). Supplemental unfractionated heparin was started when the ACT dropped from 250 s. To prevent excessively high doses (which could cause anemia, thrombocytopenia, access-site bleeding, and kidney failure), the low setting (10 IU/kg/h) was used first, ie, 600 IU/h for this patient (60 kg). Because the devices supplied 250 IU/h, a dose of 350 IU/h was prescribed at the beginning and then adjusted to the ACT test results. The second complex issue encountered was the need for invasive hemodynamic monitoring: the Swan-Ganz catheter made it possible to optimize filling pressures. Cardiac output measurement by thermodilution was not reliable because, in addition to severe tricuspid regurgitation, the Impella RP catheter partially bypasses the pulmonary artery and, consequently, the Fick method was used for the calculation. Based on experience with ECMO, an alternative for patients with pulsatility could be pulse waveform contour systems, which are not useful for calculating absolute cardiac output but can be used to monitor trends.<sup>1</sup> Last, this patient exhibited higher levels of hemolysis and thrombocytopenia than usually seen.

In conclusion, this strategy offers advantages over surgical implantations and VA-ECMO,<sup>2</sup> most notably, it is a minimally

**Table 1**  
Hemodynamic, echocardiographic, and laboratory parameters

	Preimplantation	Postimplantation, immediate	Postimplantation, 24 h	Pretransplantation, day 5
<i>Circulatory assist</i>				
Impella CP/RP P level		P8/P6	P8/P6	P6/P6
Impella CP/RP flow, L/min		3.4/3.1	3.5/3.1	2.9/3.1
Dobutamine, $\mu\text{g}/\text{kg}/\text{min}$	3.5	3.5	2.2	2
<i>Hemodynamic parameters</i>				
Mean arterial pressure, mmHg	58	65	72	70
Fick cardiac output, L/min/m <sup>2</sup>	2.1	2.7	2.6	2.4
Central venous pressure, mmHg	22	19	17	15
Pulmonary capillary pressure, mmHg	14	13	13	13
Mean pulmonary pressure, mmHg	15	18	23	28
<i>Echocardiographic parameters</i>				
LV end-diastolic diameter, mm	62	61	61	61
RV end-systolic diameter, mm	56	60	51	53
<i>Laboratory parameters</i>				
Lactate, mmol/L	2.3	1.2	0.8	0.6
SvO <sub>2</sub> , %	56	57	60	63
Creatinine, mg/dL	3.1	2.7	1.8	1.6
Urea, mg/dL	172	134	123	73
Sodium, mEq/L	130	129	133	140
AST, IU/L	18	24	43	54
ALT, IU/L	15	12	11	19
GGT, IU/L	229	158	166	90
ALP, IU/L	138	97	116	63

ALP, alkaline phosphatase; ALT, alanine aminotransferase; AST, aspartate aminotransferase; GGT, gamma-glutamyl transferase; LV, left ventricle; RV, right ventricle; SvO<sub>2</sub>, mixed venous oxygen saturation.

invasive procedure performed under conscious sedation and has a lower rate of vascular complications (smaller introducers), lower need for transfusions than with VA-ECMO, and lower volume needed to resuscitate the patient. However, extrapolation of these conclusions is limited, as the experience described concerns a single patient.

## FUNDING

No institution has funded this research.

## AUTHORS' CONTRIBUTIONS

E. Puerto conceived this paper and drafted the manuscript. R. Martín-Asenjo collaborated in the manuscript text and performed a critical review of the text. R. Maruri, L. Domínguez-Pérez, H. Bueno, and F. Arribas-Ynsaurriaga performed a critical review of the text. All authors approved the final version of the text.

## CONFLICTS OF INTEREST

None of the authors report any conflicts of interest related to the work submitted.

## Acknowledgments

To Dr María Dolores García-Cosío and Dr Juan Delgado (Transplant Unit) and to Dr María Teresa Velázquez and Dr Agustín Albarrán (Interventional Cardiology) for their assistance with the patient's care.

Elena Puerto,<sup>a,\*</sup> Roberto Martín-Asenjo,<sup>a</sup> Ramón Maruri,<sup>a</sup> Laura Domínguez-Pérez,<sup>a</sup> Fernando Arribas Ynsaurriaga,<sup>a,b,c</sup> and Héctor Bueno<sup>a,b,c,d</sup>

<sup>a</sup>Servicio de Cardiología, Hospital Universitario 12 de Octubre, Instituto de Investigación Sanitaria Hospital 12 de Octubre (imas12), Madrid, Spain

<sup>b</sup>Centro de Investigación Biomédica en Red de Enfermedades Cardiovasculares (CIBERCV), Spain

<sup>c</sup>Facultad de Medicina, Universidad Complutense de Madrid, Madrid, Spain

<sup>d</sup>Centro Nacional de Investigaciones Cardiovasculares (CNIC), Madrid, Spain

\* Autor para correspondencia:

E-mail address: [elenapuerto.garcia@salud.madrid.org](mailto:elenapuerto.garcia@salud.madrid.org) (E. Puerto).

Available online 13 de abril de 2021

## REFERENCES

1. Su Y, Liu K, Zheng JL, et al. Hemodynamic monitoring in patients with venoarterial extracorporeal membrane oxygenation. *Ann Transl Med.* 2020;8:792.
2. Varian K, Xu WD, Lin W, et al. Minimally invasive biventricular mechanical circulatory support with Impella pumps as a bridge to heart transplantation. *ESC Heart Failure.* 2019;6:552–554.

<https://doi.org/10.1016/j.rec.2021.01.015>

1885-5857/© 2021 Sociedad Española de Cardiología. Published by Elsevier España, S.L.U. All rights reserved.

## Transcatheter closure of coronary artery fistula draining into left ventricle: a long-term study



### Evolución a largo plazo de fístulas coronarias que drenan al ventrículo izquierdo cerradas percutáneamente

#### To the Editor,

Coronary artery fistula draining into the left ventricle (CAF-LV) is a rare congenital heart disease, which increases the risk of myocardial ischemia, endocarditis, rupture of coronary artery aneurysm and so on.<sup>1,2</sup> After surgical repair, residual shunt is not uncommon (17%).<sup>3</sup> In comparison, transcatheter closure might become an alternative treatment, and its feasibility and effectiveness have been suggested in previous publications.<sup>4</sup> However, group research and long-term follow-up are still absent after transcatheter closure of CAF-LV. This study was carried out to investigate its long-term outcome.

From January 2011 to September 2020, a total of 21 consecutive patients (15 men, 6 women, age  $34.14 \pm 15.13$  years) with CAF-LV were included according to guidelines on the management of congenital heart disease (with symptoms of a typical murmur),<sup>2</sup> and transcatheter closure was performed successfully in all patients. The origin and drainage of CAF-LV were determined arteriographically, and the appropriate device was selected based on the minimum size and morphology of CAF-LV (figure 1A,B). Dual-antiplatelet therapy was employed in CAF-LV patients after transcatheter closure. Anticoagulant and antiplatelet therapy was selected by CAF-LV patients with a giant coronary artery aneurysm. Follow-up was

performed by X-rays, 12-lead electrocardiogram and transthoracic echocardiography (TTE) records at 1 day, 1 month, and serially at 2- to 6-month intervals. The residual shunt measured by TTE was classified as follows: trivial (1 mm), mild (1-2 mm), moderate (2-4 mm), or large (4 mm). Clinical characteristics are shown in table 1. Among 21 patients, CAF-LV originated from the right coronary artery in 15 patients (71.43%), and there was 1 “recanalized” CAF-LV after surgical repair (figure 1C,D). Dilatation of the feeding coronary artery was observed in 20 patients (95.24%), and “giant” coronary artery aneurysm was identified in 3 patients. In all, 37 devices were deployed, and the residual shunt was detected in 3 patients (trivial in 2 and mild in 1). After transcatheter closure, 10 patients experienced nonspecific ST-T wave changes. During the follow-up period (median, 2.83 years), there was a significant decrease in left ventricular end-diastolic dimension ( $52.24 \pm 7.48$  mm vs  $56.86 \pm 11.39$  mm,  $P = .004$ ). Six months after the intervention, 1 patient with giant coronary artery had a myocardial infarction (4.76%). In the remaining patients, no complications occurred during long-term follow-up.

To the best of our knowledge, this is the first group research on transcatheter closure of CAF-LV. Our findings suggest that the long-term outcome was satisfactory in patients without giant coronary artery aneurysm, and that postoperative cardiac remodeling was favorable in most patients. In this study, the effectiveness of transcatheter closure was further confirmed, and there were 3 patients with trivial-mild residual shunt. During the long-term follow-up, myocardial infarction occurred in 1 of 3 patients with giant coronary artery aneurysm, which is consistent with a previous study.<sup>5</sup> In CAF-LV patients with giant coronary artery