

Image in cardiology

 ^{18}F -FDG Pitfall due to Atrial Appendages UptakeFalso positivo ^{18}F -FDG por captación en orejuelas auriculares

Cristina Buján-Lloret, Pablo Antonio de la Riva-Pérez, and Francisco Javier García-Gómez*

Servicio de Medicina Nuclear, Hospital Universitario Virgen Macarena, Sevilla, Spain

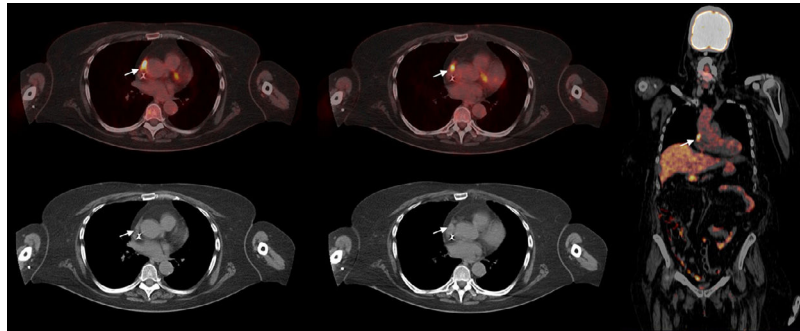


Figure 1.

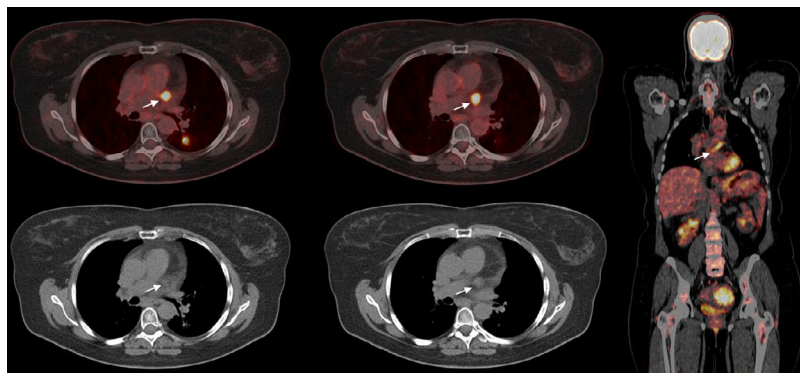


Figure 2.

Although the cardiac anatomy is well known, some of the cardiac structures are not easily recognized on imaging scans. That is the case of the atrial appendages, which are trabecularized structures with significant clinical implications. Both the right and left atrial appendages are remnants of the primary atria, which are formed at the fourth week of embryogenesis.

^{18}F -Fluorodeoxyglucose positron emission tomography uptake by atrial appendages is an extremely unusual finding (estimated incidence of 0.42% for the right atrial appendage) that seems to be related to atrial fibrillation, inflammatory activity, or overload physiology. Only a few cases have been reported in the literature revealing how physiologically increased uptake at the right atrial appendage, specifically at the crista terminalis, can pose a diagnostic challenge. In our short series, right atrial appendage uptake was observed in a patient with a history of diffuse large B-cell lymphoma and stroke in the middle cerebral artery territory secondary to thrombotic thrombocytopenic purpura (Figure 1, arrows). Similarly, left atrial appendage uptake with a tendency to linearity was observed in a patient who had undergone a left hemicolectomy with end-to-end anastomosis because of colon adenocarcinoma and subsequent chemoradiotherapy with radical intent for nonmicrocytic lung carcinoma (Figure 2, arrows). This increased uptake could be influenced by the history of chest radiotherapy.

Since increased uptake can mimic hypermetabolic mediastinal nodal disease, its recognition by careful correlation with the computed tomography image is mandatory to avoid erroneous diagnosis of cardiac mass or mediastinal involvement, especially in patients monitored for lung cancer or lymphoproliferative syndromes.

* Corresponding author:
E-mail address: javier191185@gmail.com (F.J. García-Gómez).
Available online 7 March 2018