

Experimental Study of the so Called Left Ventricular Isovolumic Relaxation Phase

Juan A. Cosín Aguilar, Amparo Hernández Martínez, M. Teresa Tuzón Segarra, Jaime Agüero Ramón-Llin, and Francisco Torrent-Guasp (†)

Unidad de Cardiología Experimental, Centro de Investigación, Hospital Universitario La Fe, Valencia, Spain

Introduction and objectives. Left ventricular filling begins in the ventricular isovolumic relaxation phase. According to the Torrent-Guasp myocardial band theory, this phase results from the contraction of the final portion of the myocardial band: the ascending segment of the apical loop. The objectives were to study the myocardial mechanisms influencing transmitral flow during early diastole and to determine whether the rapid ventricular filling phase involves contraction or relaxation.

Methods. An experimental *in vivo* pig model was used. Regional contractility in 3 segments of the myocardial band was assessed using piezoelectric crystals and mitral flow was measured by echo-Doppler ultrasonography at baseline and after akinesia had been induced in the ascending segment by 2.5% formaldehyde infusion. Changes in intracavitary pressure in the left ventricle and left atrium and flow alterations in the aortic root were recorded. The start of the isovolumic relaxation phase was identified using the time at which the ejection of blood ceases, as indicated by aortic flow measurements.

Results. During the left ventricular isovolumetric relaxation phase, the ascending segment of the apical loop was undergoing contraction. The infusion of formaldehyde into this segment affected the extent to which the intraventricular pressure could decrease, prolonged the isovolumic relaxation phase and resulted in a lower minimum pressure. It also produced a significant decrease in transmitral flow velocity in early diastole and an increase at end-diastole.

Conclusions. The rapid ventricular filling phase is characterized by contraction.

Key words: *Diastole. Contractility. Heart failure.*

Estudio experimental de la llamada fase de relajación isovolumétrica del ventrículo izquierdo

Introducción y objetivos. El llenado del ventrículo izquierdo se inicia con la fase de relajación isovolumétrica ventricular. En la teoría de la banda miocárdica de Torrent-Guasp, esta fase se produce como consecuencia de la contracción de la porción final de la banda muscular, el segmento ascendente de la lazada apexiana. El objetivo es estudiar los mecanismos miocárdicos involucrados en el flujo transmitral durante la protodiástole y discernir si la fase de llenado rápido ventricular es un proceso de relajación o de contracción.

Métodos. Modelo experimental *in vivo* en cerdos. Se estudia la contractilidad regional con cristales piezoeléctricos en 3 segmentos de la banda miocárdica y el flujo transmitral con eco-Doppler, en situación basal y tras la producción de akinesia del segmento ascendente mediante la infiltración con formaldehído al 2,5%. Se registran las curvas de presión intracavitarias del ventrículo izquierdo y la aurícula izquierda y el flujo en la raíz aórtica. Para determinar el inicio de la fase de relajación isovolumétrica, hemos identificado el final de la expulsión de sangre en la curva del flujo aórtico.

Resultados. Durante la fase de relajación isovolumétrica del ventrículo izquierdo, el segmento ascendente de la lazada apexiana está contrayéndose. La infiltración con formaldehído de este segmento afecta a la capacidad de reducir la presión intraventricular, y la duración de la fase de relajación isovolumétrica se prolonga y se alcanza una menor presión mínima. Se produce un descenso significativo en las velocidades del flujo transmitral de la protodiástole y un incremento en la telediástole.

Conclusiones. La fase de llenado rápido ventricular es un proceso de contracción.

Palabras clave: *Diástole. Contractilidad. Insuficiencia cardiaca.*

This study has been financed by grant no. 99/1002 from the Spanish Fondo de Investigaciones Sanitarias (FIS).

Correspondence: Dr. JA. Cosín Aguilar.
Unidad de Cardiología Experimental. Centro de Investigación. Hospital Universitario La Fe.
Avda. Campanar, 21. 46009 Valencia. España.
E-mail: hernandez_amp@gva.es

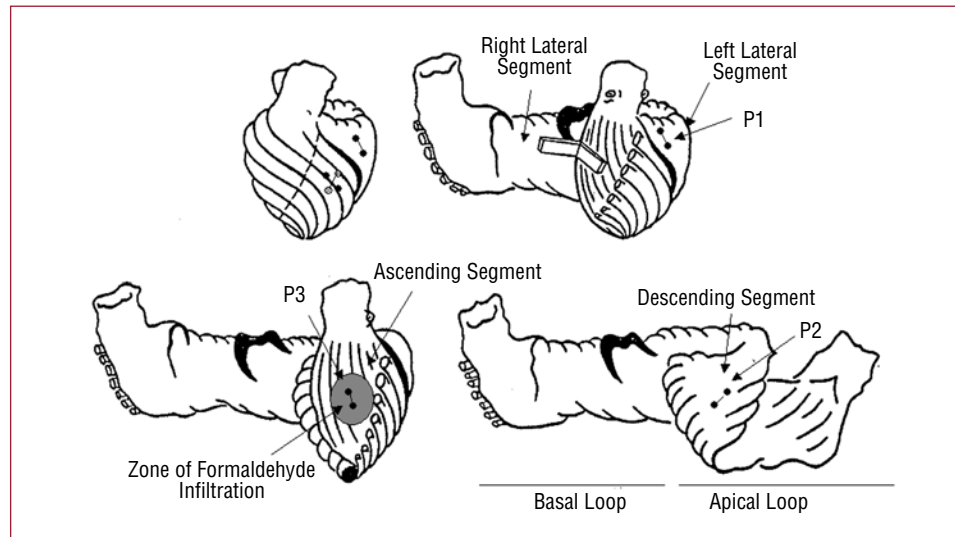
Received July 15, 2008.

Accepted for publication January 14, 2009.

INTRODUCTION

According to Torrent-Guasp and other authors,¹⁻⁶ the ventricular myocardium consists of a continuous band of muscle that extends from the pulmonary

Figure 1. Diagrams showing the segments of the myocardial band (Torrent-Guasp) and the position of the pairs of crystals implanted into the myocardium, represented as small circles connected by a line. In the upper left diagram, the crystals corresponding to subendocardial P2 (in the descending segment of the apical loop) are represented by open circles.



artery root to the aortic root, forming a helical structure with 2 spirals and delimiting the 2 ventricular cavities. This myocardial band would be composed of the “basal loop” and the “apical loop.” The basal loop is predominantly horizontal and divides into left and right segments; the apical loop is predominantly vertical and consists of the descending segment and the ascending segment (Figure 1). Ejection would be produced by the successive contraction of the right basal and left basal segments, which leads to a narrowing of the base of the heart, followed by the contraction of the descending apical segment. This, in turn, produces shortening of the longitudinal dimensions of the heart, bringing the base closer to the apex. Ventricular filling would begin with the contraction of the ascending apical segment, accompanied by longitudinal lengthening and followed by the relaxation of the ventricular walls. During the cardiac cycle, the apex remains stationary, while the base moves downward, the main cause of the longitudinal shortening and of the ejection of the blood, followed by another upward movement to which the suction of the blood from left atrium is attributed.⁷⁻⁹

In the classical doctrine, left ventricular filling begins with ventricular relaxation, an active energy-consuming process that reduces the intraventricular pressure to less than that corresponding to left atrium. The cross between pressures causes the opening of the mitral valve and the initiation of early rapid filling. The factors determining this mechanism are considered to be elastic recovery, which involves different components such as the elastin content in the collagen of the extracellular matrix,¹⁰ or the protein titin, which restores force to the sarcomere for its recovery after the deformation produced during systole,¹¹ and the relaxation of the

myocardial wall. Hemodynamically, this involves 80% of the filling volume and is produced with nearly no contribution on the part of atrial factors.¹⁰

What is difficult to imagine and to demonstrate is the fact that the isovolumic relaxation phase and the subsequent rapid filling are a consequence of the contraction of the final portion of the myocardial band. However, this would explain why whenever systolic dysfunction develops, it is accompanied by diastolic dysfunction, why the index T (the time constant of the pressure fall during the isovolumic contraction phase) depends on the contractility, and is improved by isoproterenol,¹² and even why diastolic dysfunction with normal or “preserved” systolic function is an entity for which the significance, identification and treatment remain unclear.¹³⁻¹⁷

The experimental studies that we present here have been carried out for the purpose of determining the myocardial mechanisms involved in early diastolic transmitral flow. Specifically, we wanted to know whether the phase of rapid ventricular filling is a process of relaxation or contraction.¹⁸ To address this question, we will examine whether the contraction of the ascending segment of the apical loop coincides temporally with the so-called left ventricular isovolumic relaxation phase and whether the induction of hypokinesia or akinesia limited to that segment has a negative effect on early transmitral flow, the rate of the intraventricular pressure fall during the isovolumic phase and the minimum pressure reached in left ventricle.

METHODS

We studied 12 pigs of both sexes with a mean weight of 28.2 (5.1) kg. They had been bred in

the Veterinary Unit of the Research Center of our hospital. The experiments were performed in accordance with the Spanish and European guidelines for the "Protection of animals used for experimental and other scientific purposes" (Royal Decree 223/1988 and Royal Decree 1201/2005). The surgical procedures were carried out by investigators who possessed the European certificate of training in animal experimentation (Royal Decree 1201/2005).

Preparation of the Experiments

On the day of the experiment, the animals are preanesthetized and sedated in their stalls by intramuscular injection of midazolam (0.5 mg/kg body weight) and ketamine (10 mg/kg body weight). Anesthesia is induced in the experimental operating room by the intravenous route (thiopental, 10 mg/kg body weight), and endotracheal intubation and catheterization of the external jugular vein are carried out. Anesthesia is maintained with sevoflurane (2.5%) in a mixture of 40% oxygen and 60% nitrous oxide, delivered by means of a ventilator (Temel VT3, Spain). Analgesia and relaxation are initiated with vecuronium bromide (0.08 mg/kg body weight) and morphine hydrochloride (0.7 mg/kg body weight) and are maintained with vecuronium bromide (0.08 mg/kg body weight) and 20 mg of morphine hydrochloride in 50 mL of serum in an infusion pump at a rate of 12 mL/h. Median sternotomy is performed, followed by pericardiectomy. The mechanical ventilation is adjusted to a rate between 16 and 20 breaths per minute and to a gas flow of approximately 5 L/min, depending on the oximetry in blood. The peripheral electrocardiogram, blood pH, blood gases, hematocrit, and rectal temperature are monitored throughout the entire experiment. The temperature is maintained with an electric blanket.

Segmental Function

Three pairs of ultrasonic microcrystals (Biopac Systems, Santa Barbara, California, USA) are implanted into the myocardium: one pair in the mesocardium (at a depth of approximately 4 to 5 mm) of the lateral aspect of left ventricle corresponding to the basal loop, left lateral segment (P1), following the direction of the longitudinal axis of the heart; another pair in the subendocardium of the anterior aspect of the middle third of left ventricle, between the first and second diagonal branches of anterior descending artery and tangential to it, a zone corresponding to the descending segment of the apical loop (P2); and, finally, another pair in the subepicardium (at a depth of 1 to 2 mm) of

the anterior aspect of left ventricle, between the first and second diagonal branches of the anterior descending artery and parallel to the anterior descending artery toward the aortic root, in a zone corresponding to the ascending segment of the apical loop (P3) (Figure 1). The pairs of microcrystals are aligned following the direction of the muscle fibers of the zone in which they are placed. They are separated by approximately 2 cm. The P2 pairs are anchored in the subendocardium by means of transseptal puncture, reaching the ventricular cavity and drawing back in order to deposit them in the subendocardium, forming a cross with the P3 pairs in the subepicardium. The pairs of crystals enable us to know the relative displacement of the 2 points in the myocardium over which they are secured and, thus, the dynamic properties of the segment contained between them. The acquisition of the regional myocardial contractility curves is achieved with the Sonometrics Corporation Digital Ultrasonic Measurement System (London, Ontario, Canada).

Intracavitary Pressures

A catheter is inserted through the left ventricular free wall for monitoring left ventricular pressure and another is inserted through the auricle to measure left atrial pressure; both catheters are connected to pressure transducers (Transpac IV, USA).

Aortic Flow

The aortic root is dissected and an electromagnetic flow meter is placed (Transonic Systems, New York, United States).

Transmitral Flow

A Doppler echocardiogram was carried out (Interspec XL Doppler, USA) with a 5-MHz probe, directly over the epicardium, to record the transmitral flow from an apical four-chamber view, first in baseline conditions and then after injection of diluted formaldehyde into the myocardial wall.

Induction of Segmental Akinesia

This involves injections of formaldehyde¹⁹ diluted to 2.5%, using an atraumatic needle, into the subepicardium (at a depth of 1 to 2 mm) of the ascending segment of the apical loop, where the P2 pairs of crystals are situated. A maximum of 0.8 mL of the indicated dilution are injected, distributed among 3 and 4 injections. After each injection, the effect produced on the fraction of segment

TABLE 1. Hemodynamic Parameters

	Block of the Ascending Segment, Apical Loop	
	Baseline	Formaldehyde
Aortic flow, mean (SD), mL/min	78.7 (17.9)	81.7 (19.3)
LVSP _{max} , mean (SD), mm Hg	76.1 (9.7)	72.8 (9.1)
LAP, mean (SD), mm Hg	5.9 (0.9)	8.8 (1.2) ^a
LVPmin, mean (SD), mm Hg	-0.16 (2.6)	1.2 (3.8) ^a
LVEDP, mean (SD), mm Hg	6.8 (3)	10.2 (3.3)
Isovolumic relaxation time, mean (SD), ms	40.8 (7.4)	106 (24.9) ^b
Aortic closure-P1 contraction time, mean (SD), ms	-17.8 (27.9)	-8.9 (42.03)
Aortic closure-P2 contraction time, mean (SD), ms	10.6 (44.6)	-18.9 (47.3)
Aortic closure-P3 contraction time, mean (SD), ms	72.7 (26.3)	-56.1 (42.9) ^c

Aortic flow indicates mean flow in aortic root; aortic valve closure-P1, P2, and P3 contraction time, time elapsed between aortic valve closure, and the point of maximum contraction of the myocardial segments; isovolumic relaxation time, time elapsed between aortic valve closure, and the point corresponding to a pressure surpassing the left ventricular end-diastolic pressure by 10 mm Hg; LAP, left atrial pressure; LVEDP, left ventricular end-diastolic pressure; LVPmin, minimum left ventricular pressure; LVSPmax, maximum left ventricular systolic pressure; SD, standard deviation.

^a $P < .05$.

^b $P < .01$.

^c $P < .001$

shortening is monitored until akinesia or dyskinesia is achieved in the given segment.

Data Collection

The records corresponding to: ECG (I, II, or III), left ventricular pressure in mm Hg, left atrial pressure in mm Hg, aortic flow (mL/min), and sonometric data of the 3 myocardial band segments indicated are digitized and stored in an electronic memory (BIOPAC Systems Inc, Santa Barbara, California, United States). The transmitral flow velocity curves and values obtained using Doppler echocardiography (m/s) are stored separately.

Once the experiments are completed, the animals are sacrificed under anesthesia by means an intravenous injection of potassium chloride. After removal of the anatomical structure (the heart), the anatomical site of the 3 pairs of crystals is verified, the anterior left ventricular wall is dissected, following the route of the interventricular artery, and the depth at which each crystal is implanted is verified, as is the region of the muscle infiltrated with formaldehyde.

Parameters Analyzed

In the Doppler echocardiogram, we study the maximal transmitral flow velocities at the beginning (E) and end (A) of diastole and the E/A ratio. The intracavitary pressure curves provide the maximum left ventricular systolic pressure, the minimum left ventricular pressure, the left ventricular end-diastolic pressure (LVEDP), the time elapsed from aortic valve closure until the intraventricular pressure surpasses the end-diastolic pressure by 10 mm Hg,

which corresponds to the isovolumic relaxation time¹²; at this point, we can be sure that this is the isovolumic phase with the mitral valve still closed. The segmental function curves reveal the shortening fraction, and the aortic flow curves show the mean aortic flow and the temporal relationship between the end of the contraction of each of the three segments (P1, P2, and P3) and the suspension of aortic flow (time aortic closure-contraction P1, P2, P3). All these parameters are analyzed before and after the injection of formaldehyde into the ascending segment. The shortening fraction is measured after each formaldehyde injection until an adequate change in the injected segment is verified.

Analysis of the Results

The variables studied are continuous, and the results are expressed as the mean plus or minus the standard deviation. The changes in the variables following the blockade with formaldehyde with respect to baseline conditions have been studied. The comparison of the means was carried out using Student *t* test for paired samples or the Mann-Whitney nonparametric test for data that did not show a normal distribution. A *P* value less than .05 was considered significant. The SPSS statistical package (version 9.0) was employed.

RESULTS

Hemodynamic Changes (Table 1)

The injection of formaldehyde significantly prolongs the time required to surpass the left ventricular end-diastolic pressure by 10 mm Hg

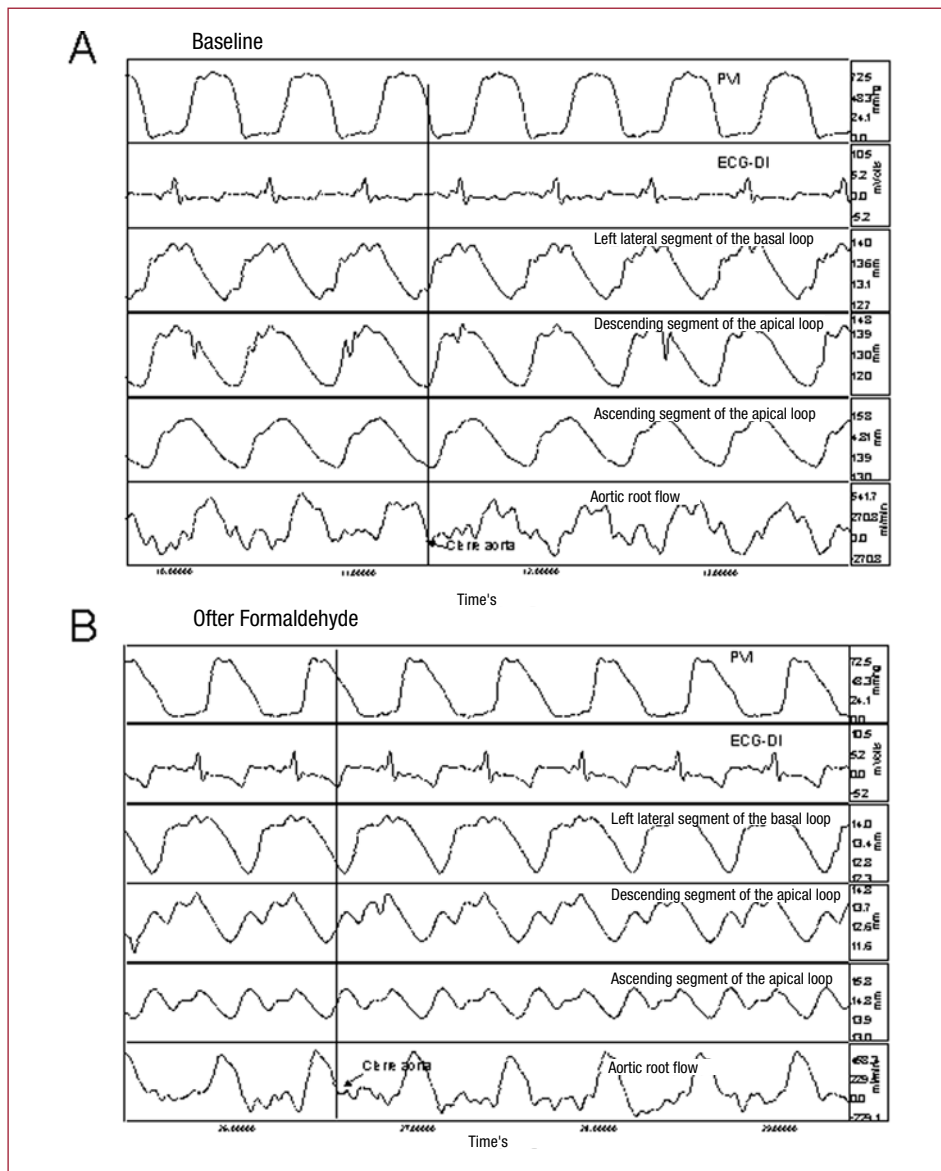


Figure 2. Recording of left ventricular pressure (PVI); electrocardiogram (ECG-DI); segmental contractility in left lateral segment of the basal loop, descending segment of the apical loop and ascending segment of the apical loop; and aortic root flow under baseline conditions (A) and after formaldehyde injection (B). The arrows indicate the points corresponding to aortic valve closure. The changes induced by the injection of formaldehyde are described in the text.

following aortic valve closure, increases the minimum left ventricular pressure that is reached in early diastole, changing from negative to positive pressures, raises—although not in a very significant way—the LVEDP and significantly increments the mean atrial pressure. There are no immediate significant changes in the aortic flow or in left ventricular pressure during systole (Figure 2).

End of Myocardial Contraction and Initiation of Diastole

In order to determine the initiation of the isovolumic relaxation phase, we identified the time at which the ejection of blood ceases in the aortic flow curve and the segmental contraction phase in the corresponding sonometric curves (Figure 2).

In all experiments, the ascending segment (P3) was in contraction after the aortic flow ceased and the aortic valve closed. The contraction of the last myocardial segment ended in a mean time of 72.7 (26.3) ms after closure of the aortic valve, coinciding with the so called isovolumic relaxation phase in early diastole (Figure 2), whereas the descending segment (P2) reached maximum contraction 10.6 (44.6) ms after aortic valve closure, and the end of the contraction of the P1 segment (basal loop) preceded the closure of the aortic valve (Table 1).

Transmitral Flow

Table 2 shows the effect produced in the shortening fraction of the monitored segment by the injection of formaldehyde into the ascending segment of

TABLE 2. Parameters of Regional Contractility and Transmitral Flow

	Block of the Ascending Segment, Apical Loop	
	Baseline	Formaldehyde
SF P1, mean (SD), %	8.9 (3.2)	8.4 (2.6)
SF P2, mean (SD), %	11.6 (5.9)	4.4 (4.2) ^a
SF P3, mean (SD), %	9.4 (3.2)	-0.4 (4.5) ^b
E wave, mean (SD), m/s	0.42 (0.1)	0.3 (0.07) ^b
A wave, mean (SD), m/s	0.32 (0.08)	0.39 (0.08) ^b
E/A, mean (SD)	1.39 (0.3)	0.78 (0.2) ^b

E/A indicates ratio between the E and A waves of transmitral flow; P1, left lateral segment of the basal loop; P2, descending segment of the apical loop; P3, ascending segment of the apical loop; SD, standard deviation; SF, segment shortening fraction.

^a $P < .01$.

^b $P < .001$.

the apical loop. There is a decrease to levels of dyskinesia (according to protocol) in the injected segment (P3, ascending segment) and hypokinesia in the neighboring segment, the descending segment (P2) of the apical loop. The zones corresponding to the left lateral segment of the basal loop (P1) are not altered. In parallel, the transmitral flow is affected, with changes in the ventricular filling rates in early diastole and in the E/A ratio; the E wave decreased as the A wave increased, the E/A ratio being significantly reduced ($P < .01$) (Table 2). These changes occurred immediately after infiltration of the myocardium and, depending on the extension, continued until a maximum was reached, after which there were no additional increases with subsequent injections. In parallel, there was an evident change in the transmitral flow curve in the Doppler echocardiogram (Figure 3).

DISCUSSION

When the ventricle ceases to eject the blood, systole ends and diastole commences. From this moment, and until the mitral valve opens, there is a period of time during which both valves are closed, which is known as the isovolumic relaxation phase. During this phase, the intraventricular pressure falls at a constant rate¹² and leads to transmural and transvalvular pressure gradients towards the interior of the chamber. A suction effect is produced, to which the rapidity of early ventricular filling is immediately attributed and the total or partial loss of which is a cause of left ventricular diastolic dysfunction, the pathophysiological substrate of heart failure with preserved systolic function.

In clinical practice,^{16,20,21} the diagnosis of heart failure due to diastolic dysfunction depends on 3 conditions: the presence of signs or symptoms of heart failure, a normal or slightly decreased left

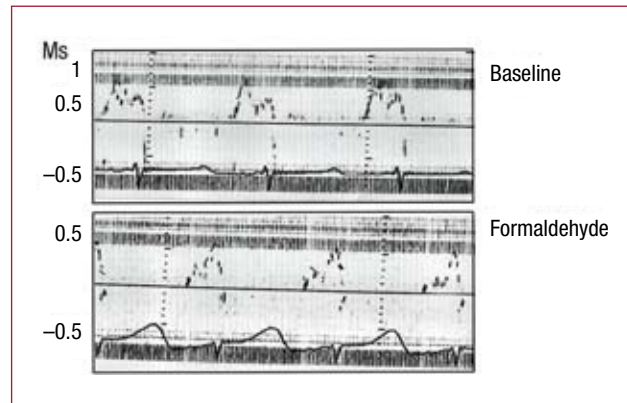


Figure 3. Immediate changes in the transmitral flow rate, measured by Doppler echocardiography, secondary to infiltration with 2.5% formaldehyde in the ascending segment of the apical loop. Figure corrected for reproduction.

ventricular ejection fraction, and an increased left ventricular filling pressure. The latter factor has an impact and can be measured in the left ventricular filling curve of the Doppler echocardiogram, in the prolongation of the isovolumic relaxation period, in the decrease in the early diastolic velocity (E), in the prolongation of the deceleration time, in the increase in the end-diastolic velocity (A), and in the reduction of the E/A ratio.

Ventricular filling, which identifies the diastolic time, was attributed to atrial contraction until 1954.^{3,4} It is now accepted that the left ventricle participates actively with the suction force that we referred to above. It is an active process^{22,23} that consumes energy and involves Ca^{2+} exchange. A number of authors consider diastole to be a consequence of the elongation of the myocardial fibers of the walls of a closed chamber. It would be a phenomenon linked to muscle relaxation (separation of the myosin filaments) and to elastic recovery of the fibers, in which the elastin contained in a collagen network that makes up the extrafibrillar connective tissue intervenes, as well as the protein titin as an element of the recovery of the sarcomere deformed during systole.^{10,11} The ventricular mechanical activation during diastole is heterogeneous, with subendocardial-subepicardial relaxation gradients at the beginning of diastole.^{22,24,25}

In the theory of Torrent-Guasp, it is a systolic phenomenon linked to muscle contraction.^{23,26} The ejection of the blood is a consequence of the contraction of the descending segment of the apical loop; its contraction “screws” the base over the apex, drawing the 2 parts nearer. The next and final segment of the muscle band is the ascending segment of the apical loop, which covers the descending segment, forming the epicardium of the anterior aspect as far as the aortic root, and which has been “stretched out and coiled up” by

the contraction of the preceding segment. When it contracts, the ascending segment makes a movement that “unscrews” the base, moving it away from the apex, increasing the longitudinal axis of the heart and producing suction like that which would occur in the interior of a cylinder that moves away from its piston, dynamics that have been observed in humans in magnetic resonance images.²⁷

In this study, we have contributed data that demonstrate that the suction force produced during the isovolumic relaxation phase depends on contraction because it is produced during the phase of segmental contraction and, moreover, that its functionality is strongly linked to the contraction of the ascending segment of the apical loop, specifically:

1. We have shown that, at the beginning of and during the left ventricular isovolumic relaxation phase, the ascending segment of the apical loop is contracting.

2. Infiltration of the ascending segment of the apical loop with diluted formaldehyde directly affects the capacity to reduce the intraventricular pressure or, in other words, the suction force. This aspect has been demonstrated by the prolongation of the time required for the intraventricular pressure to fall to 10 mm Hg over the end-diastolic pressure, a level that enables us to ensure that the mitral valve is still closed and that the lower velocity (that is, more time elapsed) in the pressure fall is in a closed (isovolumic) chamber. It has also been demonstrated by the lower minimum intraventricular pressure reached in early diastole, which is significantly affected when we infiltrate said ascending segment.

3. As a consequence of a lower fall velocity and a less marked final decrease in the intraventricular pressure during the isovolumic phase, the suction effect is lesser and the ventricular filling rate decreases during early diastole, increasing in compensation during end-diastole, as a consequence of a contraction of the “fuller” left atrium. This has been demonstrated by the changes in the values of E, A, and the E/A ratio, as well as by the progressive increase in atrial pressure commencing in early diastole.

Limitations of the Study

The use of ultrasonic crystals is appropriate if we assume that the structure of the myocardium is organized partially or totally in a band and that we have implanted the ultrasonic crystals in the same line that marks the direction of the movement of the fibers. This method is unable to isolate the function of a single segment, as it is part of the same continuum as the others. Thus, the alteration

of any given segment would change the contraction in the entire band, as occurs in our model, in which the injection into the ascending segment also significantly modifies the contraction of the fibers contained in P2, identified as pertaining to the descending segment, which neighbors the injected segment.

For the identification of the segments and the direction of their fibers, as well as the postmortem confirmation in the anatomical specimens, we were counseled by Dr Torrent-Guasp. The subendocardial fibers of the descending segment in the zone of the anterior aspect of left ventricle pass through the mesocardium at a certain depth, crossing perpendicularly with those of the ascending segment,²⁸ a circumstance that we have confirmed in the anatomical specimens. For this reason, the crystals anchored in the subendocardium followed a direction that the pair implanted in the corresponding epicardium (ascending segment) crossed perpendicularly.

The muscle involvement secondary to the injection of diluted formaldehyde is difficult to standardize and, of course, it affects all the active and passive properties of the fiber, reducing contraction, relaxation and elasticity to their lowest limits. The attempt has been made to minimize the changes produced by formaldehyde, limiting the amount and number of injections in all the experiments, and monitoring the effect depending on the alteration of the contractility of the injected segment and verifying the change in transmitral flow. For many researchers, the theories of Dr Torrent-Guasp have opened paths they can follow to progress in the understanding of the physiology of cardiac muscle. Other points continue to be hard to reconcile with previous data.¹⁸

CONCLUSIONS

In this new conception of diastolic function, the 3 properties of the myocardial fibers would participate, following a certain order while, at the same time, overlapping. The initial suction with the closed chamber would be a consequence of the contraction of the last segment of the band, as we have attempted to demonstrate with the experiments presented here; the relaxation of the fibers of the successive segments with the mitral valve open would allow rapid filling and, finally, the distensibility would make it possible for the myocardial wall to yield in response to the increase in pressure/volume produced by injection into the atrium.

ACKNOWLEDGMENTS

This study was carried out in memory of Dr Francisco Torrent-Guasp.

REFERENCES

1. Torrent-Guasp F. El ciclo cardiaco. Madrid: Espasa-Calpe; 1954.
2. Streeter DD. The cardiovascular system I. In: American Physiological Society, editor. Handbook of physiology. Baltimore: Williams & Wilkins; 1979. p. 61-112.
3. Torrent Guasp F. La estructuración macroscópica del miocardio ventricular. *Rev Esp Cardiol.* 1980;33:265-87.
4. Torrent-Guasp F. Estructura y función del corazón. *Rev Esp Cardiol.* 1998;51:91-102.
5. Torrent-Guasp F, Bukberg GD, Clemente C, Cox JL, Coghlan HC, Gharib M. The structure and function of the helical heart and its buttress wrapping. I. The normal macroscopic structure of the heart. *Semin Thorac Cardiovasc Surg.* 2001;13:301-19.
6. Buckberg GD. Basic science review: The helix and the heart. *J Thorac Cardiovasc Surg.* 2002;124:863-83.
7. Torrent Guasp F. La mecánica ventricular. *Rev Lat Cardiol.* 2001;22:48-55.
8. Torrent Guasp F. Mecánica de los segmentos descendente y ascendente de la banda miocárdica ventricular. *Rev Esp Cardiol.* 2001;54:1091-102.
9. Torrent Guasp F. El ciclo cardiaco. *Rev Lat Cardiol.* 2003;24:28-41.
10. Brutsaert DL, Sys SU. Relaxation and diastole of the heart. *Physiol Rev.* 1989;69:1228-315.
11. Helmes M, Trombitas K, Granzier H. Titin develops restoring force in rat cardiac myocytes. *Circ Res.* 1996;79:619-26.
12. Martín G, Gimeno JV, Cosin J, Guillem MI. Time constant of isovolumic pressure fall, new numerical approaches and significance. *Am J Physiol.* 1984;247:H283-94.
13. Banerjee P, Banerjee T, Khand A, Clark AL, Cleland JG. Diastolic heart failure: neglected or misdiagnosed? *J Am Coll Cardiol.* 2002;39:138-41.
14. Vasan RS, Levi D. Defining diastolic Heart failure: a call for standardized diagnostic criteria. *Circulation.* 2000;101:2118-21.
15. Cleland JGF, Tendera M, Adamus J, Freemantle, Polonski L, Taylor J, on behalf of PEP-CHF Investigators. The perindopril in the elderly people with chronic heart failure (PEP-CHF) study. *Eur Heart J.* 2006;27:2338-45.
16. European Study Group on Diastolic Heart Failure. How to diagnose diastolic heart failure. *Eur Heart J.* 1998;19:990-1003.
17. MacFadyen RJ, MacLeod CM, Shiels P, Smith WR, MacDonald TM. Isolated diastolic heart failure as a cause of breathlessness in the community: The Arbroath study. *Eur J Heart Fail.* 2001;3:243-8.
18. Zarco P. La fase de llenado rápido ventricular: ¿un proceso de relajación o de contracción muscular? *Rev Esp Cardiol.* 2001;54:1031-2.
19. Strubelt O, Brasch H, Pentz R, Younes M. Experimental studies on the acute cardiovascular toxicity of formalin and its antidotal treatment. *Clin Toxicol.* 1990;28:221-33.
20. Caruana L, Petrie MC, Davie AP, McMurray JV. Do patients with suspected Heart failure and preserved left ventricular systolic function suffer from "diastolic heart failure" or from misdiagnosis? A prospective descriptive study. *BMJ.* 2000;321:215-8.
21. Mandinov L, Eberli FR, Seiler C, Hess OM. Diastolic heart failure. *Cardiovasc Res.* 2000;45:813-25.
22. Sengupta PP, Khandheria BK, Korinek J, Wang J, Jahangir A, Seward JB, et al. Apex-to-base dispersion in regional timing of left ventricular shortening and lengthening. *J Am Coll Cardiol.* 2006;47:163-72.
23. Buckberg GD, Castellá M, Gharib M, Saleh S. Active myocyte shortening during the 'isovolumetric relaxation' phase of diastole is responsible for ventricular suction; 'systolic ventricular filling.' *Eur J Cardiothorac Surg.* 2006;29 Suppl 1:98-106.
24. Ashikaga H, Criscione JC, Omens JH, Cowell JW, Ingels NB. Transmural left ventricular mechanisms underlying torsional recoil during relaxation. *Am J Physiol Heart Circ Physiol.* 2004;286:H640-7.
25. Ashikaga H, Coppola BA, Hopfenfeld B, Leifer ES, McVeigh ER, Omens JH. Transmural dispersion of myofiber mechanics. *J Am Coll Cardiol.* 2007;49:909-16.
26. Li P, Wang Z, Ballester M, Narula J, Vannan MA. Isolated diastolic dysfunction is a contraction abnormality: new insights from left ventricular longitudinal and torsional dynamics by velocity vector imaging. *Circulation.* 2005;112:II500.
27. Lorenz CH, Pastorek JS, Bundy JM. Delineation of normal human left ventricular twist throughout systole by taget cine magnetic resonance imaging. *J Cardiovasc Magn Reson.* 2000;2:97-108.
28. Buckberg GD, Coghlan HZ, Torrent-Guasp F. The structure and function of the helical heart and its buttress wrapping. V. Anatomic and physiologic considerations in the healthy and failing heart. *Semin Thorac Cardiovasc Surg.* 2001;13:358-85.