

Effect of Mycophenolate Mofetil on Diabetic Cardiomyopathy in db/db Mice



Efecto de micofenolato mofetilo en la miocardiopatía diabética de ratones db/db

To the Editor,

Recent studies have shown that chronic inflammation associated with the development and aggravation of type 2 diabetes mellitus is an important factor in the pathogenesis of diabetic macrovascular complications. Diabetic cardiomyopathy is characterized by functional and structural cardiac changes, most frequently myocardial fibrosis, including myocardial cell death and accumulation of extracellular matrix protein.¹ Mycophenolate mofetil (MMF) was shown to ameliorate renal injury and prevent

the development of nephropathy through anti-inflammatory mechanisms and attenuated podocyte apoptosis.² A study using a carotid artery balloon injury model revealed that MMF greatly reduced intimal hyperplasia with decreased expression of TGF- β 1 and collagen III.³ Mycophenolate mofetil prevented endothelial dysfunction through enhanced nitric oxide availability with improvement of endothelial nitric oxide synthase.⁴ The purpose of this study was to evaluate its effect on diabetic cardiomyopathy resulting from type 2 diabetes mellitus.

Six-week-old male nondiabetic db/m and diabetic db/db mice were purchased from Jackson Laboratory (Sacramento, California, United States). All mice received a diet of rodent pellets (348 kcal/100 g) containing 5.5% crude fat and tap water *ad libitum*. Mycophenolate mofetil (Roche Pharma AG, Grenzach-Wyhlen, Germany) was incorporated into chow (Dooyeol Biotech, Seoul,

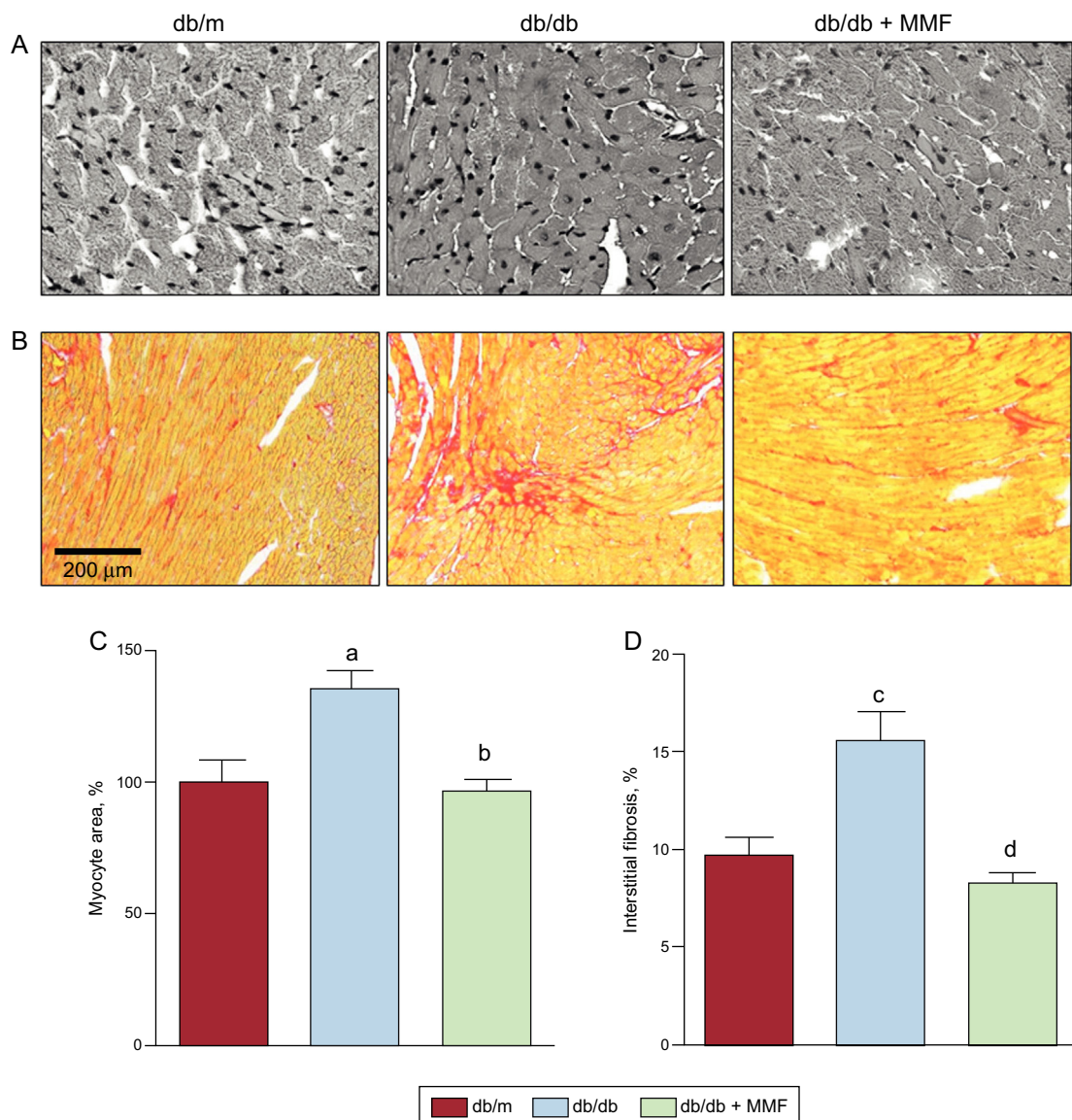


Figure. Effects of MMF on diabetic cardiomyopathy in db/db mice. Mycophenolate mofetil attenuates hypertrophy and fibrosis of myocytes in db/db mice. Representative images of hematoxylin and eosin-stained cardiac tissues (A) and Sirius red-stained interstitial areas (B). Quantification of cardiomyocyte cross-sectional area (C) and percentage of interstitial (D) areas in the graph. Data were analyzed by 1-way ANOVA with Newman-Keuls post-hoc testing and expressed as mean \pm SE ($n \geq 15$ per group). MMF, mycophenolate mofetil.

^a $P < 0.001$ vs db/m.

^b $P < 0.001$ vs db/db.

^c $P < 0.01$ vs db/m.

^d $P < 0.01$ vs db/db.

Korea) at an oral dose of 30 mg/kg body weight/d at a chow consumption rate of 0.2 g/g body weight. At 8 weeks of age, the mice were divided into 3 groups of 6 mice each as follows: the nondiabetic control group (db/m), the diabetic group (db/db), and the diabetes with MMF group (db/db + MMF). During experiments, food intake, water intake, urine volume, body weight, fasting plasma glucose level, and glycosylated hemoglobin were measured monthly. All animal experiments were performed in compliance with the guidelines of the Animal Research Ethics Committee of Kyung Hee University, Seoul, Korea.

Transthoracic echocardiography was performed to obtain 2-dimensional, M-mode images using a 12-MHz linear probe prior to sacrificing the animal at the end of the study protocol (20 weeks) using standard formulae. The cardiac tissue was fixed in buffered 4% formaldehyde and embedded in paraffin. Tissue sections of 5 μ m were deparaffinized, rehydrated and stained with hematoxylin and eosin to determine cardiomyocyte area. To visualize cardiac fibrosis, the sections were stained with Sirius red. Images from all stained cardiac tissue sections were analyzed using ImageJ software version 1.47t. Capillary and arteriolar densities in the myocardium were evaluated by means of CD31 and α -smooth muscle actin staining.

All values are expressed as means \pm SE. Results were analyzed using the Kruskal-Wallis nonparametric test for multiple comparisons. Significant differences in the Kruskal-Wallis test were confirmed by the Mann-Whitney test (used to compare mean differences). *P*-values $<$.05 were considered statistically significant.

Various biochemical parameters such as body weight, daily food intake, and daily water intake were higher in db/db mice groups than in the db/m mice group, but there was no difference between the 2 db/db mice groups in these parameters. Both db/db mice groups showed higher glycosylated hemoglobin levels than the db/m mice group. In particular, glycosylated hemoglobin was higher in the MMF-treated db/db group at 20 weeks.

As shown in the Figure, the diabetic mouse heart developed hypertrophy, including increased cardiac myocyte area and interstitial fibrosis. Cardiomyocyte cross-sectional area was decreased in MMF-treated db/db mice compared with untreated db/db mice (Figures A-C). Furthermore, interstitial fibrosis was also attenuated in the MMF-treated db/db heart (Figures B-D). However, MMF had no effect on intramyocardial arteriole or capillary densities (Table). Echocardiographic studies show dilated left ventricle and reduced cardiac performance in db/db mice (Table). The MMF-treated group showed a significant reduction in left ventricle dilatation, as indicated by a lower left ventricular diastolic and systolic dimension and volume. The left ventricular ejection fraction and fractional shortening were improved by MMF.

The results of this study suggest that MMF prevented the progression of diabetic cardiomyopathy in db/db mice independent of glycemic control. The MMF regimen is widely used in heart transplantation to prevent allograft vasculopathy, but limited data are available to demonstrate the beneficial effects of MMF on the nontransplanted heart. Some reports have suggested that MMF has antiatherogenic properties and that it downregulates endothelial adhesion molecules, alleviates proliferation of arterial smooth muscle cells, and induces apoptosis of monocytes or macrophages.^{2,5} A limitation of this study is that we did not evaluate the underlying cause of the cardioprotective effect of MMF. If confirmed in humans, the cardioprotective effect achieved by MMF in our small experience with a diabetic mouse model could be an effective way to alleviate cardiac hypertrophy and fibrosis in patients with diabetic cardiomyopathy.

Table

Effects of Mycophenolate Mofetil on Diabetic Cardiomyopathy in db/db Mice

Characteristics	db/m (n=6)	db/db (n=6)	db/db + MMF (n=6)
IVS thickness	0.76 \pm 0.11	0.73 \pm 0.08	0.67 \pm 0.08
PW thickness	0.82 \pm 0.09	0.79 \pm 0.13	0.74 \pm 0.08
LV diastolic dimension	3.92 \pm 0.31	4.55 \pm 0.28 ^a	3.70 \pm 0.33 ^b
LV systolic dimension	2.52 \pm 0.31	3.27 \pm 0.35 ^a	2.53 \pm 0.26 ^b
LV end-diastolic volume	0.16 \pm 0.04	0.24 \pm 0.04 ^a	0.13 \pm 0.03 ^b
LV end-systolic volume	0.04 \pm 0.02	0.09 \pm 0.03 ^a	0.04 \pm 0.12 ^b
Ejection fraction	71.6 \pm 4.8	61.2 \pm 6.2 ^a	67.1 \pm 3.5 ^b
Fractional shortening	35.8 \pm 3.9	28.4 \pm 3.9 ^a	32.2 \pm 2.7 ^b
Body weight, g	31.4 \pm 0.5	51.0 \pm 3.2 ^a	50.1 \pm 1.9 ^a
Heart weight, mg	137.3 \pm 3.9	142.5 \pm 2.2 ^a	139.3 \pm 1.6 ^b
Arteriole density, mm ²	27.83 \pm 5.3	20.5 \pm 4.1 ^a	19.3 \pm 3.1 ^a
Capillary density, mm ²	2083 \pm 177	1760 \pm 227 ^a	1833 \pm 85 ^a

IVS, interventricular septum; LV, left ventricular; MMF, mycophenolate mofetil; PW, posterior wall.

Data are expressed as mean \pm SE.

^a Significantly different with respect to db/m mice.

^b Significantly different with respect to db/db mice.

FUNDING

This work was supported by the Bio & Medical Technology Development Program of the National Research Foundation (NRF) funded by the Korean government (MEST) (No. 2012M3A9C6050507). Mycophenolate mofetil was kindly donated by Roche.

Kyung Hye Lee,^a Jung-Woo Seo,^b Sang Ho Lee,^b Jong Shin Woo,^a Ju-Young Moon,^b and Weon Kim^{a,*}

^aDivision of Cardiology, Department of Internal Medicine, Kyung Hee University, College of Medicine, Seoul, Korea

^bDivision of Nephrology, Department of Internal Medicine, Kyung Hee University, College of Medicine, Seoul, Korea

* Corresponding author:

E-mail address: mylovekw@hanmail.net (W. Kim).

Available online 28 February 2016

REFERENCES

1. Wang W, Wang B, Lu Q, Zhang W, Qin WD, Liu XJ. Inhibition of high-mobility group box 1 improves myocardial fibrosis and dysfunction in diabetic cardiomyopathy. *Int J Cardiol.* 2014;172:202-12.
2. Allison AC, Eugui EM. Mycophenolate mofetil and its mechanisms of action. *Immunopharmacology.* 2000;47:85-118.
3. Waller JR, Brook NR, Bicknell GR, Murphy GJ, Nicholson ML. Mycophenolate mofetil inhibits intimal hyperplasia and attenuates the expression of genes favouring smooth muscle cell proliferation and migration. *Transplant Proc.* 2005;37:164-6.
4. Freguin-Bouilland C, Godin M, Bellien J, Richard V, Remy-Jouet I, Dautreux B. Protective effect of mycophenolate mofetil on endothelial function in an aortic allograft model. *Transplantation.* 2011;91:35-41.
5. Richter MH, Zahn S, Kraus M, Mohr FW, Olbrich HG. Mycophenolate mofetil significantly reduces leukocyte graft infiltration after heterotopic cardiac transplantation in a rat model: comparative study with cyclosporine and FK 506. *J Heart Lung Transplant.* 2003;22:1107-16.

<http://dx.doi.org/10.1016/j.rec.2016.01.011>