

Echocardiographic Segmental Analysis in Patients With an Atrioventricular Criss-Cross

Jesús de Rubens Figueroa,^a Julio Erdmenger Orellana,^a Luis Muñoz Castellanos,^b Clara Vázquez Antona,^a Alfonso Buendía Hernández,^c and Jesús Vargas Barrón^a

^aDepartamento de Ecocardiografía, Instituto Nacional de Cardiología Ignacio Chávez (INCICH), Mexico

^bDepartamento de Embriología, Instituto Nacional de Cardiología Ignacio Chávez (INCICH), Mexico

^cServicio de Cardiología Pediátrica, Instituto Nacional de Cardiología Ignacio Chávez (INCICH), Mexico

The aim of this study was to describe the echocardiographic characteristics of patients with an atrioventricular criss-cross who underwent segmental cardiac morphological analysis. The study involved 5 patients with a criss-cross heart (0.6% of the studies). The patients' average age was 6 years and 3 months. All patients presented with situs solitus. Three had a discordant atrioventricular connection and 2 had a concordant connection. In addition, 4 patients had a ventriculoarterial connection with a double-outlet right ventricle while 1 had a concordant connection. Two patients had superior-inferior ventricles. Other associated lesions included ventricular septal defect in all patients, pulmonary stenosis, persistent ductus arteriosus, and atrial septal defect in 3, pulmonary perforation in 1, and a hypoplastic aortic arch in 1.

In these patients, segmental analysis can be carried out satisfactorily using transthoracic echocardiography.

Key words: Congenital heart disease. Superior-inferior ventricles. Criss-cross heart. Segmental analysis.

Análisis segmentario ecocardiográfico en pacientes con conexión auriculoventricular cruzada (*criss-cross*)

El objetivo es describir las características ecocardiográficas utilizando el análisis morfológico segmentario del corazón en los pacientes con criss-cross. Se estudió a 5 pacientes con diagnóstico de criss-cross (0,06% de los estudios). La media de edad fue 6 años y 3 meses. Todos los pacientes se presentaron en situs solitus. Las conexiones auriculoventriculares fueron 3 discordantes y 2 concordantes. Las conexiones ventriculoarteriales fueron 4 con doble salida del ventrículo derecho y una concordante. Dos pacientes cursaron con ventrículos superiorinferiores. Las lesiones asociadas fueron comunicación interventricular en todos los pacientes, estenosis pulmonar, persistencia del conducto arterioso y comunicación interauricular en 3, uno con imperforación pulmonar y otro con hipoplasia del arco aórtico. El análisis segmentario en estos pacientes puede ser estudiado adecuadamente por medio de la ecocardiografía transtorácica.

Palabras clave: Cardiopatía congénita. Ventrículos superiorinferiores. Criss-cross. Análisis segmentario.

INTRODUCTION

A heart with a criss-cross atrioventricular (AV) connection is a cardiopathy in which the ventricles are positioned contralaterally to the atria to which they are connected; the ventricular inflow tracts are crossed, hence the name criss-cross.

In 1961 various cases of AV discordance with or without ventriculoarterial (VA) discordance were described. One of those cases presented as situs

solitus with dextrorotation of the cardiac loop, which could correspond to the description of this abnormality.¹ In 1973, for the first time, in Mexico a report was published of a 4-month-old boy with situs solitus with AV concordance, VA discordance, and crossing of the ventricular inflow chambers, with anterosuperior right ventricle (RV) and posterior and inferior left ventricle (LV), ventricular septal defect (VSD), and pulmonary stenosis (PS).² These cases were later given the name of criss-cross.³

In the later years, other cases were described: 37 with situs solitus, 2 with situs inversus, and 1 with isomerism, most with AV concordance.^{4,5} The most common VA connection was discordant transposition of the great arteries (TGA), followed by double outlet RV (DORV), associated with PS and even more rarely with pulmonary atresia.⁴⁻⁶

The most common is atrial situs solitus presentation with right atrium (RA) connected to left-sided RV

Correspondence: Dr. J. de Rubens Figueroa.
Juan Badiano, 1, Col. Sección XVIII. Delegación Tlalpan. CP 14080.
México DF. México.
E-mail: derubens@hotmail.com

Received December 12, 2007.

Accepted for publication December 16, 2008.

with anterior tricuspid valve and left aorta, as well as left atrium (LA) connected to right-sided LV with mitral valve oriented in the posterior direction. Criss-cross heart is often associated with superior-inferior ventricles; this ventricular relationship can present in other cardiopathies.⁷

In many cases, the size of the ventricles (small on many occasions) is conditioned by the size of the annulus of the AV valves.^{8,9}

The physiology is determined by the discordant or concordant AV and VA connection and the associated cardiac defects, such as displaced and/or straddling left AV valve, VSD (which always presents), valvular or subvalvular PS, small RV, and juxtaposition of the atrial appendages.^{7,10-12}

Another of its hemodynamic characteristics is that the systemic and pulmonary venous systems are crossed at the AV level, although without mixing.

Two-dimensional echocardiography, with subcostal and 4-chamber views, can be used to identify the ventricular morphology and position, the AV valves, the AV and VA connection, and the characteristics of the great vessels. The artery connection can be seen more clearly in the parasternal window.¹³

METHODS

Over a 5-year period, 8567 studies were performed in our echocardiography laboratory; criss-cross heart was diagnosed in 5 patients.

A retrospective, observational, longitudinal study was carried out, analyzing age, gender, and symptoms. The echocardiographic study was based on the segmental sequential approach used to diagnose congenital heart diseases.¹⁴ The study identified the situs, AV and VA connection, spatial position of the ventricles and interventricular septum, characteristics of the arterial vessels, ventricular size, other associated cardiac lesions, and the orientation of the aortic arch. Because the level of implantation of the AV valves is difficult to define in this condition, ventricular morphology was defined by the characteristics of the subvalvular apparatus, RV moderator band and trabeculations. Blood flow characteristics and directions were analyzed by color Doppler ultrasound. In 3 patients, the echocardiographic findings were compared to the cardiac catheterization study to confirm the diagnosis.

All studies were carried out with Hewlett-Packard Agilent 5500 echocardiography system using 3-MHz and 8-MHz transducers.

Patients with hearts in which the superior-inferior ventricles did not present criss-cross were excluded from the study.

RESULTS

Criss-cross heart was diagnosed in 5 (0.06%) of the 8567 studies. Patient age ranged between 1 month and 20 years (mean, 6 years and 3 months); 4 were female and 1 was male. The predominant clinical signs were systolic murmur in the aortic area in all patients, manifestations of heart failure in 4, and cyanosis in 3.

All 5 patients presented situs solitus and levocardia on echocardiographic segmental analysis. Pulmonary venous return was normal in all patients, and none had juxtaposition of the atrial appendages.

The AV connections were discordant in 3 cases and concordant in 2. The tricuspid valve showed regurgitation in 2 patients (1 with valve dysplasia) and was normal in 3. Hypoplastic mitral valve was present in 1 patient and straddling mitral valve in 2. The interventricular septum was vertical in 3 patients and horizontal in 2, with superior-inferior ventricles. In 3 patients, the LV was small (Figures 1 and 2). Regarding the VA connection, 4 patients presented DORV and 1, concordance with imperforate pulmonary valve (IPV).

The associated cardiac lesions were large VSD in all patients (1 perimembranous; 2 subaortic, 2 inflow tract); 1 had multiple VSDs. In 3 patients, mixed-type PS was present; persistent ductus arteriosus in 3, and atrial septal defect in 3; 1 patient had hypoplastic aortic arch. The aortic arch was left-sided in 4 cases and right-sided in 1 (Table 1).

A hemodynamic study was performed in 3 patients and was consistent with the echocardiographic diagnoses.

To our knowledge, none of the 5 patients died during clinical follow-up.

DISCUSSION

Criss-cross heart is a rare, complex congenital heart malformation. The ventricles twist around their long axis, with no concomitant movement of the atria, thus producing crossing of the inflow tracts. In a crossed AV connection, the ventricles are contralateral to the atria to which they are connected. This abnormal position is explained by twisting of the ventricular mass (once the AV connection has been established). When twisting over the ventricular long axis is counterclockwise in concordant AV connections, the right-sided RA remains connected to the right ventricle (RV) spatially located in the anterior and left position; this leads to a discordant AV relationship (Figure 3A and B). When the AV connections are discordant, the twist is clockwise and the left-sided LA is connected to the RV, located in the anterior and right position, which determines a concordant AV relationship¹⁵⁻¹⁷ (Figure 3C and D).

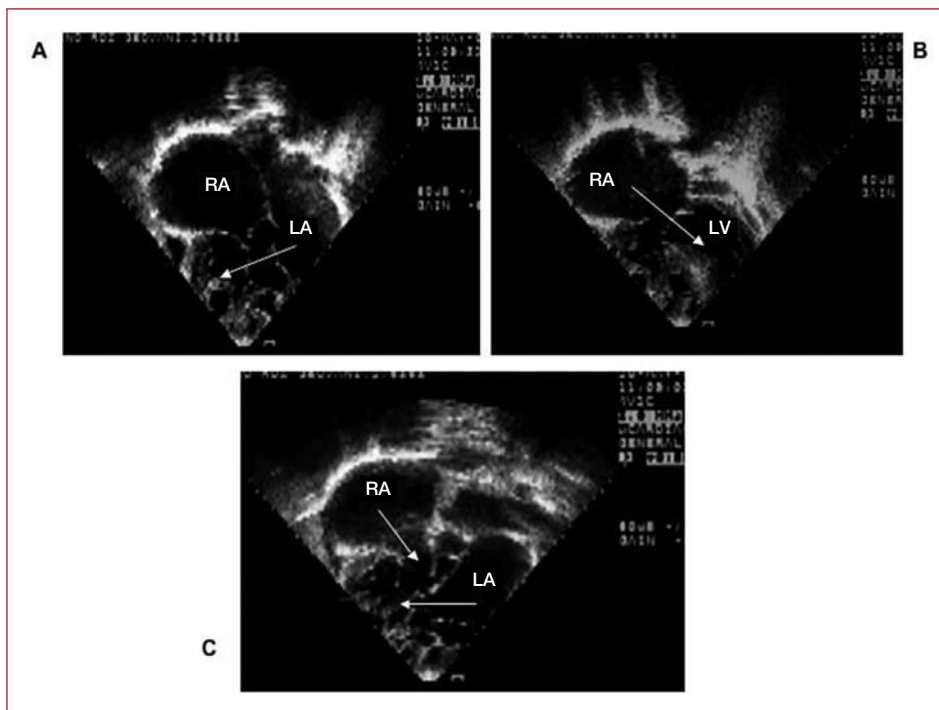


Figure 1. Two-dimensional echocardiography of Patient 3 in 4-chamber apical view. A, left atrium (LA) connected to a right-sided morphologic right ventricle (RV) with atrioventricular discordance and straddling mitral valve. B, right atrium (RA) connected to a left-sided morphologic left ventricle (LV). C, atrioventricular crossover with vertically oriented ventricles.

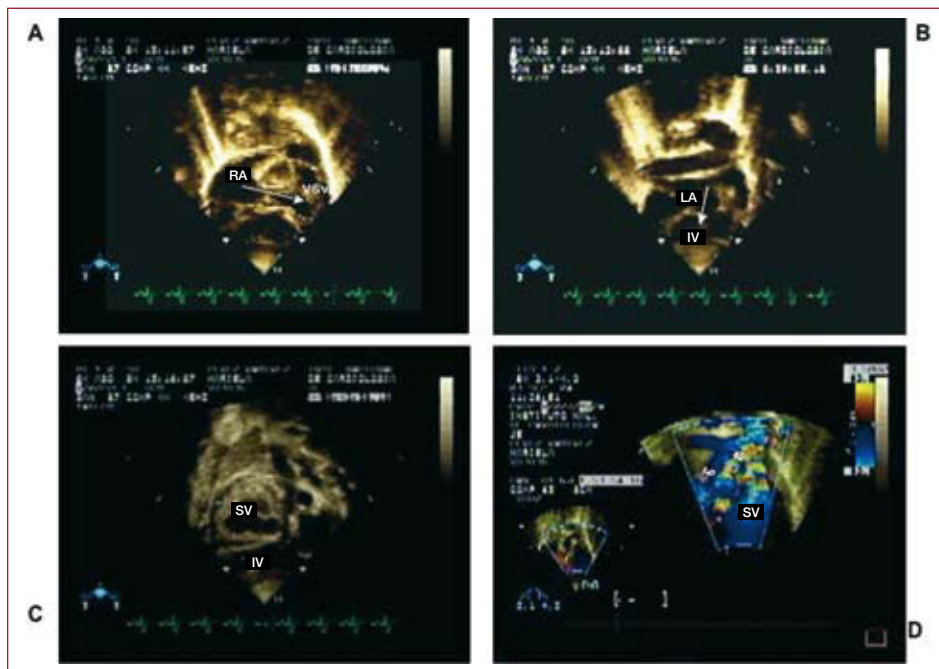

Figure 2. Two-dimensional color echocardiography of Patient 5, in subcostal view. A: right atrium (RA) connected to a superior ventricle (SV). B: left atrium (LA) connected to an inferior ventricle (IV), with atrioventricular concordance. C: superior ventricle (SV) and inferior ventricle (IV). D: double-outlet superior ventricle (SV) with right-sided aorta (Ao) and left-sided pulmonary artery (PA).

TABLE 1. Echocardiographic Characteristics of Patients With Criss-Cross Heart

Case	Age	Sex	Situs	AVC	IVS	SLV	VAC	VSD	PS	PDA	Lesions	AoA
1	2 years, 9 months	F	S	D	V		DORV	IT	Yes	Yes	SMV, ASD	L
2	8 years, 3 months	F	S	D	V	Yes	DORV	PM	Yes			L
3	20 years	M	S	D	V		DORV	IT	Yes		SMV	L
4	4 months	F	S	C	H		C	SubAo, SMV		Yes	IPV, ASD	R
5	1 month	F	S	C	H	Yes	DORV	SubAo, T		Yes	HAA, ASD	L

AoA indicates aortic arch; ASD, atrial septal defect; AVC, atrioventricular connection; C, concordance; D, discordance; DORV, double-outlet right ventricular; F, female; H, horizontal; HAA, hypoplastic aortic arch; IPV, imperforate pulmonary valve; IT, inflow tract; IVS, interventricular septum; L, left; M, male; PDA, persistent ductus arteriosus; PM, perimembranous; PS, pulmonary stenosis; R, right; S, solitus; SLV, small left ventricle; SMV, straddling mitral valve; SubAo, subaortic; T, trabecular; V, vertical; VAC, ventriculoarterial connection; VSD, ventricular septal defect.

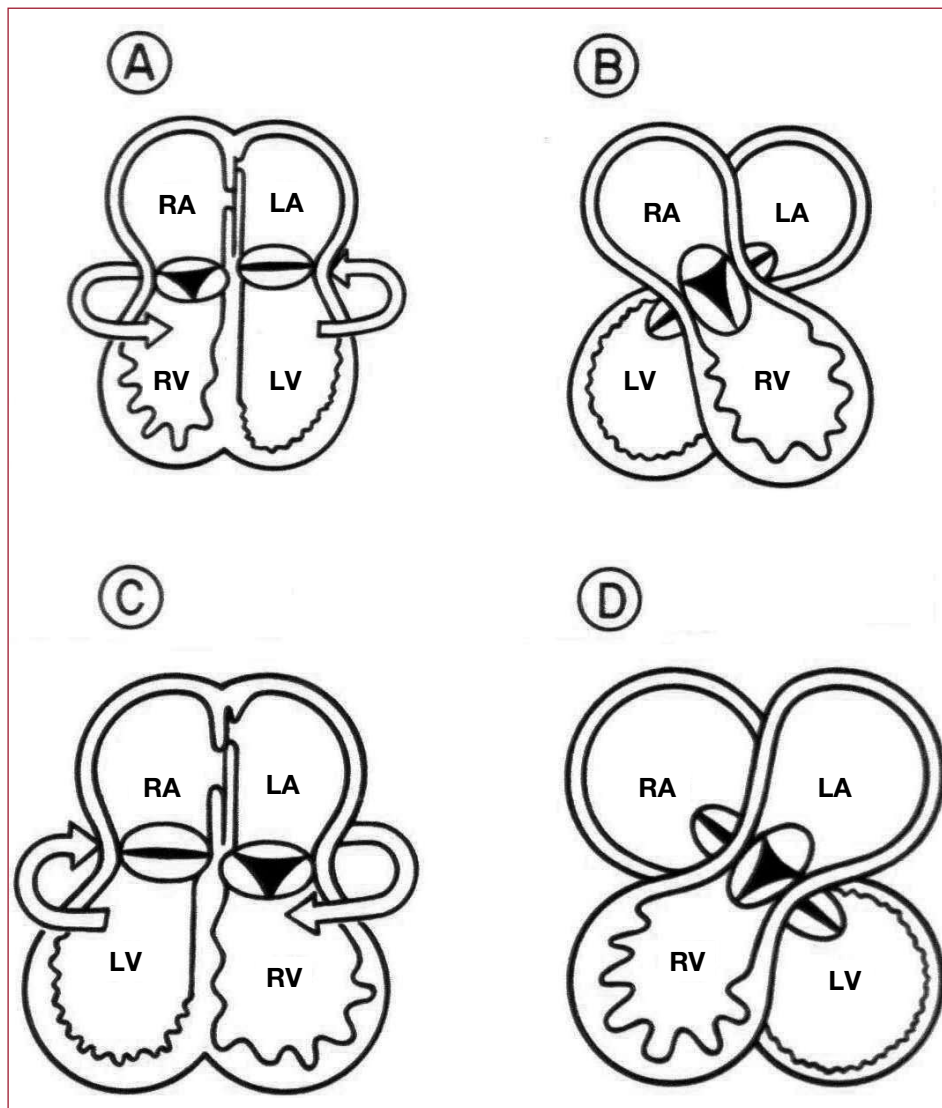


Figure 3. Anterior view (from the observer). Diagram of the cardiac chambers illustrating the etiologic mechanism (ventricular twist) that causes criss-cross heart. A: atrioventricular (AV) concordance; ventricular twist is counterclockwise. B: AV concordance with discordant spatial relationship: right-sided morphologic right atrium (RA) connected to a left-sided morphologic right ventricle (RV) and left-sided morphologic left atrium (LA) connected to a right-sided morphologic left ventricle (LV). C: AV discordance; ventricular twist is clockwise. D: AV discordance with concordant spatial relationship: right-sided morphologic RA connected to a left-sided morphologic LV and left-sided morphologic LA connected to a right-sided morphologic RV.

This disorder can be interpreted as the crossing of systemic and pulmonary venous blood without mixing in the AV valves.³

In the criss-cross heart, the ventricles are often related top to bottom (superior-inferior), displacing the ventricular mass in the horizontal plane. However, this is not an essential condition. In our study, only 2 of the 5 patients presented superior-inferior ventricles.

The VA connection should be described separately from the relationship of the chambers and arteries with the AV connection.¹⁷ The VA connection is extremely variable: discordant is the most common type reported in the literature, followed by DORV. The VA relationship may be concordant or discordant, and PA rarely presents.¹⁸ In our study, DORV was most common and 1 patient had IPV (Table). Abnormalities in the coronary arteries, such as underdeveloped or absent left anterior

interventricular artery, have also been reported.¹⁹

Up to 1999, 97 cases of patients with criss-cross heart had been published, of which only 14 presented double discordance.²⁰

A complete anatomic and physiologic diagnosis can be established in this condition using 2-dimensional echocardiography, along with other diagnostic methods such as magnetic resonance imaging, if necessary.^{21,22}

The type of connection (AV or VA) and characteristics of associated lesions (VSD, PS, straddling mitral valve, and small ventricles) determine the clinical and hemodynamic manifestations in patients with criss-cross heart and can be used to guide the surgical repair.¹⁶

One of the difficulties for the surgeon is to locate the branch of the His bundle in VSD repair. Biventricular surgical repair is the option in some criss-cross cases. In patients who also present

DORV or TGA and have ventricles of adequate size, the repair should be accompanied by a patch on the ventricular septal defect and an atrial or arterial switch. If PS is present, a systemic-pulmonary shunt must be performed; however, RV size and tricuspid valve displacement may be limitations for good surgical outcome.^{9,23} In patients who cannot undergo biventricular surgical repair, palliative surgery with the modified Glenn and Fontan technique for definitive repair is proposed.¹³

The condition can be more clearly understood if the defects are observed separately because criss-cross hearts are characterized by concomitant multiple lesions and rarely present alone.¹⁹

In conclusion, patients with criss-cross heart can be diagnosed by a careful, systematic segmental study with 2-dimensional color-coded transthoracic echocardiography to determine the sequence of connections and spatial relationships of the cardiac chambers and identify other abnormalities.

REFERENCES

1. Lev M, Rowlatt UF. The pathologic anatomy of mixed levocardia. A review of thirteen cases of atrial or ventricular inversion with or without corrected transposition. *Am J Cardiol.* 1961;8:250-5.
2. Franco Vázquez JS, Pérez Treviño C, Gaxiola A. [Corrected transposition of the great arteries with extreme counterclockwise torsion of the heart]. *Extrait des Acta Cardiologica (Bruxelles).* 1973;28:636-43.
3. Anderson RH, Shinebourne AE, Gerlis ML. Criss-cross atrioventricular relationship producing paradoxical atrioventricular concordance or discordance. Their significance to nomenclature of congenital heart disease. *Circulation.* 1974;50:176-80.
4. Attie F, Muñoz Castellanos L, Ovseyevitz J, Flores-Delgado I, Testelli RM, Buendía A, et al. Crossed atrioventricular connections. *Am Heart J.* 1980;99:163-72.
5. Anderson RH, Lie JT, Sieg K, Hagler DJ, Ritter DG, Davis GD. A criss-cross heart. Detailed anatomic description and discussion of morphogenesis. *Mayo Clin Proc.* 1977;52:569-75.
6. Shneeweiss A, Shem Tov A, Blieden LC, Deutsch V, Neufeld HN. Criss-cross heart —a case with horizontal septum, complete transposition, pulmonary atresia and ventricular septal defect. *Pediatr Cardiol.* 1982;3:325-8.
7. Hery E. Echocardiographic findings in superior-inferior cardiac ventricles. *Am J Cardiol.* 1989;63:1385.
8. van Mill G, Moulart A, Harinck E, Wenink A, Oppenheimer AD. Subcostal two dimensional echocardiographic recognition of a criss-cross heart with discordant ventricle arterial connections. *Pediatr Cardiol.* 1982;3:319-23.
9. Marino B, Sanders PS, Pasquini L, Giannico S, Parness AI, Colan DS. Two-dimensional echocardiographic anatomy in criss cross heart. *Am J Cardiol.* 1986;58:325-33.
10. Anderson RH. Abnormal positions and relationships of the heart. In: Anderson RH, Baker JE, McCartney JF, Rigby LM, Shinebourne E, Tynan M, editors. *Paediatric cardiology.* 2nd ed. London: Livingstone; 2002. p. 1586-93.
11. Sieg K, Hegler DJ, Ritter DG, McGoan DC, Maloney JD, Seward JB, et al. Straddling right atrioventricular valve in criss-cross atrioventricular relationship. *Mayo Clin Proc.* 1977;52:561-8.
12. Snider AR, Serwer AG, Ritter BS. *Echocardiography in pediatric heart disease.* 2nd ed. St. Louis: Mosby; 1997. p. 571-5.
13. Carminati M. Cross-sectional echocardiography study of criss-cross hearts and supero-inferior ventricles. *Am J Cardiol.* 1987;59:114-8.
14. Tynan MJ, Becker AE, McCartney FJ, Quero JM, Shinebourne EA, Anderson RH. Nomenclature and classification of congenital heart disease. *Br Heart J.* 1979;41:544-53.
15. Patiño BE, Muñoz Castellanos L, Calderón CJ, Ramírez S, García MJ, Buendía HA. Aspectos clínicos de criss-cross: A propósito de un caso. *Arch Cardiol Méx.* 2006;76:197-201.
16. Attie F, Zabal C, Buendía A. *Cardiología pediátrica. Diagnóstico y tratamiento.* 1st ed. México: Panamericana; 1993. p. 353-62.
17. Anderson RH. Criss-cross hearts revisited. *Pediatr Cardiol.* 1982;3:305-13.
18. Zach M, Singer H, Löser H, Hagel KJ. The horizontal interventricular septum: three cases with different ventriculoarterial connections. *Eur J Cardiol.* 1980;11:269-82.
19. Angelini P, López A, Lufschanowski R, Nemeth AM, Flamm DS. Coronary arteries in criss-cross heart. *Tex Heart Inst J.* 2003;30:208-13.
20. Cabrera DA, Alcibar VJ, Rienzu IM-A, Carbonero RD, Portillo Barreda M-C, Miranda GJ-M, et al. Corazón en crisscross con discordancia auriculoventricular y ventriculo arterial. *Rev Esp Cardiol.* 2000;53:1121-2.
21. Robinson JP, Kumpeng V, McCartney JF. Cross sectional echocardiographic and angiographic correlation in crisscross hearts. *Br Heart J.* 1985;54:61-7.
22. Araoz AP, Reddy PG, Thompson DP, Higgins BC. Magnetic resonance angiography of criss-cross heart. *Circulation.* 2002;105:537-8.
23. Danielson GK, Tabry IF, Ritter DG, Fulton RE. Surgical repair of criss-cross heart with straddling atrioventricular valve. *J Thorac Cardiovasc Surg.* 1979;77:847-51.