

## ECG Contest

## ECG, May 2020

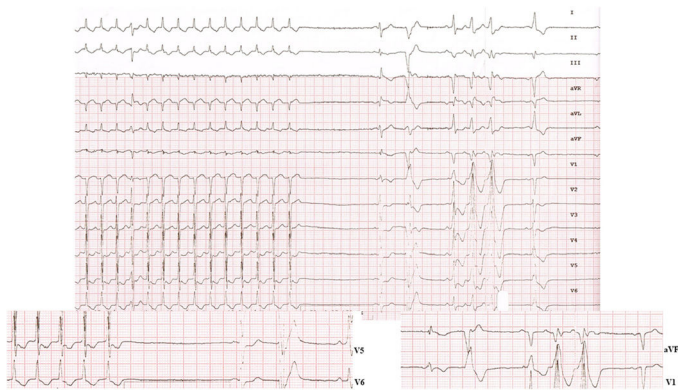
## ECG de mayo de 2020



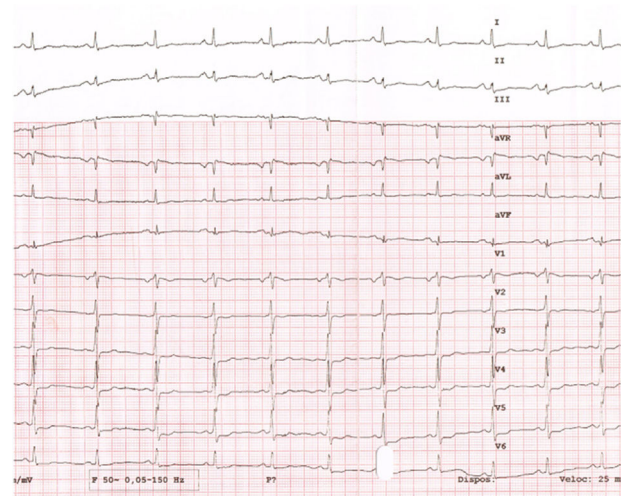
Ez Alddin Rajjoub Al-Mahdi,\* Álvaro Lorente Ros, and Vanesa Cristina Lozano Granero

Servicio de Cardiología, Hospital Universitario Ramón y Cajal, Madrid, Spain

A 72-year-old man was admitted to the general surgery department after a Hartmann intervention for diverticulitis. On different days after the operation, he required attention for tachyarrhythmia that always remitted with carotid sinus massage. **Figure 1** shows the response to one of the massages (the expanded traces reflect different times in the response: Left panel, V<sub>5</sub>-V<sub>6</sub> capture the end of the tachycardia; Right panel, aVF and V<sub>1</sub> show the ongoing response to massage). **Figure 2** shows the baseline electrocardiogram.



**Figure 1.**



**Figure 2.**

What type of tachycardia did the patient have?

1. Atrial tachycardia with first-degree atrioventricular block.
2. Sinus tachycardia.
3. Nodal re-entry tachycardia.
4. Tachycardia mediated by orthodromic accessory pathway.

Submit your answer to [www.revespcardiol.org/en/electroreto/73/05](http://www.revespcardiol.org/en/electroreto/73/05). The answer will be published in the next issue (June 2020). #RetoECG.

\* Corresponding author:  
E-mail address: [erajal2010@gmail.com](mailto:erajal2010@gmail.com) (E.A. Rajjoub Al-Mahdi).