

## ECG Contest

## ECG, March 2020

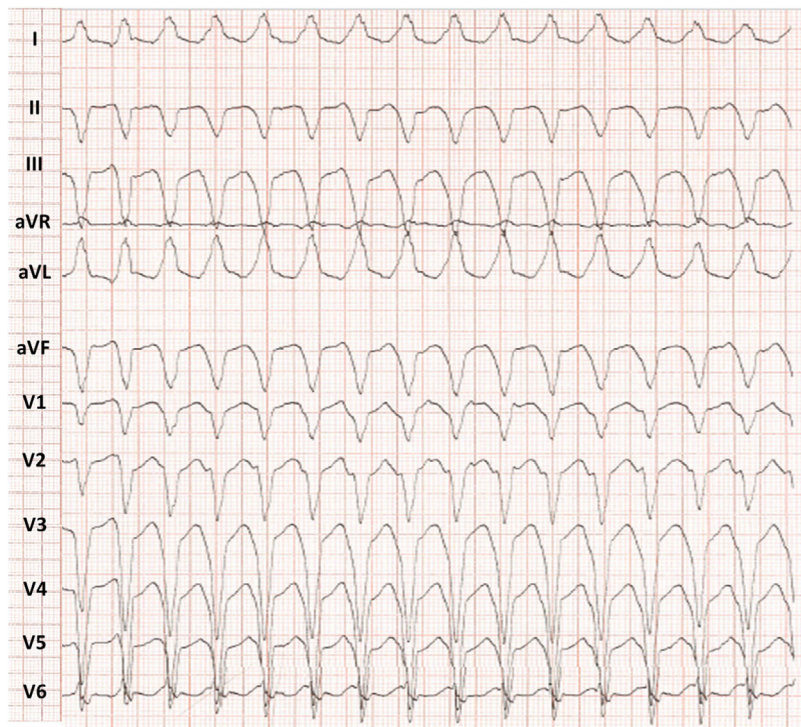
## ECG de marzo de 2020



Andrea Martínez-Cámara, Cristina Martín-Sierra, and Gerard Loughlin\*

Unidad de Arritmias, Servicio de Cardiología, Complejo Hospitalario Universitario de Toledo, Toledo, Spain

A 42-year-old man with a previous diagnosis of right ventricular arrhythmogenic cardiomyopathy and a carrier of a single-chamber implantable cardioverter-defibrillator (ICD) for primary prevention attended the emergency room due to a 1-hour history of palpitations, accompanied by general malaise. The ECG recorded is shown in [figure 1](#).



**Figure 1.**

What do you think was the diagnosis?

1. Aberrant supraventricular tachycardia.
2. Antidromic tachycardia.
3. Ventricular tachycardia with ventriculoatrial conduction.
4. Dual tachycardia.

Submit your answer to <http://www.revespcardiol.org/es/electroreto/73/03>. The answer will be published in the next issue (April 2020). #RetoECG.

\* Corresponding author:  
E-mail address: [gerardscotland@hotmail.com](mailto:gerardscotland@hotmail.com) (G. Loughlin).  
Available online