

ECG Contest

ECG, March 2017

ECG de marzo de 2017

Alfonso Macías,* Sara Castaño, and Inés Madrazo

Servicio de Cardiología, Hospital General Nuestra Señora del Prado, Talavera de la Reina, Toledo, Spain



A 79-year-old man with a dual-chamber defibrillator for the last 6 years presents to the emergency room with a 3-hour history of palpitations. He is hemodynamically stable (blood pressure, 130/70 mmHg) and has not received any shocks from the device. An electrocardiogram is recorded (Figure).

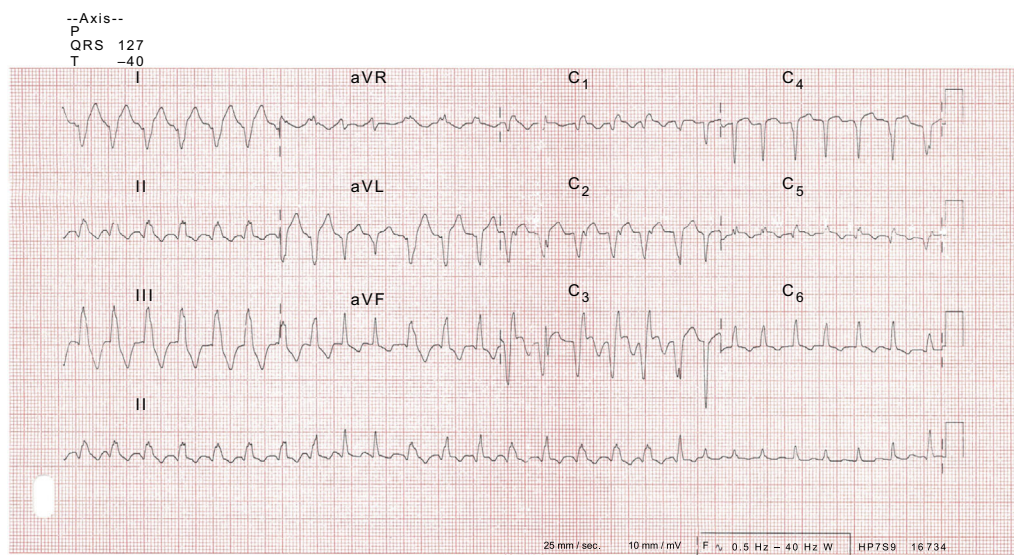


Figure.

What is the diagnosis with this trace?

1. Polymorphic ventricular tachycardia
2. Atrial fibrillation with aberrant conduction
3. Monomorphic ventricular tachycardia and atrial fibrillation
4. Pre-excited atrial fibrillation (left lateral accessory pathway)

Suggest a solution to this ECG Contest <http://www.revespcardiol.org/en/electroreto/70/3>. The answer will be published in the next issue (April 2017). #RetoECG.

* Corresponding author:

E-mail address: amaciasg@sescam.jccm.es (A. Macías).