Rev Esp Cardiol. 2016;69(3):325

ECG Contest

ECG, March 2016

ECG de marzo de 2016

Gustavo Tortajada

Servicio de Electrofisiología, Centro Cardiovascular de Casa de Galicia y Revista Uruguaya de Cardiología, Montevideo, Uruguay

The patient was a 22-year-old woman with no family or personal history of note. She reported having had recurrent brief episodes of palpitations, which began and ended abruptly, for at least 5 years, although they had never been documented. Twice they had been accompanied by presyncope. There was nothing else in her history that was worthy of mention. She underwent electrocardiography, echocardiography and 24-hour Holter monitoring, which revealed no evidence of disease. She attended the emergency department with a new episode of palpitations, of sudden onset, that had commenced approximately 30 minutes earlier. Electrocardiography was performed (Figure), and the symptoms ceased during the recording. What is your diagnosis?

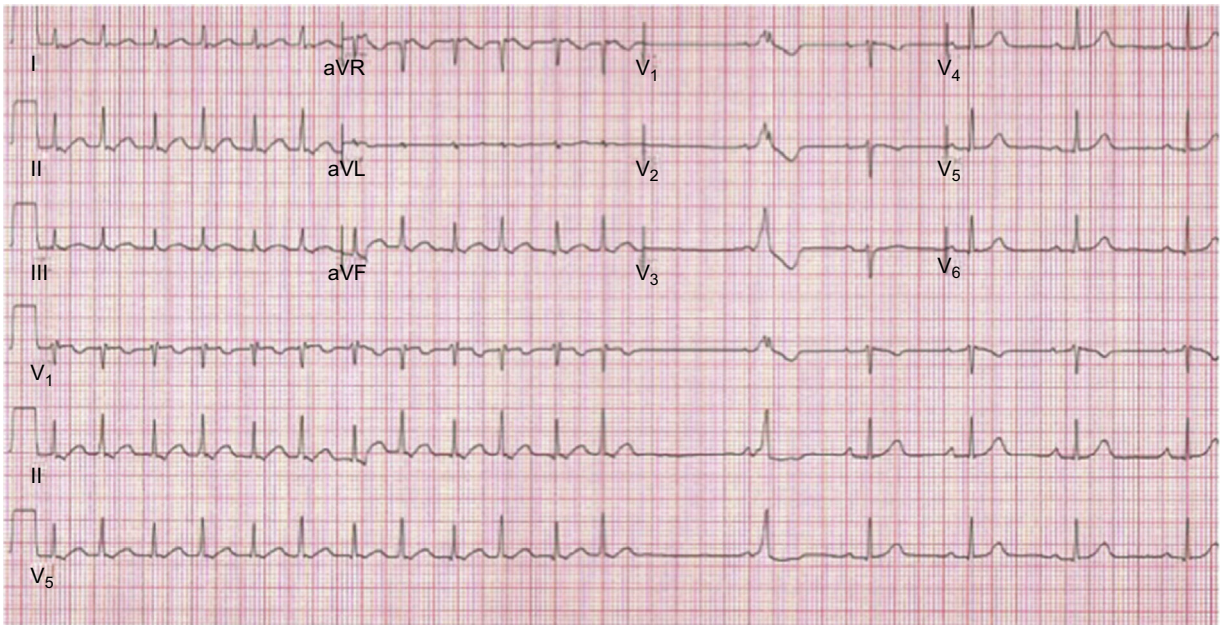

Figure.

Suggest a solution to this ECG Contest at http://www.revespcardiol.org/es/electroreto/69/03 (only Spanish). The answer will be published in the next issue (April 2016). #RetoECG.

E-mail address: gtortabel@hotmail.com

http://dx.doi.org/10.1016/j.rec.2015.09.017
1885-5857/© 2015 Sociedad Española de Cardiología. Published by Elsevier España, S.L.U. All rights reserved.