

ECG Contest

ECG, June 2015

ECG de junio de 2015

Domingo Marzal Martín

Servicio de Cardiología, Complejo Hospitalario de Mérida, Mérida, Badajoz, Spain



A 79-year-old woman, with medical history of high blood pressure, type 2 diabetes mellitus treated with oral antidiabetics, and heart failure with moderately depressed left ventricular systolic function and paroxysmal atrial fibrillation, in functional class II of the New York Heart Association, was being treated with acenocoumarol, ramipril, digoxin, torsemide, metformin, and omeprazole. She consulted the emergency department due to a 1-week history of regular palpitations and general malaise and nausea after spontaneous resolution of previous acute gastroenteritis. An electrocardiogram (Figure) and complete analytical study were performed when she arrived at the emergency department.

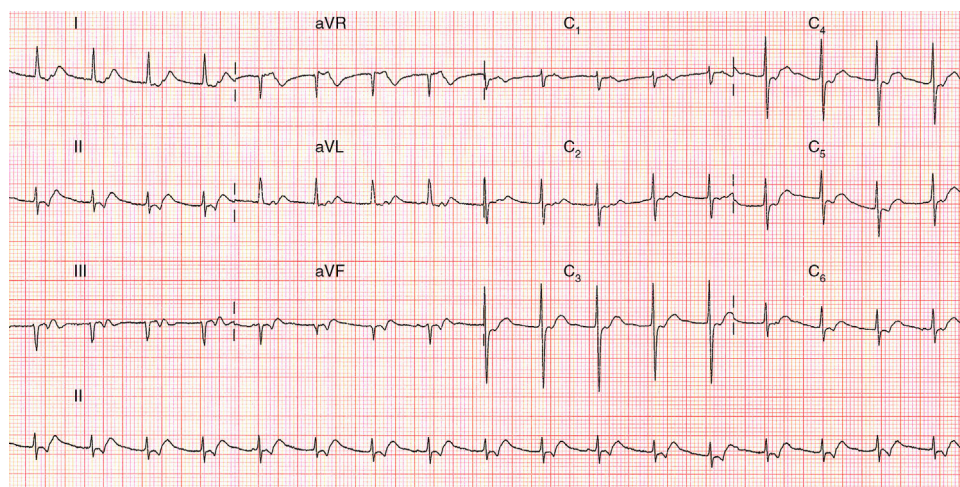


Figure.

Suggest a solution to this ECG Contest at <http://www.revespcardiol.org/es/electroreto/68/06> (only Spanish). The answer will be published in the next issue (July 2015). #RetoECG.

E-mail address: domingo.marzal@gmail.com

<http://dx.doi.org/10.1016/j.rec.2014.08.018>

1885-5857/© 2014 Sociedad Española de Cardiología. Published by Elsevier España, S.L.U. All rights reserved.