

## ECG Contest

## ECG, February 2015

## ECG de febrero de 2015

Tomás Ripoll Vera

Servicio de Cardiología, Hospital Son Llàtzer, Instituto de Investigación Sanitaria de Palma (IdISPa), Palma de Mallorca, Balearic Islands, Spain



This case concerns a 62-year-old woman, who had been hypertensive since the age of 49 years. Her parents had died suddenly in odd circumstances: her father, at the age of 45 years, possibly due to stroke and her mother at the age of 50 years, with a “big” heart. In 2004, the patient was assessed for exertional dyspnea and a murmur; electrocardiography (Figure 1), echocardiography, and stress testing were performed, with no pathological findings.

In 2013, she was referred for dyspnea (functional class III/IV), and had a rough-sounding, grade III/VI parasternal systolic murmur that increased with the Valsalva maneuver. Electrocardiography (Figure 2) and echocardiography showed mild concentric left ventricular hypertrophy and moderate-severe (16 mm) basal septal hypertrophy, with preserved function and no intraventricular obstruction. Stress testing, which had to be suspended because of dyspnea, reached 6.8 MET and was negative for ischemia; blood pressure response was normal.

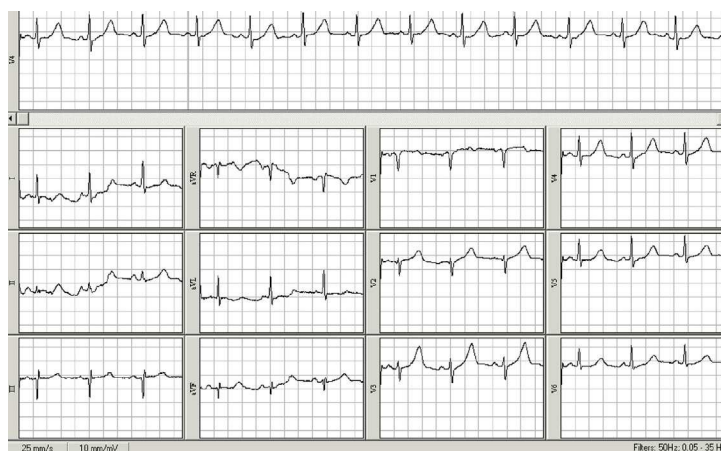


Figure 1.

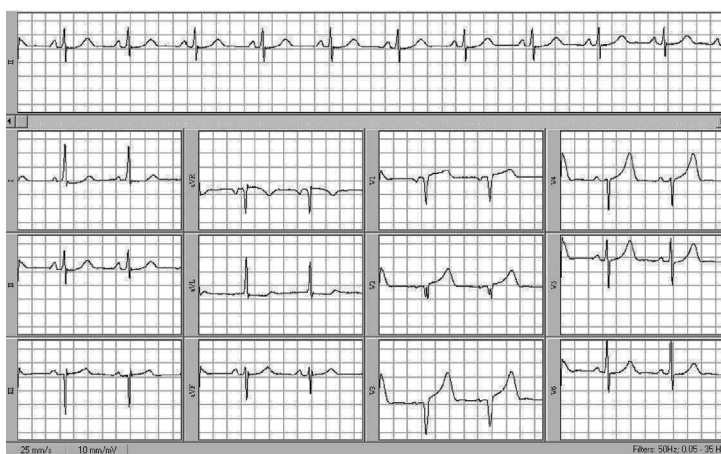

Figure 2.

Suggest a solution to this ECG Contest at <http://www.revescardiol.org/es/electroreto/68/02> (only Spanish). The answer will be published in the next issue (March 2015). #ECG-RETO.

E-mail address: [tripoll@hsl.es](mailto:tripoll@hsl.es)

<http://dx.doi.org/10.1016/j.rec.2014.06.028>

1885-5857/© 2014 Sociedad Española de Cardiología. Published by Elsevier España, S.L.U. All rights reserved.