

ECG Contest

ECG, December 2017



ECG de diciembre de 2017

Pedro Martínez-Losas* and Miguel Ángel Cobos Gil

Instituto Cardiovascular, Hospital Clínico San Carlos, Madrid, Spain

A 48-year-old hypertense male smoker, with a 1-year history of unstable angina, required implantation of 2 drug-eluting stents in the left main coronary artery and the left anterior descending artery. He attended the clinic for a follow-up exercise test. The test was discontinued during stage 2 of the Bruce protocol, on reaching 7 metabolic equivalents, because of atypical chest pain. The electrocardiogram at the time of discontinuation is shown in the [Figure](#).

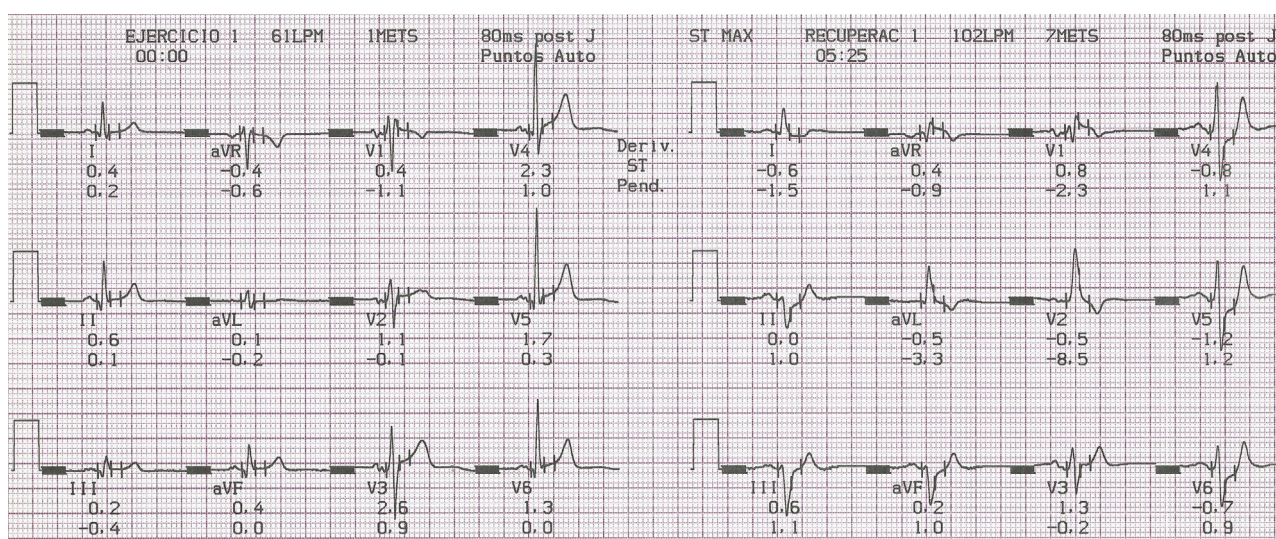


Figure.

What is the correct diagnosis and appropriate approach?

- Negative exercise test; clinical follow-up required
- Exercise test not evaluable; stress echocardiography should be performed
- Positive exercise test; medical treatment should be adjusted
- Positive exercise test; coronary angiography should be performed

Suggest a diagnosis to this ECG Contest at: <http://www.revvespcardiol.org/electroreto/70/12>. The answer will be published in the next issue (January 2018). #EKGchallenge.

* Corresponding author:

E-mail address: martinezlosasp@gmail.com (P. Martínez-Losas).