

ECG Contest

ECG, August 2019

ECG de agosto de 2019



Sofía Calero-Núñez,* Víctor M. Hidalgo-Olivares, and Jesús Fernando García-Sacristán Fernández

Unidad de Electrofisiología y Estimulación Cardíaca, Servicio de Cardiología, Complejo Hospitalario Universitario de Albacete, Albacete, Spain

A 33-year-old woman, with no relevant personal or family history, was referred for electrophysiological study because of clinical manifestations in the past year consisting of frequent and paroxysmal palpitations not worsening with exercise. The ECG shown in the [Figure 1](#) was recorded. A 24-hour electrocardiographic Holter study showed the presence of a regular narrow-QRS tachycardia most of the time.

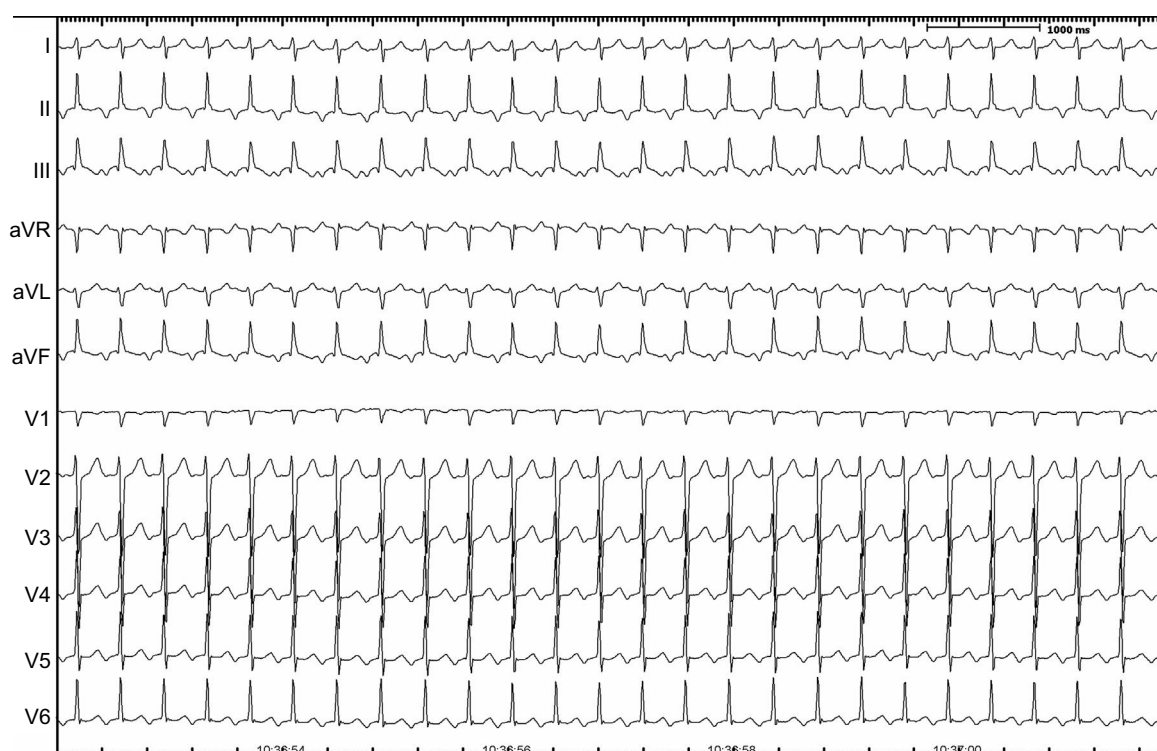


Figure 1.

What do you think was the most likely diagnosis?

1. Focal tachycardia originating in the left superior pulmonary vein
2. Typical slow-fast atrioventricular nodal reentry tachycardia
3. Orthodromic reciprocating tachycardia via an accessory pathway with decremental conduction
4. Inappropriate sinus tachycardia

Submit your answer to <http://www.revespcardiol.org/en/electroreto/72/8>. The solution will be published in the next issue (September 2019). #ECGChallenge #RetoECG.

* Corresponding author:

E-mail address: sofia.caleron@gmail.com (S. Calero-Núñez).