

ECG Contest

ECG, August 2018

ECG de agosto de 2018

Ana Andrés Lahuerta,* Joaquín Osca Asensi, and Víctor José Donoso Trenado

Departamento de Cardiología, Unidad de Arritmias, Hospital Universitario y Politécnico La Fe, Valencia, Spain



The patient was a 53-year-old woman with no cardiovascular risk factors or known heart disease. She had a history of leiomyosarcoma removed surgically in 2010 and received chemotherapy after pulmonary and bone recurrence. Asymptomatic bradycardia had been detected in a previous visit to the clinic; sinus rhythm was observed with ventricular extrasystoles (Figure 1) and bisoprolol 2.5 mg/d was administered. Three weeks later, while still on this treatment, she presented to the emergency room with palpitations and chest pain of sudden onset while sleeping. An ECG was recorded (Figure 2A) and she received 12 mg of adenosine intravenously (Figure 2B).

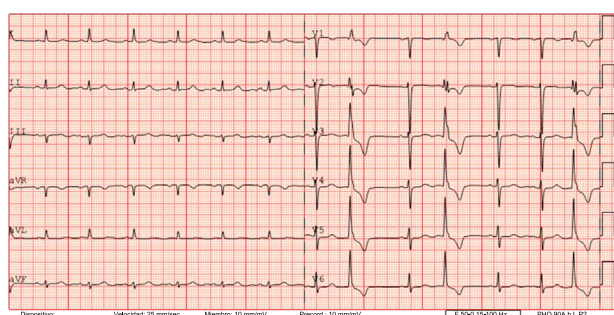


Figure 1.

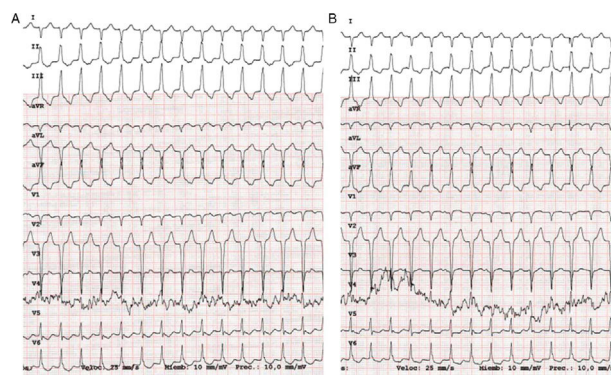

Figure 2.

What was the correct diagnosis and what should the treatment be?

1. Supraventricular tachycardia that did not convert to sinus rhythm with adenosine. A higher dose of adenosine should be administered.
2. Supraventricular tachycardia that did not convert to sinus rhythm with adenosine. Verapamil should be administered.
3. Probable ventricular tachycardia. Adenosine has had no effect on tachycardia.
4. Ventricular tachycardia. Adenosine did not stop the tachycardia, but it did enable diagnosis.

Submit your diagnosis at <http://www.revespcardiol.org/en/electroreto/71/8>. The answer will follow in the next issue (September 2018). #RetoECG.

* Corresponding author:

E-mail address: anaandreslahuerta@gmail.com (A. Andrés Lahuerta).