

ECG Contest

ECG, August 2015

ECG de agosto de 2015

Ramón Bover Freire

Servicio de Cardiología, Hospital Clínico San Carlos, Madrid, Spain



A 36-year-old male smoker had a 4-day history of intense asthenia, general malaise, slight fever and dry cough predominately at night for the past 4 days. He had experienced several presyncope episodes for which he had received antibiotic therapy with amoxicillin and bronchodilators. He finally presented to the emergency department for an episode of oppressive retrosternal chest pain, with stabbing sensation towards his back, and with intense dyspnea. He was admitted for observation to the short-stay ward. The examination revealed signs of mild heart failure and left parasternal pansystolic murmur. Hemoglobin was 10.3 mg/dL; there were no other abnormalities. We were contacted to evaluate this Holter ECG tracing (Figure).

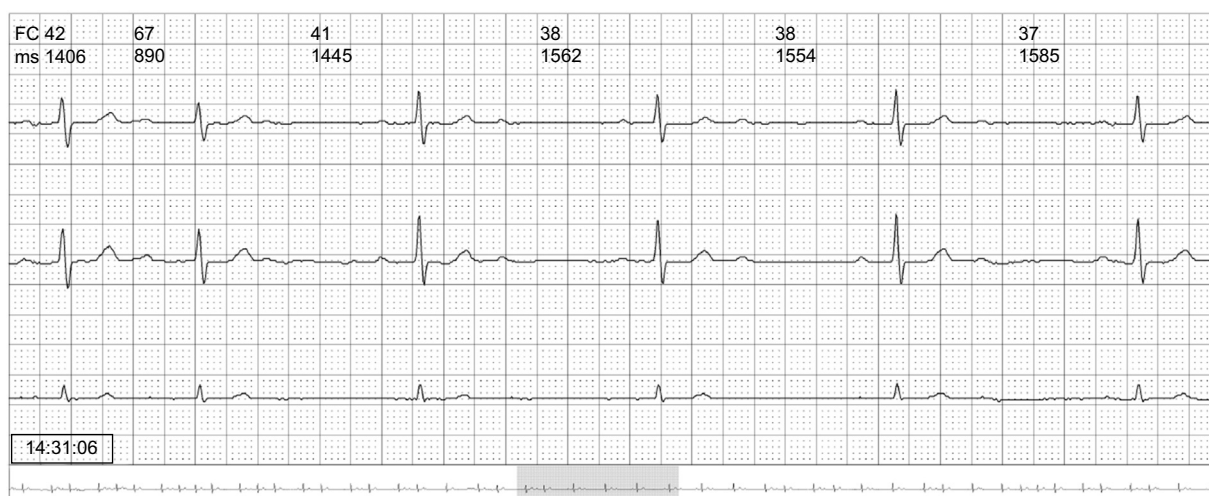


Figure.

Suggest a solution to this ECG Contest at <http://www.revespcardiol.org/es/electroreto/68/08> (only Spanish). The answer will be published in the next issue (September 2015). #RetoECG.

E-mail address: ramonbover@secardiologia.es

<http://dx.doi.org/10.1016/j.rec.2014.10.024>

1885-5857/© 2014 Sociedad Española de Cardiología. Published by Elsevier España, S.L.U. All rights reserved.