

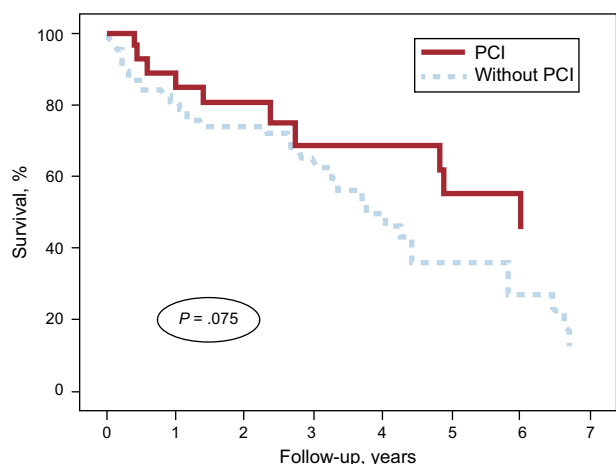Figure. Survival curves for patients with non-ST-segment elevation acute coronary syndrome and severe anemia (hemoglobin < 10 g/dL) at admission, stratified according to whether or not they had undergone PCI, and after adjustment for the GRACE score at discharge. GRACE, Global Registry of Acute Coronary Events; PCI, percutaneous coronary intervention.

adjustment for the GRACE (Global Registry of Acute Coronary Events) score at hospital discharge, and a trend toward a lower mortality rate persisted (HR = 0.52; 95%CI, 0.26–1.07; $P = .075$) (Figure).

Thus, we conclude that, in routine clinical practice, it is not uncommon to encounter patients admitted for NSTEMACS who have severe anemia (3 out of every 100), a comorbidity that will influence the treatment of the coronary event, and most patients are undertreated with respect to currently recommended drug therapy. The prognosis of these patients is frankly poor, with a mortality rate higher than 10% during the hospital stay and greater than 50% at 3 years. The interventional strategy has not been

shown to reduce the high in-hospital mortality rate in this patient population, although there is a trend toward a reduction in long-term mortality.

Sergio Raposeiras Roubín,* Emad Abu-Assi, Diego Iglesias Álvarez, Rocío González Ferreiro, José María García Acuña, and José Ramón González Juanatey

Servicio de Cardiología, Hospital Clínico Universitario de Santiago de Compostela, Santiago de Compostela, A Coruña, Spain

* Corresponding author:

E-mail address: raposeiras26@hotmail.com (S. Raposeiras Roubín).

Available online 29 October 2014

REFERENCES

1. Bodí V, Sanchís J, Llacer A, Fàcil L, Núñez J, Pellicer M, et al. Estrategia invasiva en el síndrome coronario agudo sin elevación del segmento ST. De los grandes estudios al mundo real. Rev Esp Cardiol. 2004;57:1143–50.
2. Mehta SR, Cannon CP, Fox KA, Wallentin L, Boden WE, Spacek R, et al. Routine vs selective invasive strategies in patients with acute coronary syndromes: a collaborative meta-analysis of randomized trials. JAMA. 2005;293:2908–17.
3. Fernández-Ortiz A, Pan M, Alfonso F, Arós F, Barrabés JA, Bodí V, et al. Comentarios a la guía de práctica clínica de la ESC para el manejo del síndrome coronario agudo en pacientes sin elevación persistente del segmento ST. Un informe del Grupo de Trabajo del Comité de Guías de Práctica Clínica de la Sociedad Española de Cardiología. Rev Esp Cardiol. 2012;65:125–30.
4. Ennezat PV, Maréchaux S, Pinçon C, Finzi J, Barrailler S, Bouabdallaoui N, et al. Anaemia to predict outcome in patients with acute coronary syndromes. Arch Cardiovasc Dis. 2013;106:357–65.
5. García-Serrano L, Nogales-Asensio JM, Aranda-López C, García-García P. Incidence and prognosis implication of anemia in patients admitted with acute coronary syndrome. Med Clin (Barc). 2013;140:425–6.

<http://dx.doi.org/10.1016/j.rec.2014.07.012>

Early Treatment of Refractory Cardiogenic Shock With Percutaneous Veno-arterial ECMO Implanted in the Cardiac Catheterization Laboratory



Tratamiento precoz del shock cardiogénico refractario mediante implante percutáneo de ECMO venoarterial en el laboratorio de hemodinámica

To the Editor,

Circulatory support devices such as veno-arterial extracorporeal membrane oxygenation (VA-ECMO) help maintain hemodynamic support and adequate tissue oxygenation, and form part of the therapeutic armamentarium in cardiac arrest and refractory cardiogenic shock.^{1–3} Percutaneous implantation is less invasive than the approach used in other short-term devices, with femoral cannulation most commonly used due to its simplicity and speed.⁴ VA-ECMO can be used as a bridge to recovery or to the decision for a long-term ventricular assist device or heart transplantation. It is in widespread use,³ and experience continues to increase in adult patients in Spain,⁵ where the sole alternative is cardiac surgery.

It is well known that early treatment with appropriate circulatory support is vital in patients with cardiogenic shock.^{1–3} For this reason, in July 2013 we set up a transfemoral percutaneous ECMO implantation program in nonsurgical patients with refrac-

tory cardiogenic shock at our hospital. The interventional cardiologist implanted the CARDIOHELP™ system (MAQUET Cardiopulmonary AG, Germany) in all patients in the cardiac catheterization laboratory, and inpatient care then continued in the cardiac intensive care unit. This article describes the baseline patient characteristics; the indications, duration and management of circulatory support; and progress at follow up.

Between July 2013 and April 2014 VA-ECMO was implanted in 4 consecutive patients with refractory cardiogenic shock, INTERMACS level 1 (critical cardiogenic shock).⁶ Three of these patients had cardiogenic shock following an anterior, inferior and right ventricular myocardial infarction, respectively, and the fourth had a refractory cardiac arrest secondary to an anterior infarction. The baseline characteristics and the clinical progress of the 4 patients are described in the Table. The mean (standard deviation) age was 54.5 (7.4) years. Three patients were male. The mean left ventricular ejection fraction before ECMO implantation was 10% (5%) (n = 3) and the fourth patient had severe right ventricular dysfunction. The decision to implant VA-ECMO was made in the cardiac catheterization laboratory due to poor clinical outcome of the primary percutaneous coronary intervention. An interventional cardiologist performed the cannulation. Implantation was successful in all cases and the mean time to pump initiation was 14 (8–20) minutes. At 24 hours postcannulation, lactic acid levels had dropped from a precannulation baseline of 8.4 (1.7) mmol/L to 2.3 (1) mmol/L ($P < .001$). All patients had previously

Table Baseline Characteristics and Progress of Patients With Venous-arterial Extracorporeal Membrane Oxygenation

Patient	Sex, age, y	HT	DM	PVD	Diagnosis	Baseline LVEF, %	Baseline creatinine, mg/mL	Baseline lactic acid, mmol/L	Lactic acid at 2h, mmol/L	Lactic acid at 24 h, mmol/L	Time between decision and initiation of support, min	Venous cannula, Fr	Arterial cannula, Fr	Infection	ECMO, days	Goal, bridge to	LVEF on discharge, %	Discharge and 100 day survival
1	M, 62	Yes	No	No	inferior AMI, Killip IV	15	1.67	10	2.8	1.3	15	21	17	No	2	CT	60	Yes
2	M, 50	Yes	Yes	Yes	anterior AMI, Killip IV	10	1.7	6	5.4	1.6	20	21	19	Yes	4	Recovery	30	Yes
3	F, 46	Yes	Yes	No	Refractory CPR secondary to anterior AMI	5	0.48	12.5	8.8	5.4	8	21	19	No	6	Recovery	35	Yes
4	M, 59	Yes	Yes	Yes	RV AMI	60	0.87	5.1	3.7	1.1	14	21	19	Yes	8	Recovery	55	Yes

AMI, acute myocardial infarction; CPR, cardiopulmonary arrest; CT, cardiac transplantation; DM, diabetes mellitus; ECMO, extracorporeal membrane oxygenation; F, female; HT, hypertension; LVEF, left ventricular ejection fraction; M, male; PVD, peripheral vascular disease; RV, right ventricular. Patient 1 had a successful heart transplantation, hence normal LVEF on discharge.

had intra-aortic balloon counterpulsation implantation via the contralateral femoral artery. Due to their clinical status, all patients required invasive mechanical ventilation, and a Swan-Ganz catheter for hemodynamic monitoring.

In all patients we achieved the initial goal of providing a bridge to heart transplantation (patient 1), and to recovery (patients 2, 3 and 4). The mean duration of support was 5 (2.5) days, and none of the patients had serious complications such as stroke or lower limb ischemia (in all patients angiography was performed prior to implantation to check that femoral artery size was adequate, and as a guide for cannula size). Two patients (1 and 4) required multiple blood product transfusions, specifically upon initiation of support, with subsequent stabilization, and 2 patients required intravenous antibiotic treatment for infectious complications (Table). We managed to wean 3 patients (75%) off the device, following revascularization and recovery of ventricular function. The other patient (patient 1) required implantation of a Berlin Heart EXCOR biventricular assist device as a bridge to heart transplantation, which was subsequently performed successfully. Survival to discharge and 100-day survival were both 100%. Left ventricular ejection fraction on discharge is shown in the Table.

Our study has the limitations of being single center and having a small sample number. However, our initial experience shows that early implantation of percutaneous VA-ECMO in the cardiac catheterization laboratory, carried out by an interventional cardiologist, in patients with refractory cardiogenic shock secondary to myocardial infarction, is feasible and safe, and avoids dependence on surgical treatment and possible delay in its performance in extreme clinical emergencies. Appropriate patient selection is fundamental, and VA-ECMO implantation probably has a stronger indication in patients with acute and potentially reversible heart failure, as a bridge to recovery, long-term circulatory assist device implantation, or heart transplantation.

FUNDING

This work was partially supported with *Fondo de Desarrollo Regional (FEDER-UE)/Instituto de Salud Carlos III (ISCIII)* and *Red de Investigación Cardiovascular (RIC) RD12/0042*.

Pablo Díez-Villanueva,* Iago Sousa, Alberto Núñez, Felipe Díez, Jaime Elízaga, and Francisco Fernández-Avilés

Servicio de Cardiología, Hospital General Universitario Gregorio Marañón, Facultad de Medicina, Universidad Complutense de Madrid, Instituto de Investigación Sanitaria Gregorio Marañón, Madrid, Spain

* Corresponding author:

E-mail address: pablo_diez_villanueva@hotmail.com (P. Díez-Villanueva).

Available online 30 October 2014

REFERENCES

1. Ghodsizad A, Koerner MM, Brehm CE, El-Banayosy A. The role of extracorporeal membrane oxygenation circulatory support in the 'crash and burn' patient: from implantation to weaning. *Curr Opin Cardiol.* 2014;29:275–80.
2. Anguita M, Comín J, Almenar L, Crespo M, Delgado J, González-Costello J, et al. Comentarios a la guía de práctica clínica de la ESC sobre diagnóstico y tratamiento de la insuficiencia cardiaca aguda y crónica 2012. Un informe del Grupo de Trabajo del Comité de Guías de Práctica Clínica de la Sociedad Española de Cardiología. Grupo de trabajo de la SEC sobre la guía de insuficiencia cardiaca ESC 2012. *Rev Esp Cardiol.* 2012;65:874–8.

3. Paden ML, Conrad SA, Rycus PT, Thiagarajan RR. ELSO Registry. Extracorporeal Life Support Organization Registry Report 2012. *ASAIO J.* 2013;59:202–10.
4. Haneya A, Philipp A, Diez C, Schopka S, Bein T, Zimmermann M, et al. A 5-year experience with cardiopulmonary resuscitation using extracorporeal life support in non-postcardiotomy patients with cardiac arrest. *Resuscitation.* 2012;83:1331–7.
5. Ariza-Solé A, Sánchez-Salado JC, Lorente-Tordera V, González-Costello J, Miralles-Cassina A, Cequier-Fillat A. Asistencia ventricular con membrana de oxigenación extracorpórea: una nueva alternativa al rescate del *shock* cardiogénico refractario. *Rev Esp Cardiol.* 2013;66:501–3.
6. Kirklin JK, Naftel DC, Stevenson LW, Kormos RL, Pagani FD, Miller MA, et al. INTERMACS database for durable devices for circulatory support: first annual report. *J Heart Lung Transplant.* 2008;27:1065–72.

<http://dx.doi.org/10.1016/j.rec.2014.07.013>

Initial Experience With a New Ablation Catheter Using Laser Energy for Electrical Pulmonary Vein Isolation



Experiencia inicial con un nuevo catéter balón de ablación con energía láser para el aislamiento eléctrico de las venas pulmonares

To the Editor,

Catheter ablation is the recommended treatment in patients with paroxysmal atrial fibrillation refractory to antiarrhythmic therapy or with symptomatic persistent atrial fibrillation that cannot be controlled by other therapeutic strategies.¹ The main objective of this procedure is electrical isolation of the pulmonary veins.² The most widely used techniques are point-by-point radiofrequency ablation and cryoablation.² Recently, an ablation system has been introduced that uses laser energy. The catheter, which includes a compliant balloon, enables direct visualization of left atrium and the pulmonary veins to guide the ablation. The first clinical results showed good safety and efficacy.^{3–5} Our objective was to describe the first use of the laser balloon catheter for pulmonary vein isolation in Spain, evaluating its efficacy and safety.

We included patients who underwent ablation of atrial fibrillation between February 2013 and March 2014. All patients signed an informed consent form. We excluded those with a long history of persistent atrial fibrillation or significant structural heart disease.

The ablation system (CardioFocus, Marlborough, Massachusetts, United States) includes the following components (Figure A): a steerable sheath (15 Fr), adaptable to a balloon catheter, with an

adjustable diameter (up to 35 mm) and an atraumatic tip (Figure B); an endoscope (2 Fr); an optical fiber; and a console for selection of the power and duration of the applications. The endoscope and optical fiber are inserted via the balloon catheter. As viewed with the endoscope, blood is red and the tissue in contact with the balloon is white (Figure C); there is a blind area of 45°, making it necessary to rotate the catheter to complete the ablation line. Energy (a 980 nm diode laser) is applied by the optical fiber.

A quadripolar catheter was used to stimulate the phrenic nerve during ablation and an esophageal temperature probe was inserted. Following pulmonary vein angiography, the balloon catheter was introduced and was inflated until the occlusion of each vein was completed. The antral or ostial anatomy was confirmed by the radiological or endoscopic image. The objective was to direct the laser beam as close as possible to the antrum. Each application overlapped the preceding one by 30% to 50% to achieve a continuous ablation line. The energy applied (5.5–12 W) was adjusted according to the expanse of tissue visualized and the presence of blood trapped by the balloon. Once the circumference of each vein had been completely encircled, bidirectional block was confirmed. When conduction persisted, additional applications were carried out in accordance with Lasso[®] catheter recordings.

Forty-two patients underwent laser catheter ablation. The patients' characteristics are summarized in the Table. The pulmonary vein anatomy was normal in 86% of the patients, that of the left common pulmonary vein in 7%, and that of the right common pulmonary vein in 5%. The mean duration (standard deviation) of the procedure was 159 (30) minutes, with a mean fluoroscopy time of 41 (15) minutes. In all, 162 (99%) of the 164 veins included were isolated. Ablation of both ipsilateral veins was accomplished with a single encirclement in 21% of the

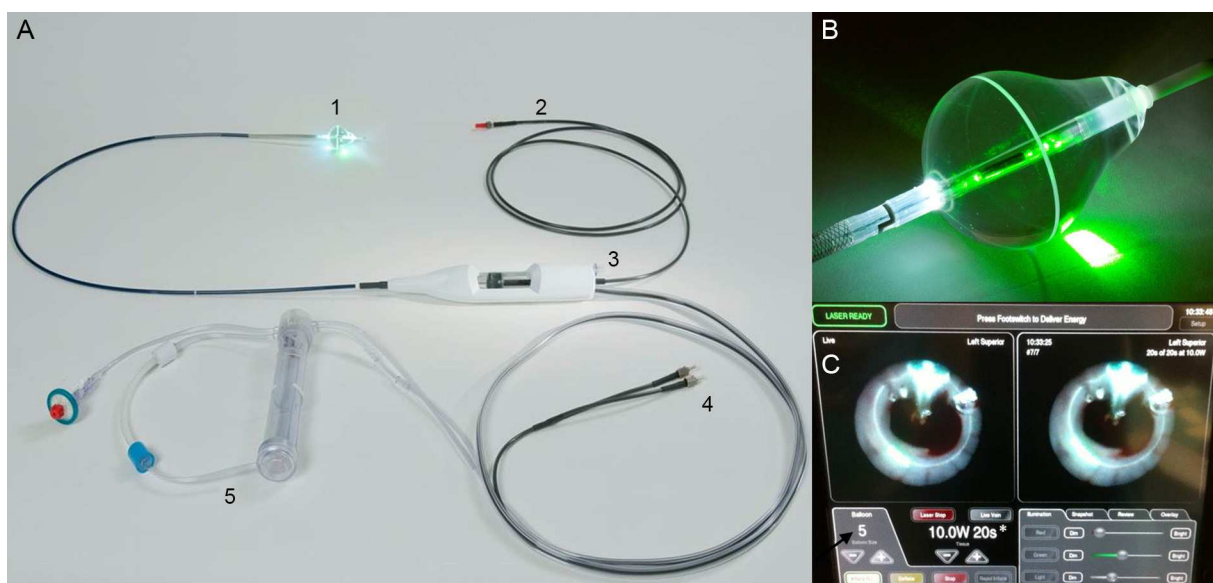


Figure. A: Components of the ablation system. B: Adaptable balloon with soft, atraumatic tip. C: Endoscopic view of pulmonary venous antrum.