

Image in cardiology

# Double Trouble: Concurrent Atrial Fibrillation and Ventricular Tachycardia



Doble problema: fibrilación auricular y taquicardia ventricular simultánea

Carlos A. Espinoza,\* Sanjay Mehra, and Harry DeAntonio

Department of Cardiovascular Sciences, East Carolina Heart Institute at East Carolina University, North Carolina, United States

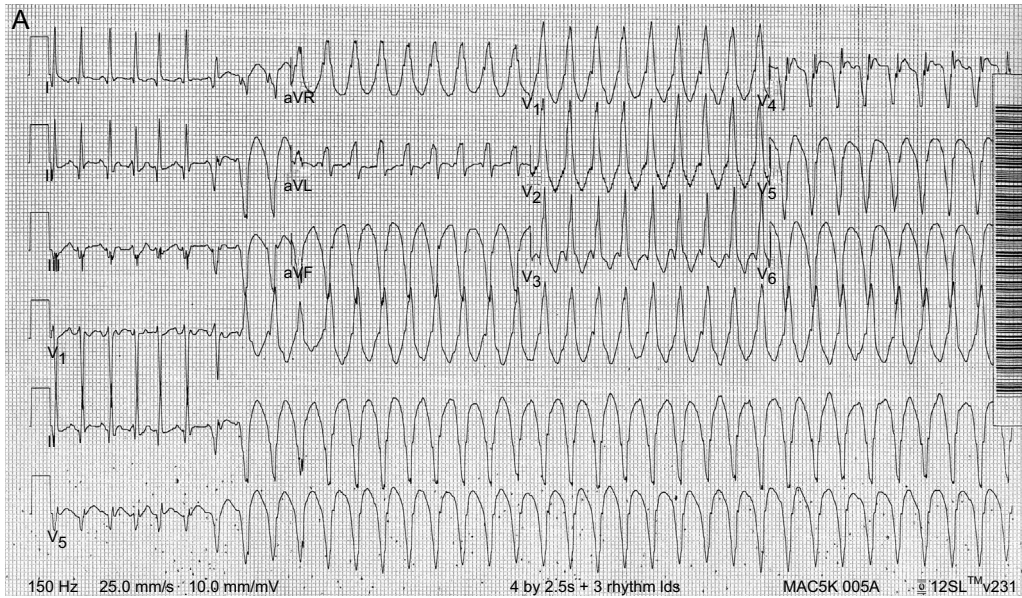
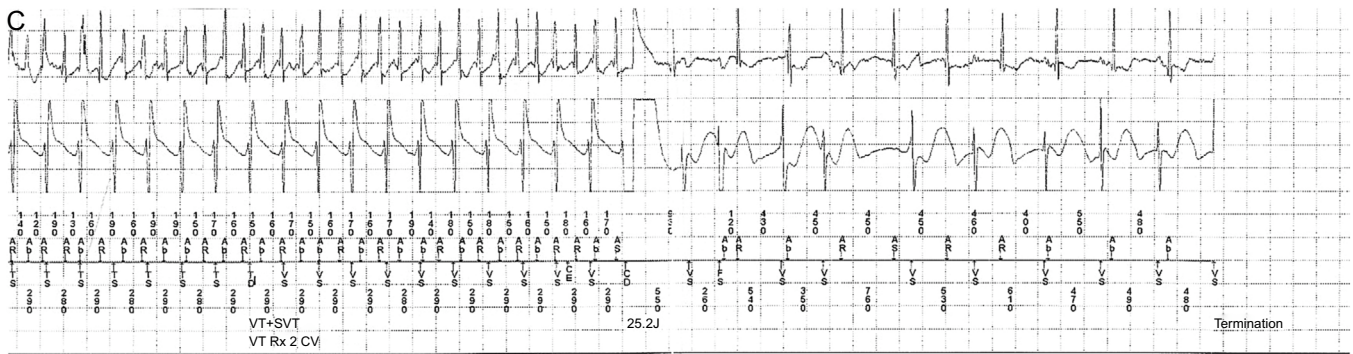


Figure 1.

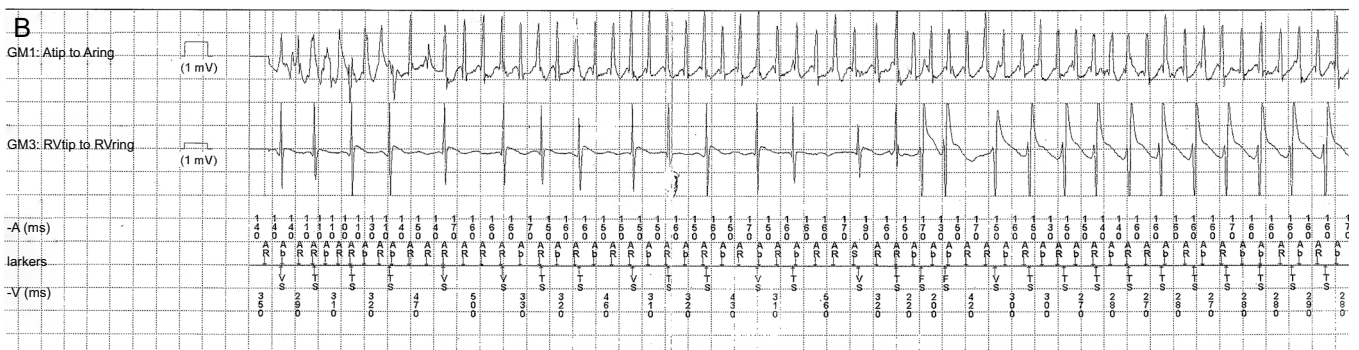

Figure 2.

\* Corresponding author:  
E-mail address: [espinozac@ecu.edu](mailto:espinozac@ecu.edu) (C.A. Espinoza).  
Available online 14 April 2016



**Figure 3.**

A 50-year-old woman with a history of chronic nonischemic systolic heart failure status after implantable cardioverter defibrillator (ICD) placement presented to the emergency department with a history of palpitations and multiple ICD shocks. Her 12-lead electrocardiogram demonstrated narrow complex, irregular tachycardia followed by wide complex tachycardia (Figure 1). The presence of a fusion beat and atrioventricular dissociation suggested ventricular tachycardia (VT). A 150 mg bolus of amiodarone intravenously restored sinus rhythm. Electrolyte and thyroid function tests were within the normal reference range. Echocardiogram showed improvement of ejection fraction from 35% to 50%. The ICD intracardiac electrogram showed more atrial than ventricular activity. The short and variable cycle length of the atrial recording suggested atrial fibrillation. The right ventricular electrogram morphology changed and then accelerated with a relative fixed cycle length suggestive of VT (Figure 2). Both arrhythmias were terminated by 25J discharge (Figure 3). A similar pattern was seen in a total of 14 recorded episodes. Previously disabled antitachycardia pacing was turned on. She had no prior history of atrial fibrillation. In addition to the increase of metoprolol and the start of apixaban, antiarrhythmic therapy was initiated using sotalol. The patient's rhythm and QTc interval was monitored for 72 hours and she was then discharged home in a stable condition. She was doing well when she was seen in the clinic 4 weeks later.

Intracardiac electrogram from pacemaker or ICD can be paramount in the diagnosis of arrhythmias that can have serious consequences if they remain undiagnosed and untreated.