

Does Intracoronary Abciximab Improve the Outcome of Percutaneous Coronary Interventions? A Randomized Controlled Trial

José G. Galache Osuna, Juan Sánchez-Rubio, Isabel Calvo, José A. Diarte, Antonela Lukic, and Luis J. Placer

Unidad de Hemodinámica y Cardiología Intervencionista, Hospital Miguel Servet, Zaragoza, Spain.

Introduction and objectives. It has been clearly demonstrated that abciximab is useful in percutaneous coronary interventions. However, it is not known if intracoronary administration of the initial abciximab bolus improves outcome. Moreover, there may be safety concerns.

Methods. The study was a single-center prospective randomized trial that included all patients undergoing coronary angioplasty involving the use of abciximab. Patients were randomized to either intracoronary or intravenous administration of the abciximab bolus. The primary endpoint was the incidence of major adverse cardiac events (i.e., death, myocardial infarction, or the need for revascularization); secondary endpoints were hemorrhagic complications and the troponin-I level.

Results. The study included 137 patients; 72 received an intracoronary abciximab bolus and 65, an intravenous bolus. Clinical characteristics and baseline angiographic findings were similar in the 2 groups. All patients underwent coronary stent implantation. No difference was observed between the intracoronary bolus group and the intravenous bolus group in type of stent used (drug eluting stent 47.2% vs 50.8%, respectively), total stent length, or final TIMI flow grade (3 vs 2.97, respectively). The intervention success rates were also similar (98.5% vs 99%, respectively). No complication associated with the administration route was reported. However, the level of the myocardial injury marker troponin I increased significantly in the intravenous bolus group. Clinical follow-up at 1 year did not reveal any difference in the incidence of major adverse cardiac events: 8.5% in the intracoronary bolus group versus 6.2% in the intravenous bolus group.

Conclusions. Intracoronary administration of an abciximab bolus did not appear to be less safe or effective than intravenous administration. Less postprocedural myocardial damage was observed in the intracoronary bolus group.

Key words: *Abciximab. Platelet aggregation. Stent. Prospective randomized trial.*

Correspondence: Dr. J.G. Galache Osuna.
Hospital Miguel Servet. Unidad de Hemodinámica. Servicio de
Cardiología.
Isabel la Católica, 1-3. 50009 Zaragoza. España.
E-mail: galaruiz@comz.org

Manuscript received May 24, 2005.
Accepted for publication March 23, 2006.

¿Mejora el uso de abciximab intracoronario el resultado del intervencionismo percutáneo? Estudio prospectivo y aleatorizado

Introducción y objetivos. La utilidad del abciximab en el intervencionismo coronario percutáneo se ha demostrado plenamente. Sin embargo, se desconoce si la administración intracoronaria del bolo inicial puede aportar ventajas. Igualmente, podría haber dudas acerca de su seguridad.

Métodos. Estudio en un solo centro, prospectivo y aleatorizado, en el que se incluyó a todos los pacientes en los que se realizó un intervencionismo coronario percutáneo con abciximab. Se aleatorizó a los pacientes para recibir un bolo de abciximab (ABX) intracoronario o intravenoso. Se analizaron la incidencia de MACE (muerte, reinfarto y necesidad de revascularización) como variable principal y las complicaciones hemorrágicas y las concentraciones de troponina I como variables secundarias.

Resultados. Se incluyó a 137 pacientes (72 con ABX intracoronario y 65 con ABX intravenoso). Las características clínicas y los hallazgos angiográficos fueron similares en ambos grupos. Todos recibieron *stents*. No hubo diferencias en el tipo de *stent* utilizado (recubierto activo del 47,2 frente al 50,8%), la longitud total del *stent* y el flujo TIMI final (3 frente a 2,97). Los resultados del intervencionismo coronario percutáneo fueron similares: se realizó con éxito en el 98,5% de los pacientes del grupo ABX intracoronario y en el 99% del grupo ABX intravenoso. No se detectaron complicaciones derivadas de la vía de administración. En el grupo ABX intravenoso se observó una elevación significativa posprocedimiento de la troponina I. En el seguimiento clínico al año no se hallaron diferencias significativas en la incidencia de MACE (el 8,5% en el grupo ABX intracoronario frente al 6,2% en el grupo ABX intravenoso).

Conclusiones. La administración intracoronaria del bolo de abciximab no parece menos segura que la intravenosa y es, al menos, igualmente eficaz. Se observó un menor grado de daño miocárdico posprocedimiento en el grupo ABX intracoronario.

Palabras clave: *Abciximab. Agregación plaquetaria. Stent. Ensayo prospectivo y aleatorizado.*

ABBREVIATIONS

ABX: abciximab.
AMI: acute myocardial infarction.
PCI: percutaneous coronary intervention.
MACE: major adverse cardiac event.
ACS: acute coronary syndrome.

INTRODUCTION

The results of percutaneous coronary interventions (PCI) have improved continuously since the technique was introduced. Advances in the procedures and materials have been accompanied by a notable development in associated drug treatments.

The use of abciximab (ABX), a murine-human chimeric antibody fragment (c7E3 Fab) that inhibits platelet aggregation by acting selectively on glycoprotein IIb/IIIa receptors,¹ has been one of the most significant advances in drug treatment, and its effectiveness has been demonstrated for PCI in high-risk patients² with complex lesions or requiring multiple stents,^{2,3} in the context of acute myocardial infarction (AMI),⁴ in diabetic patients,^{5,6} with intracoronary thrombus,⁷ etc. The efficacy of the drug has been demonstrated both in the short-term for the reduction of thrombotic complications⁸ and in the medium- to long-term.⁹

Since platelet inhibition caused by ABX occurs immediately, local administration, in this case intracoronary, may act faster and with a greater intensity than intravenous administration, especially in lesions with a greater thrombus load. Little data is available to address this possibility and the majority of the studies that have been performed are neither prospective nor randomized. We have only found 1 randomized controlled trial on the efficacy of intracoronary ABX, but the study was performed selectively in patients in the acute phase of AMI.¹⁰

On the other hand, the incidence of bleeding complications in patients treated with ABX is known to be higher than in patients who do not receive the drug.^{11,12} However, it is not clear whether this varies according to the route of administration.

A randomized, double-blind, controlled trial was therefore designed to assess the safety, efficacy, and possible prognostic benefits of intracoronary versus intravenous administration of ABX.

METHODS

All patients with acute coronary syndrome (ACS) admitted to our hospital between January 1 and November 10, 2004, and in whom PCI was performed with concurrent administration of ABX were

consecutively enrolled in the study. Once the study protocol was accepted by the local ethics committee, the inclusion criteria were as follows: acute coronary syndrome with or without ST-segment elevation in which the use of ABX was indicated and provision of informed consent by the patient.

The exclusion criteria were as follows: *a*) impossibility of stent implantation; *b*) cardiogenic shock; *c*) contraindications for the use of ABX, namely active internal bleeding, hemorrhagic stroke in the last 2 years, recent (2 months) spinal or cranial surgery or trauma, major surgery in the last 2 months, intracranial tumors, aneurysm or arteriovenous malformation, hemorrhagic diathesis or uncontrolled hypertension, preexisting thrombocytopenia, vasculitis, diabetic or hypertensive retinopathy, and severe hepatic or renal failure.

Indication for ABX was assessed on the basis of the guidelines for percutaneous coronary intervention of the European Society of Cardiology¹³:

1. Prior to PCI in high-risk patients with non-ST elevation ACS.
2. High-risk patients with known anatomy 24 hours prior to PCI.
3. All primary PCI, particularly in high-risk patients.
4. In stable angina associated with complex lesions, occlusion or the possibility of occlusion of the vessel, visible thrombus, reduced flow or no-reflow phenomenon, angioplasty with multiple stents, and diabetic patients.

Patients were randomized to receive an initial bolus by intracoronary or intravenous administration. Randomization was performed using a table of random numbers that determined the route of administration of ABX once the indication was established. A double-blind system was used such that neither the patients nor the cardiologists responsible for their assessment and follow-up knew to which group they belonged. In addition, prior to the procedure, the interventional cardiologist who performed the PCI did not know the route of administration of ABX.

The patients included in the study received an initial standard dose of 0.25 mg/kg by intracoronary or intravenous administration. Subsequently, ABX was administered in both groups by intravenous perfusion at a rate of 0.125 µg/kg/min over a 12-hour period.

In all procedures, at least 50 U/kg of unfractionated heparin was provided intravenously and antiplatelet treatment was given with aspirin and clopidogrel. If the patients had not received antiplatelet drugs prior to entering the catheterization laboratory they received 500 mg of aspirin and a 300 mg loading dose of clopidogrel. Treatment with aspirin was continued indefinitely and clopidogrel was continued for at least 6 months.

Catheterization was performed through the radial or femoral artery; in 98% of cases employing the femoral artery, a hemostatic puncture closing device was used. Angiographic success was defined on the basis of less than 30% residual stenosis.

In the majority of patients, markers of myocardial necrosis were assessed before and after (6-8 and 24 hours) the procedure. The marker used was troponin I (TnI) and concentrations were considered to be normal, in our hospital, if they did not exceed 0.05 ng/mL.

Risk factors and clinical signs were analyzed along with angiographic findings associated with the procedure, and clinical follow-up. The main study variable was the incidence of major adverse cardiac events (MACE), defined as death, nonfatal myocardial infarction, and need for repeat revascularization during follow-up. Major vascular complications and elevated postprocedural concentrations of TnI, as a marker of myocardial damage, were considered as secondary variables.

Clinical follow-up was performed by face-to-face or telephone interview of 6 months after the inclusion of the last patient.

The following were considered major vascular complications arising from the procedure and/or ABX treatment: severe hemorrhage (that led to death, had an intracranial or ocular localization, or caused a reduction of more than 5 g/dL in serum hemoglobin or a 15% reduction in hematocrit), acute or subacute vascular occlusion, requirement for transfusion or large hematoma (>6 cm) at the site of catheterization requiring transfusion or surgical repair, clinical evidence of ischemia, and retroperitoneal bleeding.

Statistical Analysis

Statistical analysis was performed using the SPSS program. Continuous variables are expressed as the mean (SD) and categorical variables as percentages. The Student *t* test was used for comparison of quantitative variables and the χ^2 test for qualitative variables.

Treatment efficacy was calculated based on the relative risk of MACE in the group treated with intravenous ABX compared with those receiving intracoronary ABX. An actuarial Kaplan-Meier curve was used to analyze event-free survival in both groups and the log-rank test was used for comparison of survival curves. Confidence intervals (CI) were used at a 95% level and statistical significance was established at $P < .05$.

RESULTS

The study included 137 patients with ACS in whom PCI was performed with ABX treatment; based on a

random assignment of patients, a bolus was given by either intravenous or intracoronary administration. ABX was provided by intracoronary administration in 52% of patients (n=72) and by intravenous administration in 48% (n=65).

The clinical characteristics of the 2 groups were similar (Table 1). The number of patients who received PCI and had ACS with ST-segment elevation was similar in the 2 groups and slightly above 40%, indicating a high incidence of AMI in the patients included in the study. However, the proportion of procedures corresponding to primary or rescue angioplasty was 20.3% in the intracoronary ABX group compared with 17.5% in the intravenous group. Tenecteplase was used as a thrombolytic in all cases. The mean time elapsed following ACS with ST-segment elevation was 4 hours 20 minutes for primary angioplasty and 14 hours 48 minutes for rescue angioplasty, and was similar in both groups.

The indication for PCI in patients with ACS with ST-segment elevation when neither primary nor rescue angioplasty were performed was the presence of at least 1 criterion for poor short- or medium-term prognosis: severe ventricular dysfunction, silent ischemia, suspicion of multiple vessel disease, and early or extensive ischemia in the prognostic test. The mean time elapsed between ACS with ST-segment elevation and the procedure was 5.65 days.

The reason for admission in the remaining 60% of patients was ACS without ST-segment elevation and was similar in the 2 groups.

Table 2 shows the angiographic findings. The number of diseased vessels per patient (2.03 vs 1.97 in the intracoronary and intravenous groups,

TABLE 1. Clinical Characteristics*

	Intracoronary ABX	Intravenous ABX
Age, y	63±5	59.8±12
Men	86%	77%
Smoking habit	41.4%	42.9%
Hypertension	53.6%	60.3%
Diabetes	31.3%	30%
Hyperlipidemia	48.6%	41.3%
ACS with ST-segment elevation	42%	41.3%
Anterior AMI	24%	29%
ACS without ST-segment elevation	58%	58.7%
ACS without ST-segment elevation + normal TnI†	57%	60.3%
Primary PTCA	12.5%	10.5%
Rescue PTCA	7.8%	7%
LVEF	56.5±12	57.8±12

*Data are shown as mean ±SD or percentage.

ABX indicates abciximab; PTCA, percutaneous transluminal coronary angioplasty; AMI, acute myocardial infarction; ACS, acute coronary syndrome; TnI, troponin I; LVEF, left ventricular ejection fraction.

†TnI concentration <0.5 ng/mL.

TABLE 2. Angiographic Findings*

	Intracoronary ABX	Intravenous ABX
Number of diseased vessels	2.03±0.82	1.97±0.76
Number of lesions (264)	132	122
LAD lesion	40.8%	50%
Type B2 or C lesions	74.2%	75.5%
Significant calcification	12.4%	6.1%
Major bifurcation	7.2%	5%
Restenosis	1.5%	0.8%
Visible thrombus	35%	27%
Preprocedural TIMI flow grade 2 to 3	88.7%	89.8%

*Data are shown as mean ±SD or percentage. ABX indicates abciximab; LAD, left anterior descending artery; TIMI, Thrombolysis in Myocardial Infarction.

TABLE 3. Characteristics of the Procedure*

	Intracoronary ABX	Intravenous ABX
Number of lesions treated per patient	1.9±0.4	2.01±0.5
Complete revascularization	62%	70%
Number of stents per lesion	1.09 0.3	1.1 0.3
Stent diameter	3.18 0.42	3.15 (0.48)
Length stent/lesion	22.1 8	21.2 7
Drug-eluting stent	47.2%	50.8%
Postprocedural TIMI flow grade 3	100%	98.3%
Acute occlusion	0	0
Maximum pressure	11.5 2	11.8 2.5

*Data are shown as mean ±SD or percentage. ABX indicates abciximab; TIMI, Thrombolysis in Myocardial Infarction.

respectively) and the number of complex lesions treated, defined as type B2 or C in the American College of Cardiology/American Heart Association classification, were also similar (74.2% vs 75.5%). Angiographically visible thrombi were present in 35% of the group who received intracoronary ABX and 27% of the intravenous ABX group; however, the difference did not achieve statistical significance.

Angiographic success of the procedure was similar in both groups (98.5% vs 99%), without significant differences in other parameters. Table 3 shows the most notable findings. Complete revascularization was obtained in 62% of the intracoronary ABX group and 70% of the intravenous group. No cases of acute occlusion were recorded.

A major vascular complication at the site of femoral puncture requiring surgical intervention or transfusion was produced in each of the groups. In no case was it attributable to the route of administration of the initial ABX bolus.

Clinical Follow-Up

Clinical follow-up was completed in all patients, with a mean follow-up period of more than 1 year (range, 6-21 months). The overall incidence of MACE

was 8.5% in the intracoronary ABX group and 6.2% in the intravenous group. Table 4 shows the distribution of events. Two deaths were recorded in the intracoronary ABX group (1 caused by refractory heart failure in the context of a hip fracture and the other due to cerebral hemorrhage 4 months after the procedure), while 3 occurred in the intravenous group (1 caused by retroperitoneal hematoma, 1 by ischemic stroke, and 1 by cardiogenic shock).

The relative risk (RR) associated with the main variable (MACE) at 6 months in the intracoronary ABX group compared with the intravenous group was 1.204 (95% CI, 0.280-5.177). The RR for the other variables was 0.451 (95% CI, 0.042-4.862) for death and 1.806 (95% CI, 0.168-19.449) for requirement for repeat revascularization. When the RR was calculated for all variables over a longer follow-up period, significant differences between the groups were still not observed.

Certain observations are noteworthy in relation to the patients in whom events were recorded during follow-up. The mean age was 71 years and 60% were women. Half of the patients in whom an event was recorded were diabetic. Multiple vessel disease (2 or more diseased vessels) was present in 90% of those patients and complete revascularization was only achieved in 20% (all of whom were in the intravenous ABX group).

The curves for event-free (MACE) survival in the 2 groups (Figure 1) reveal better initial progress in the group treated by intracoronary bolus (first 130 days) but followed by a greater number of events in that group, such that the survival curve for patients treated by intravenous bolus showed later improvement, without significant differences in the log-rank test ($\chi^2=0.17$; $P=.6809$). Thus, in the analysis of the risk function most MACE in the group treated with intravenous ABX occurred in the first 50 days (4.62% of MACE in the first 50 days), none were seen immediately after that period, an increase to 2.5% was observed in the period between 250 and 300 days, and none were observed after that time. In the group treated with intracoronary ABX, the mean rate of MACE was 3% in the first 50 days, none occurred in the following 50 days, an increase to 3% was seen in the period from 100 to 150 days, 1.5% in the period from 150 to 200 days, 2% between 200 and 250 days, and the rate returned to zero in the remaining follow-up period. The patients included in each 50-day period are shown in Figure 2.

When the subgroup of patients who received primary or rescue PCI was examined (20% of the total), no differences were observed for any of the parameters, either for the procedure or for the incidence of events during follow-up.

Finally, the baseline and postprocedural concentrations of TnI were analyzed in 67 patients, excluding patients with recent AMI and those presenting a significantly elevated TnI concentration prior to the procedure, since in those cases the curve is

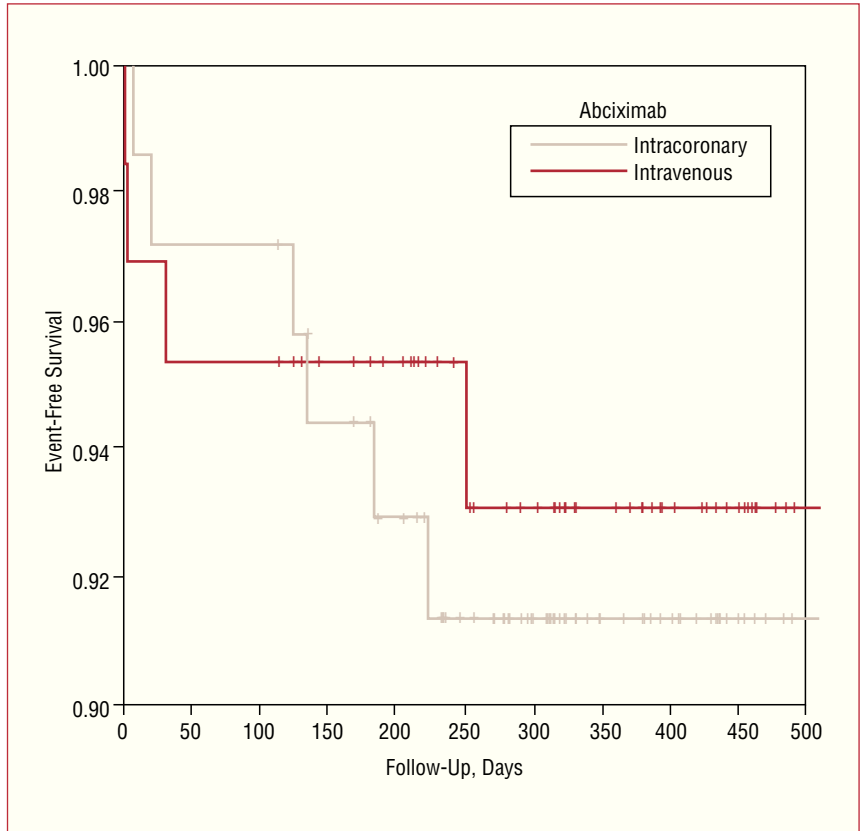


Figure 1. Kaplan-Meier curves for event-free survival (death, reinfarction, and repeat revascularization).

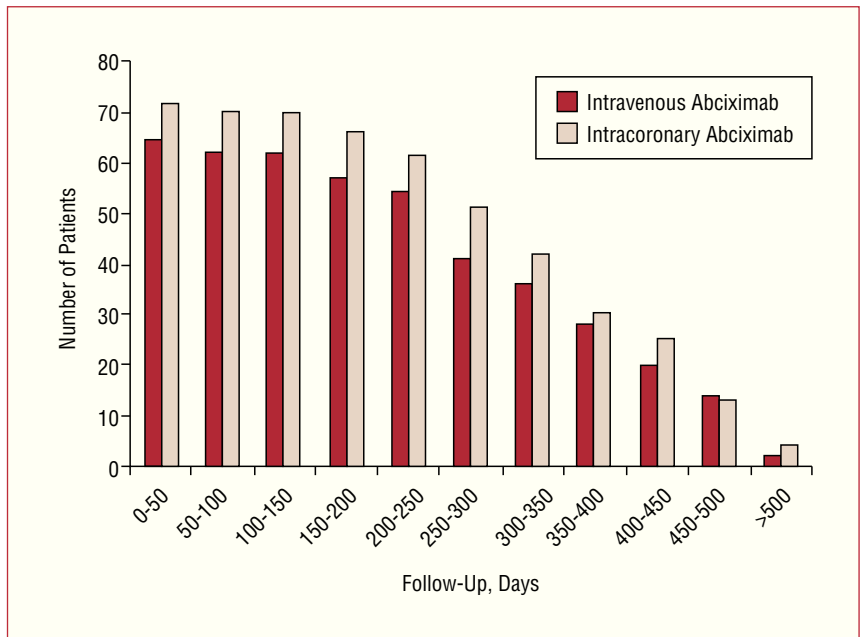


Figure 2. Patients included in each 50-day follow-up period.

difficult to interpret. A significant postprocedural elevation (more than 5 times the upper limit for normal values) was recorded in 51% (15 out of 29 patients) of the intravenous ABX group compared with only 26% (10 out of 38 patients) in the intracoronary group ($P<.05$).

DISCUSSION

Although there is no solid scientific basis, numerous interventional cardiologists use intracoronary ABX when treating lesions in which there is suspicion or angiographic evidence of intracoronary thrombus, in

the belief that administration of the drug in this way will improve its efficacy. Taking advantage of the immediate platelet inhibition provided by ABX, a more rapid and selective local effect would be achieved. However, the evidence in support of this possibility is limited. The aim of this study was therefore to assess the safety and possible benefits of intracoronary versus intravenous administration of ABX.

Numerous studies, both descriptive and randomized, have demonstrated the usefulness of ABX,^{3-5,14} although the majority were performed with an initial intravenous bolus. There are also many studies available on the efficacy of ABX during the acute phase of ACS with ST-segment elevation^{4,15}; however, although our study contains a notable number of such patients, it was not the most common scenario, representing around 20% in each group.

The limited number of studies available comparing intracoronary and intravenous administration of ABX in the context of ACS with or without ST-segment elevation report clear benefit of intracoronary administration, with a reduction in the short-term (30 days)¹⁶ and medium-term¹⁷ incidence of events, although the studies were retrospective. Our results are not consistent with the findings of those studies as we did not observe significant differences in the short-term or medium-term prognosis of these patients.

However, certain elements limit comparison with the studies mentioned: on the one hand, the shorter follow-up periods—30 and 180 days—of the retrospective studies^{16,17} and on the other the high percentage of patients treated in the acute phase of ACS with ST-segment elevation, greater than 70% in the study of Worhrle et al.¹⁶ It should be remembered that in our study only around 20% of the procedures were performed in the acute phase. Furthermore, in the study of Wohrle et al.¹⁶ the differences in the rate of events were essentially obtained in the group of patients with Thrombolysis in Myocardial Infarction (TIMI) flow grade 0 to 1 in the causative artery, and the difference no longer existed when the TIMI flow grade was 2 to 3 (6.7% vs 7.7% events). In our study, the percentage of arteries with a flow grade of 2 to 3 was around 90%, a factor that in our opinion significantly limits comparisons between these studies.

Finally, the study of Kakkar et al,¹⁷ although more similar to our study in terms of length of follow-up and number of patients, has certain baseline characteristics of the study group that are very different from those presented here and thereby limit comparisons: nonhomogeneous groups with notable differences in the number of diabetics, the angiographic data, and the PCI.

We are only aware of 1 study, that of Bellandi et al,¹⁰ with a prospective design, although it was performed selectively for patients with ACS with ST-

segment elevation. In that study, the artery responsible for infarction was occluded (TIMI flow grade 0-1) and a reduction in the size of the infarction (protected myocardium) was achieved, with improved reperfusion in the group with intracoronary administration of ABX. In the study of Bellandi et al, major cardiac events were not considered as principal variables and, as in our study, there appeared to be no differences in such events during short-term follow-up.

According to some authors, the presence of an angiographically identifiable thrombus would be associated with a worse medium-term prognosis.⁵ It is possible that this result would be altered by intracoronary administration of ABX, since information is beginning to be available from some publications to suggest that this route of administration is more effective for the dissolution of thrombi.^{18,19} Given that the presence of thrombi is more common in the context of ACS, it may be that intracoronary ABX is more useful in such cases.

In terms of the results, it is important to note that the percentage of procedures that achieved complete revascularization was 60% in the intracoronary ABX group and 70% in the intravenous group. This situation may have led to an increase in the number of adverse events in the medium to long-term, as in other studies.²⁰ However, the incidence of events in our study is not abnormally elevated (8.5% vs 6.2%) and was similar to that reported in the literature.^{16,21}

The downside of using ABX is the increased incidence of bleeding complications.^{4,11,12,22} In our study, we did not find differences in the incidence of major bleeding complications (systemic or local) following PCI according to the route of administration used. The association between the use of ABX and the increased risk of bleeding would be in relation to the drug itself and the duration of treatment, and would be independent of the route of administration.¹⁷

Studies such as that of Khan et al,²³ in which ABX was only administered intravenously, did not reveal effects on elevation of cardiac enzymes following the procedure in lesions with a high risk of embolism or thrombosis; if a reduction in troponin concentration had been obtained it would have implied less myocardial damage. However, we observed a reduced elevation of markers of myocardial necrosis associated with intracoronary administration of ABX. Bellandi et al¹⁰ obtained similar results in terms of reduced myocardial damage quantified using other parameters. We consider this aspect to be important, given that a correlation between greater elevation of cardiac enzyme concentrations and worse prognosis in PCI has been reported in the literature.^{24,25} The limited number of patients in our study could account for the absence of significant differences in the incidence of events.

A possible cause of the lower myocardial damage associated with intracoronary administration could be

that the greater and more rapid platelet inhibition would mean that the phenomenon of reperfusion would be less damaging to the myocardium.²⁶ This aspect of reduced platelet aggregation along with less distal microembolization^{8,16} and a local anti-inflammatory effect^{8,27} could, in our opinion, represent the benefits of this route of administration.

It remains to be seen how this route of administration could be complemented by the use of new antithrombotic therapies,²⁸ such as low molecular weight heparins, antibodies directed against selected coagulation factors, ximelagatran, etc, and extensive randomized controlled trials will be required to assess their utility.

Limitations of the Study

The group of patients included in this study was heterogeneous and included distinct entities, such as ACS with and without ST-segment elevation. However, this limitation is derived from the population studied and is a reflection of the day to day clinical activity, since all patients with ACS and an indication for ABX treatment were consecutively enrolled in the study.

Another limitation of the study is that the final power was notably lower than expected and less than 15% (11.1%), due in part to the predicted percentage of events being markedly lower than those of the previously published studies on which the estimate was based. Consequently, the total number of patients included, which was already relatively low compared to the ideal, was lower than predicted. Randomized controlled trials with a larger number of patients and strict selection criteria will be necessary to support the results obtained here.

CONCLUSIONS

Intracoronary administration of ABX does not appear to be less safe than intravenous administration, and it may be at least as effective. In addition, and taking into account the limitations mentioned, it would have the added benefit of reducing myocardial damage.

REFERENCES

1. Topol EJ. Prevention of cardiovascular ischemic complications with new platelet glycoprotein IIb/IIIa inhibitors. *Am Heart J*. 1995;130:666-72.
2. Genetta TB, Mauro VF. ABCIXIMAB: a new antiaggregant used in angioplasty. *Ann Pharmacother*. 1996;30:251-7.
3. Galassi AR, Russo G, Nicosia A, Tamburino C, Foti R, Rodi G, et al. Usefulness of platelet glycoprotein IIb/IIIa inhibitors in coronary stenting for reconstruction of complex lesions: procedural and 30 day outcome. *Cardiologia*. 1999;44:639-45.
4. Brener SJ, Barr LA, Burchenal JE, Katz S, George BS, Jones AA, et al. Randomized, placebo-controlled trial of platelet glycoprotein IIb/IIIa blockade with primary angioplasty for acute myocardial infarction. RAPPOR Investigators. *Circulation*. 1998;98:734-41.
5. Domínguez Franco A, Jiménez-Navarro MF, Alonso Briales JH, Curiel Balsera E, Gómez Doblas JJ, de Teresa Galván E, et al. ¿El abciximab mejora el pronóstico de los diabéticos tras la intervención coronaria percutánea? *Rev Esp Cardiol*. 2002;55:810-5.
6. Bhatt DL, Marso SP, Lincoff AM, Wolski KE, Ellis SG, Topol EJ. Abciximab reduces mortality in diabetics following percutaneous coronary intervention. *J Am Coll Cardiol*. 2000;35:922-8.
7. Khan MM, Ellis SG, Aguirre FV, Weisman HF, Wildermann NM, Califf RM, et al. Does intracoronary thrombus influence the outcome of high risk percutaneous transluminal coronary angioplasty? Clinical and angiographic outcomes in a large multicenter trial. EPIC Investigators. Evaluation of IIb/IIIa Platelet Receptor Antagonist 7E3 in Preventing Ischemic Complications. *J Am Coll Cardiol*. 1998;31:31-6.
8. Patrono C, Bachmann F, Baigent C, Bode C, de Caterina R, Charbonier B, et al. Documento de consenso de expertos sobre el uso de agentes antiplaquetarios. *Rev Esp Cardiol*. 2004;57:963-80.
9. Topol EJ, Ferguson JJ, Weisman HF, Tchong JE, Ellis SG, Kleiman NS, et al. Long-term protection from myocardial ischemic events in a randomized trial of brief integrin beta3 blockade with percutaneous coronary intervention. EPIC Investigators. Evaluation of Platelet IIb/IIIa Inhibition for Prevention of Ischemic Complication. *JAMA*. 1997;278:479-84.
10. Bellandi F, Maioli M, Gallopin M, Tosso A, Dabizzi RP. Increase of myocardial salvage and left ventricular function recovery with intracoronary abciximab downstream of the coronary occlusion in patients with acute myocardial treated with primary coronary intervention. *Catheter Cardiovasc Interv*. 2004;62:186-92.
11. Kereiakes DJ, Lincoff AM, Miller DP, Tchong JE, Cabot CF, Anderson KM, et al. Abciximab therapy and unplanned coronary stent deployment: favorable effects on stent use, clinical outcomes, and bleeding complications. EPILOG Trial Investigators. *Circulation*. 1998;97:857-64.
12. Foster RH, Wiseman LR. Abciximab. An updated review of its use in ischemic heart disease. *Drugs*. 1998;56:629-65.
13. Silver S, Albertsson P, Fernández-Avilés F, Camiri P, Colombo A, Hamm C, et al (Grupo de Trabajo de la Sociedad Europea de Cardiología). Guías de Práctica Clínica sobre intervencionismo coronario percutáneo. *Rev Esp Cardiol*. 2005;58:679-728.
14. Lincoff AM, Califf RM, Anderson KM, Weisman HF, Aguirre FV, Kleiman NS, et al. Evidence for prevention of death and myocardial infarction with platelet membrane glycoprotein IIb/IIIa receptor blockade by abciximab (c7E3 Fab) among patients with unstable angina undergoing percutaneous coronary revascularization. EPIC Investigators. Evaluation of 7E3 in Preventing Ischemic Complications. *J Am Coll Cardiol*. 1997;30:149-56.
15. de Queiroz Fernandes JO, Veloso HH, Braga de Paiva JM, Filho MW, Vincenzo de Paola AA. Efficacy and safety of abciximab on acute myocardial infarction treated with percutaneous coronary interventions: a meta-analysis of randomized, controlled trials. *Am Heart J*. 2004;148:937-43.
16. Wohrle J, Grebe OC, Nusser T, al-Khayer E, Schaible S, Kochs M, et al. Reduction of major adverse cardiac events with intracoronary compared with intravenous bolus application of abciximab in patients with acute myocardial infarction or unstable angina undergoing coronary angioplasty. *Circulation*. 2003;107:1840-3.
17. Kakkar AK, Moustapha A, Hanley HG, Weiss M, Caldito G, Misra P, et al. Comparison of intracoronary vs. intravenous administration of abciximab in coronary stenting. *Catheter Cardiovasc Interv*. 2004;61:31-4.
18. Hang Lee, C, Thye Ho K, Cheem Tan H. Instant dissolution of intracoronary thrombus by abciximab. *Int J Cardiol*. 2005;104:102-3.

19. Delcán Domínguez JL, García Fernández E, Guerrero Sanz JE. Rápida lisis de gran trombo coronario con abciximab. *Rev Esp Cardiol.* 2002;55:536.
20. Jiménez-Navarro MF, Curiel E, Hernández García JM, Alonso Briales JH, Domínguez Franco A, Gómez Doblas JJ, et al. Influencia de la diabetes mellitus en los resultados clínicos tras revascularización coronaria percutánea. *Rev Esp Cardiol.* 2002; 55:365-71.
21. Bourassa MG, Kip KE, Jacobs AK, Jones RH, Sopko G, Rosen A, et al. Is a strategy of intended percutaneous transluminal coronary angioplasty revascularization acceptable in nondiabetic patients who are candidates for coronary artery bypass graft surgery? *J Am Coll Cardiol.* 1999;33:1627-36.
22. Lenderink T, Boersma E, Ruzyllo W, Widimsky P, Ohman EM, Armstrong PW, et al. GUSTO IV-ACS. Bleeding events with abciximab in acute coronary syndromes without early revascularization: an analysis of GUSTO IV-ACS Investigators. *Am Heart J.* 2004;147:865-73.
23. Khan MA, Liu MW, Chio FL, Yates VB, Chapman GD, Misra VK, et al. Effect of abciximab on cardiac enzyme elevation after transluminal extraction atherectomy (TEC) in high-risk saphenous vein graft lesions: comparison with a historical control group. *Catheter Cardiovasc Interv.* 2001;52:40-4.
24. Simoons ML, Van den Brand M, Lincoff M, Harrington R, van der Wieken R, Vahanian A, et al. Minimal myocardial damage during coronary intervention is associated with impaired outcome. *Eur Heart J.* 1999;20:1112-9.
25. Kini AS, Richard M, Suleman J, Perez N, Lee P, Fisher EA, et al. Effectiveness of tirofiban, eptifibatid, and abciximab in minimizing myocardial necrosis during percutaneous coronary intervention (TEAM pilot study). *Am J Cardiol.* 2002;90:526-9.
26. Férrez Santander SM, Márquez MF, Peña Duque MA, Ocaranza Sánchez R, de la Peña Almaguer E, Eid Lidt G. Daño miocárdico por reperfusión. *Rev Esp Cardiol.* 2004;57:9-21
27. Simon DI, Xu H, Ortlepp S, Rogers C, Rao NK. 7E3 monoclonal antibody directed against the platelet glycoprotein IIb/IIIa cross-reacts with the leukocyte integrin Mac-1 and blocks adhesion to fibrinogen and ICAM-1. *Arterioscler Thromb Vasc Biol.* 1997;17:528-35.
28. Antman EM. Presente y futuro del tratamiento antitrombótico en el síndrome coronario agudo. *Rev Esp Cardiol.* 2003;56:115-20.