

## Dobutamine Stress Echocardiography and Troponin T as a Marker of Myocardial Injury

Gemma Pastor, José Alberto San Román, Manuel González-Sagrado<sup>a</sup>, José Luis Vega, María Luisa Arranz<sup>a</sup>, Ana María Serrador, Valeriu Epureanu, Raquel Teresa Palomino, Olga Sanz, Paula Tejedor and Francisco Fernández-Avilés

Instituto de Ciencias del Corazón (ICICOR). Hospital Universitario. <sup>a</sup>Servicio de Análisis Clínicos. Hospital Río Hortega. Valladolid. España.

**Introduction and objectives.** Troponin T (TnT) is a very specific marker of myocardial damage. Our objective was to describe TnT behavior after dobutamine stress echocardiography (EDOB) and evaluate its usefulness for improving the diagnostic power of EDOB.

**Methods.** Blood levels of TnT were measured at baseline and 3, 6, 12, and 24 h after EDOB in 63 patients (mean age:  $69 \pm 9$ ; 38 males). Coronary angiography was performed on 36 patients.

**Results.** EDOB was positive in 29 patients and there was an increase over baseline values in 15 of them (51%); EDOB was negative in 34 patients and there was only a rise in TnT in 7 (20%;  $p < 0.01$ ). The TnT increment was higher in patients with a positive response to EDOB ( $0.033 \pm 0.02$  vs.  $0.026 \pm 0.01$ ;  $p < 0.01$ ). The ischemia score index was higher in patients in which a significant increase in TnT values was later detected ( $0.41 \pm 0.31$  vs.  $0.38 \pm 0.20$ ;  $p < 0.01$ ). Coronariography was performed in 36 patients. EDOB was positive in 22 of the 29 patients with coronary artery disease (76%) and TnT was raised in 14 of them (48%;  $p < 0.05$ ).

**Conclusion.** The rise in TnT levels during EDOB suggests that this test may produce myocardial damage associated with the appearance of contractility disorders during dobutamine infusion.

**Key words:** *Dobutamine. Stress echocardiography. Troponin. Coronary disease.*

Full English text available at: [www.revespcardiol.org](http://www.revespcardiol.org)

### Ecocardiografía de estrés con dobutamina y troponina T como marcador de daño miocárdico

**Introducción y objetivos.** La troponina T (TnT) es un marcador muy específico de daño miocárdico. Nuestro objetivo fue describir el comportamiento de la TnT después de la realización de la ecocardiografía con dobutamina (EDOB) y valorar su utilidad para mejorar el poder diagnóstico de la EDOB.

**Métodos.** Los niveles en sangre de TnT fueron obtenidos basalmente y a las 3, 6, 12 y 24 h después de hacer una EDOB en 63 pacientes (edad media:  $69 \pm 9$  años; 38 varones). Se realizó coronariografía en 36 de ellos.

**Resultados.** La EDOB fue positiva en 29 pacientes y en 15 de ellos hubo un incremento de TnT respecto a los niveles basales (51%); la EDOB fue negativa en 34 pacientes y sólo en 7 se elevó la TnT (20%;  $p < 0,01$ ). El incremento de los valores de TnT fue superior en pacientes con respuesta positiva a la EDOB ( $0,033 \pm 0,02$  frente a  $0,026 \pm 0,01$ ;  $p < 0,01$ ). El índice de isquemia durante la EDOB fue mayor si se detectaba posteriormente una elevación significativa de los valores de TnT ( $0,41 \pm 0,31$  frente a  $0,38 \pm 0,20$ ;  $p = 0,01$ ) durante la EDOB. Los pacientes que presentan una elevación significativa de TnT tienen mayor frecuencia de cambios en el ECG (92 frente al 34%;  $p < 0,01$ ) y angina (42 frente al 9%;  $p < 0,01$ ) durante la EDOB. Realizamos coronariografía en 36 pacientes. De los 29 pacientes con enfermedad coronaria hubo 22 con EDOB positivo (76%) y 14 con elevación de TnT (48%;  $p < 0,05$ ).

**Conclusión.** La elevación de la TnT durante la EDOB indica que esta prueba puede provocar daño miocárdico que se asocia a la aparición de alteraciones de la contractilidad durante la administración de dobutamina.

**Palabras clave:** *Dobutamina. Ecocardiografía de estrés. Troponina. Enfermedad coronaria.*

See editorial on pages 463-5

Correspondence: Dr. J.A. San Román.  
Instituto de Ciencias del Corazón (ICICOR). Hospital Universitario.  
Ramón y Cajal, 3. 47011 Valladolid. España  
E-mail: jsancal@nexo.es

Received 27 August 2001.  
Accepted for publication 4 January 2002.

## ABBREVIATIONS

PTCA: percutaneous transluminal coronary angioplasty  
 EDOB: dobutamine stress echocardiography  
 TnT: cardiac troponin T  
 CAD: coronary artery disease

## INTRODUCTION AND OBJECTIVES

In recent years dobutamine stress echocardiography (EDOB) has become one of the combination of tests that are used routinely in the diagnosis and prognosis of patients who consult for chest pain or known coronary artery disease.<sup>1</sup> The response of the myocardium to dobutamine infusion is useful not only in the diagnosis of coronary artery disease (CAD), but also in evaluating its severity. The ischemia threshold determined by the ischemia-free time and the dilation of the left ventricle with peak stress have been correlated with its severity.<sup>2</sup> We must be aware, nonetheless, of some of the limitations of the technique. In the first place, the sensitivity of EDOB is moderate and approximately 20% of patients with CAD have a negative EDOB;<sup>3</sup> in second place, there is no truly quantitative approach to the analysis of results. Finally, it would be interesting to find more precise signs to establish the severity of CAD, which would help in decisions regarding invasive evaluations in high-risk patients.

Recently it has been demonstrated that troponin T (TnT) is a very trustworthy marker of myocardial damage.<sup>4-8</sup> However, there is hardly any information available about its behavior after EDOB.<sup>9-12</sup> Our hypothesis is that measurement of TnT after the infusion of dobutamine could increase the diagnostic power of EDOB and increase the capacity of the test to identify patients with severe CAD. We report the results obtained in a cohort of 63 patients in whom EDOB was performed and TnT was measured in blood at baseline and in the 24 h after the stress test.

## METHODS

Serial TnT measurements were made in 63 patients who underwent EDOB for a clinical indication (mean age 69±9 years, 38 men). Of the 63 patients, 31 had known CAD and 32 had suspected CAD; 19 had a history of previous myocardial infarction. As far as coronary risk factors were concerned, 40 were hypertensive, 31 dyslipidemic, 18 diabetic, and 19 smokers. Coronary angiography was performed in 36 patients. The decision to carry out angiography was

taken by the referring cardiologist, who had the results of EDOB.

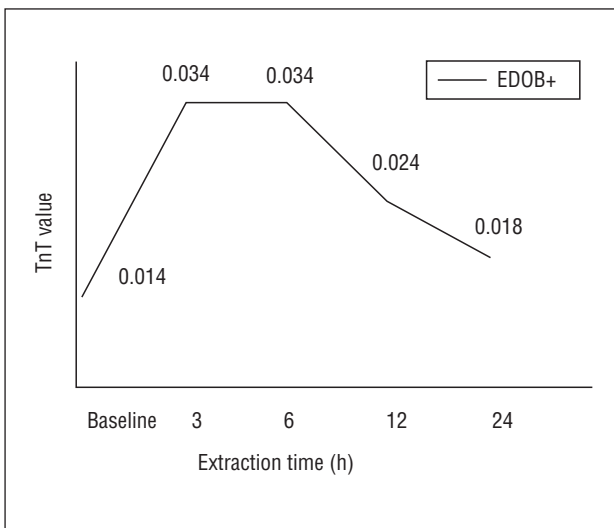
## Echocardiography with dobutamine

Monitoring with bidimensional echocardiography was carried out during the infusion of dobutamine and up to 10 min after it finalized. In the first 40 patients, dobutamine was administered with a continuous infusion pump, beginning with 10 g/kg/min and increasing by 10 g/kg/min every 3 min until reaching a maximum dose of 40 g/kg/min, which was maintained for 6 min. In the last 23 patients a short protocol was used.<sup>13</sup> The short protocol consisted of two stages lasting 3 min each, at a rhythm of perfusion of 20 g/kg/min for the first stage and 40 g/kg/min for the second stage; therefore, the maximum dose was the same. If the patient had not reached 85% of maximum heart rate or any criterion for discontinuing the test when finishing the dobutamine infusion, 1 mg of atropine was administered. A 12-lead electrocardiogram was recorded and blood pressure was taken in baseline conditions and every 3 min up to 10 min after either concluding the infusion or obtaining negative test results, if it had been positive. The criteria for discontinuation were routine: reaching maximum theoretical heart rate, intense angina, appearance of ventricular arrhythmia complexes, systolic blood pressure over 220 mm Hg or diastolic blood pressure over 130 mm Hg, and Mobitz II second-degree or third-degree atrioventricular block.

The division of the segments is that proposed by the American Society of Echocardiography,<sup>14</sup> which includes 16 segments. These segments were studied on the parasternal long axis and short axis using the apical four-chamber, three-chamber, and two-chamber planes. Each segment was scored from 1 to 4 according to its mobility: 4, dyskinesia or akinesia; 3, severe hypokinesia; 2, mild hypokinesia, and 1, normal or hyperkinesia. The sum of the segmental scores was divided by the number of segments visualized to calculate the ventricular mobility score index. This is a semiquantitative indicator of left ventricular systolic function. The test was considered positive when the contractility of any of the segments worsened with respect to baseline contractility. Image acquisition was synchronized with the electrocardiographic signal. Images were digitized for analysis. The studies were also recorded by conventional video.

## Measurement of cardiac troponin T

TnT determinations in serum were made using the Elecsys 1010 system of Boehringer Mannheim. The technique uses Troponin T STAT Elecsys reagents and third-generation calipers. The limit of detection for the



**Fig. 1.** The behavior of troponin T (TnT) levels in time; it is evident that there is an increment in TnT values with respect to baseline value and that a peak value is reached between 3 h and 6 h after performing dobutamine stress echocardiography (EDOB).

technique is 0.01 ng/ml. The upper limit of the reference interval in healthy individuals (99%) is 0.01 ng/ml, according to information facilitated by the manufacturer. Samples were extracted by peripheral venous puncture and left at room temperature until the clot formed, then frozen at 20°C. They were analyzed in series corresponding to each patient after thawing. We considered, in accordance with the standards of the National Academy of Clinical Biochemistry,<sup>4</sup> that the elevation of TnT was significant if baseline TnT was less than 0.01 and in later determinations it was higher than 0.01, or if baseline TnT is above 0.01 and in later determinations the value is 20% higher than baseline value.

*Coronary angiography*

Coronary angiography was performed according to the Judkins technique. We defined severe CAD as the presence of stenosis of more than 50% measured by quantitative angiography. The quantitative analysis of lesions was made with the Coronary Measurement System (CMS) of Medis, which is a digitized system for automatic measurement of edges.

**RESULTS**

*Behavior of cardiac troponin T*

Baseline TnT values were unappreciable in 26 patients; in the other 37, mean baseline TnT was 0.017±0.024. After EDOB, the following TnT levels were obtained: 0.034±0.023 at 3 h; 0.034±0.019 at 6 h; 0.024±0.028 at 12 h, and 0.018±0.022 at 24 h. In

Figure 1 is shown the behavior in time of the serum TnT levels. There were no differences in the behavior of TnT in the patients in which the usual protocol for dobutamine infusion was used and in those in which the short protocol was used. The TnT values in the first 40 patients were: baseline, 0.01±0.017; 3 h, 0.029±0.019; 6 h, 0.031±0.013; 12 h, 0.017±0.020, and 24 h, 0.012±0.018. For the last 23 patients, we obtained mean values of: baseline, 0.029±0.03; 3 h, 0.048±0.05; 6 h, 0.046±0.03; 12 h, 0.039±0.04, and 24 h, 0.032±0.02.

*Relation between dobutamine stress echocardiography and cardiac troponin T levels (Table 3)*

Of the 29 patients with positive EDOB, 15 showed TnT elevation in relation to the baseline values (51%). The EDOB was negative in the other 34 patients and TnT increased in only 7 of them (20%; *P*<.01) (Table 1). The increment in TnT values (difference between peak TnT - baseline TnT) was greater in patients with a positive response to EDOB (0.033±0.02 versus 0.0263±0.01; *P*<.01). A greater index of ischemia was observed in patients with a positive EDOB and significant increment in TnT levels (0.41±0.31 versus 0.38±0.20; *P*=.01). The correlation was 0.44 (*P*<.05). The patients who presented an elevation in TnT showed ECG changes more frequently (92% versus 34% ; *P*<.01) and angina (42% versus 9%; *P*<.01) during EDOB.

**TABLE 1. Relation between the results of dobutamine stress echocardiography (EDOB) and troponin T (TnT) measurement**

	TnT+	TnT-
EDOB+	15/29=51%	14/29=49%
EDOB-	7/34=20%	27/34=80%

*P*<.01.

**TABLE 2. Relation between the results of dobutamine stress echocardiography (EDOB) and troponin T (TnT) measurement and the presence of coronary artery disease (CAD) in coronary angiography**

	CAD	No CAD
EDOB+	22	2
EDOB-	7	5
TnT+	14	1
TnT-	15	6
EDOB+ and/or TnT+	25	2
EDOB and TnT-	4	5

**TABLA 3. Comparison of the clinical, angiographic, and dobutamine stress echocardiography (EDOB) characteristics in relation to the presence of an increment in TnT levels (Troponin+) or absence of an increment (Troponin-)**

	Troponin+	Troponin-	P
Age	69	69	NS
Previous infarction	33%	29%	NS
Unstable angina	57%	51%	NS
Positive EDOB	68%	34%	NS
Ischemia-free time	12±2 min	12±2 min	NS
Baseline score	1.18±0.2	1.40±0.5	<.1
Peak score	1.7±0.42	1.5±0.3	NS
Ischemia index	0.41±0.3	0.383±0.2	NS
Atropine	72%	87%	NS
Angina	42%	34%	<.01
ST changes	92%	34%	<.01
Catheterization	75%	63%	NS
Coronary artery disease	93%	71%	NS
Multivessel	60%	38%	NS

#### Coronary angiography

Coronary angiography was performed in 36 patients, of whom 29 had CAD. The EDOB was positive in 24 patients (22 with coronary artery disease) and TnT rose in 15 patients (14 with CAD). Therefore, 76% of the patients with CAD had positive EDOB versus 48% in which TnT rose ( $P<.01$ ). Of the 29 patients with CAD, 25 (86%) had positive EDOB and/or elevation of TnT (Table 2).

## DISCUSSION

The most important finding of this study is that dobutamine infusion at the doses used in stress echocardiography can induce myocardial damage, as demonstrated by an increase in serum levels of TnT with respect to baseline values. The increase in TnT levels was mild, so the damage to the myocardium can be considered minimal. Another interesting aspect of the study is that TnT did not increase after 24 h of dobutamine infusion. The increasing-decreasing TnT curve, with a peak located 3h to 12 h after dobutamine infusion, is a sure marker of myocardial damage.<sup>15,16</sup> The behavior in time of TnT levels observed coincided with other studies,<sup>17,18</sup> in which a peak TnT was obtained around 10 h after the onset of ischemia, and normal values 20 h after the ischemic episode.

Theoretically, TnT could identify a group of patients with more severe CAD in which a more interventionist attitude should be adopted, including a possible revascularization procedure. This aspect has not been assessed in the literature.

A special group was made up of patients with negative EDOB but with an increment in TnT. No definitive inferences can be drawn from a group of 7

patients, but all the patients pertaining to this group who had a coronary angiography study ( $n=3$ ) had significant CAD. These patients could have had CAD that was not detected by EDOB. Conceptually, subendocardial ischemia may not induce asynergy, although TnT could increase. On the other hand, localized ischemia may not be visible during echocardiographic analysis in patients with a deficient acoustic window.

Troponin has been determined after EDOB in two studies. Meluzin et al<sup>9</sup> did not find any increment in TnT in 27 patients with CAD, but they used a qualitative test to determine TnT and made only one venous sample 20 h after dobutamine was given. As we have seen in our results, TnT can return to normal values by this time. Beckmann et al<sup>11</sup> observed that troponin I did not increase over the range of reference (0.60 ng/mL) in 20 patients with CAD and regional contractility disturbances. The samples were made within 7 h of EDOB. We found that elevation took place in almost all of them between 3 and 12 h. Taking 5 blood samples for TnT measurements is not feasible in outpatients. According to our results, 14% of the patients in whom TnT rose had normal values at 3h and 23% at 6 h. Studies should be made to determine if there is an time interval between 3 h and 6 h in which most of the patients are detected.

If we follow the new definition of infarction recommended by the European Society of Cardiology and the American College of Cardiology,<sup>19</sup> 6 patients had a myocardial infarction after EDOB was performed. This definition is being questioned in broad sectors of the scientific community.<sup>20,21</sup> In order to be accepted definitively, would it be necessary to stop performing stress tests for the diagnosis of CAD? This engrossing question is far from being answered.

We recognize that no definitive conclusions can be established about the usefulness of assessing TnT levels after EDOB, but our work opens a new area of investigation in the exciting field of the noninvasive diagnosis of coronary artery disease. From a practical vantagepoint, the combination of EDOB and the TnT determination could help us to ascertain if a patient has coronary artery disease. In addition, TnT values could provide a better prognostic profile of these patients. Increased TnT levels could be used to support the decision to perform coronary angiography, since they suggested more severe CAD.

## CONCLUSION

After the infusion of dobutamine in the doses administered in EDOB, mild myocardial damage takes place, as demonstrated by TnT elevation. The combination of the results of EDOB and TnT could improve the diagnostic performance of isolated EDOB.



## REFERENCES

- San Román JA, Rollán MJ, Vilacosta I, Castillo JA, Meroño E, Hernández M, et al. Ecocardiografía y gammagrafía con MIBI-SPECT durante la infusión de dobutamina en el diagnóstico de la enfermedad coronaria. *Rev Esp Cardiol* 1995;48:606-14.
- De la Torre MM, San Román JA, Bermejo J, Garcimartín I, Paniagua J, Sanz O, et al. Valor pronóstico de la ecocardiografía con dobutamina después de un infarto agudo de miocardio no complicado. *Rev Esp Cardiol* 1999;52:237-44.
- San Román JA, Vilacosta I, Castillo JA, Rollán MJ, Hernández M, Peral V, et al. Selection of the optimal test for the diagnosis of coronary artery disease. *Heart* 1998;80:370-6.
- Wu A, Apple FS, Gibler B, Jessem RL, Warshaw M, Valdés R. National Academy of Clinical Biochemistry standards of laboratory practice: recommendations for the use of cardiac markers in coronary artery diseases. *Clin Chem* 1999;45:1104-21.
- Pantaghini M, Apple FS, Christenson RH, Dati F, Mair J, Wu A. Use of biochemical markers in acute coronary syndromes. IFCC Scientific Division, Committee on Standardization of Markers of Cardiac Damage. *Clin Chem Lab Med* 1999;37:687-93.
- Hudson MP, Christenson RH, Newb LK, Kaplan AL, Ohman EM. Cardiac markers: point of care testing. *Clin Chim Acta* 1999;284:223-37.
- Apple FS. Tissue specificity of cardiac troponin I, cardiac troponin T and creatine kinase-MB. *Clin Chim Acta* 1999;284:151-9.
- Filatov VL, Katrukha A, Bulargina T, Gusev N. Troponin: structure, properties, and mechanism of functioning. *Biochemistry (Moscow)* 1999;64:969-85.
- Schulz R, Guth BD, Pieper K, Heusch G. Recruitment of inotropic reserve in moderately ischemic myocardium at expense of metabolic recovery. A model of short-term hibernation. *Circ Res* 1992;70:1282-95.
- Schulz R, Rose J, Martín C, Broddle O, Heusch G. Consequences of regional inotropic stimulation of ischemic myocardium on regional myocardial blood flow and function in anesthetized swine. *Cir Res* 1989;64:1116-26.
- Beckman S, Boscksch W, Müller C, Schartl M. Does dobutamine stress echocardiography induce damage during viability diagnosis of patients with chronic dysfunction after myocardial infarction? *J Am Soc Echocardiogr* 1998;11:181-7.
- Meluzin J, Toman J, Groch L, Hornacek I, Sitar J, Fischerova B, et al. Can dobutamine echocardiography induce myocardial damage in patients with dysfunctional but viable myocardium supplied by a severely stenotic coronary artery? *Int J Cardiol* 1997; 61:175-81.
- Serrador A, San Román JA, Pastor G, Palomino R, Epureanu V, Vega JL, et al. New shorter dobutamine stress echocardiography protocol in the diagnosis of coronary artery disease [abstract]. *Eur Heart J* 2001;22(Suppl):116.
- Segar DS, Brown SE, Sawada SG, Ryan T, Feigenbaum H. Dobutamine stress echocardiography: correlation with coronary lesion severity as determined by quantitative angiography. *J Am Coll Cardiol* 1992;19:1197-202.
- Wu A, Ford L. Release of cardiac troponin in acute coronary syndromes: ischemia or necrosis? *Clin Chim Acta* 1999;284:161-74.
- Wu A, Feng Y. Biochemical differences between cTnT and TnI and their significance for diagnosis of acute coronary syndromes. *Eur Heart J* 1998;19(Suppl N):25-9.
- Suleiman VMS, Lucchetti V, Caputo M, Angelini GD. Short periods of regional ischaemia and reperfusion provoke release of troponin I from the human hearts. *Clin Chim Acta* 1999;284:25-30.
- Lindahl B, Venge P, Wallentin L. The FRISC experience with troponin T, use as decision tool and comparison with other prognostic markers. *Eur Heart J* 1998;19(Suppl N):51-8.
- The Joint European Society of Cardiology/American College of Cardiology Committee. Myocardial infarction redefined -A consensus document of the joint European Society of Cardiology/American College of Cardiology Committee for redefinition of myocardial infarction. *J Am Coll Cardiol* 2000;36:959-69.
- Tunsdall-Pedoe H. Redefinition of myocardial infarction by a consensus dissenter. *J Am Coll Cardiol* 2001;37:1472-3.
- Domínguez de Rozas JM, Obrador Mayol D, Tomás Abadal L. La nueva definición de infarto de miocardio. *Rev Esp Cardiol* 2001;54:1345.