

Table

Characteristics of the 5 Patients in Whom Atrial Fibrillation Was Detected: CHA₂DS₂-VASc Score and the Characteristics of the Episodes

Case	Age	Sex	Hypertension	DM	Prior CVA	CHF	Vascular disease	CHA ₂ DS ₂ -VASc	Episodes detected	Maximum duration, min	Time CVA-detection, months
1	80	M	Yes	Yes	Yes	No	No	6	3	4	5
2	69	M	Yes	No	Yes	No	No	4	1	10	10
3	67	M	Yes	No	Yes	No	Yes	5	1	6	1
4	79	F	Yes	No	Yes	No	No	6	13	32	3
5	73	F	Yes	No	Yes	No	No	5	2	14	10

CHF, chronic heart failure or injection fraction <40%; CVA, cerebrovascular accident; DM, diabetes mellitus; F, female; M, male.

The performance of the implantable loop recorder with this indication is under investigation in 2 randomized studies, CRYPTONITE and CRISTAL AF. Both are prospective, multicenter studies in which an implantable loop recorder is deployed in patients who have recently had a stroke and whose full etiologic study is negative. To date, only 1 study of similar characteristics has been published.³ In that study, the Reveal Plus® 9526 monitor (Medtronic Inc., Minneapolis, United States) was implanted in 24 patients with the condition. After a mean follow-up of 14.5 months, AF had not been detected in any patients. The main limitation of the study is the device itself, which requires 32 consecutive beats at a frequency of more than 165 bpm to detect AF, which might not identify some AF episodes.

While awaiting the results of the ongoing studies, our study indicates that the implantable loop device with an algorithm for the detection of AF is a tool that should be considered in the etiologic study of cryptogenic CVA. However, given the lack of a control group in our study and the high prevalence of AF in patients with this profile, no causal relationship can be established, although the technique does allow the initiation of appropriate antiplatelet treatment.

Jordi Mercé,^{a,*} Miriam Garcia,^a Xavier Ustrell,^b Anna Pellisé,^b Ramón de Castro,^a and Alfredo Bardají^a

^aServicio de Cardiología, Hospital Universitari de Tarragona Joan XXIII, Institut d'Investigació Sanitària Pere Virgili, Universitat Rovira i Virgili, Tarragona, Spain

^bServicio de Neurología, Hospital Universitari de Tarragona Joan XXIII, Institut d'Investigació Sanitària Pere Virgili, Universitat Rovira i Virgili, Tarragona, Spain

*Corresponding author:

E-mail address: jmerce@gmail.com (J. Mercé).

Available online 17 April 2013

REFERENCES

- Hindricks G, Pokushalov E, Urban L, Taborsky M, Kuck KH, Lebedev D, et al.; XPECT Trial Investigators. Performance of a new leadless implantable cardiac monitor in detecting and quantifying atrial fibrillation: Results of the XPECT trial. *Circ Arrhythm Electrophysiol.* 2010;3:141-7.
- Ustrell X, Pellisé A. Cardiac workup of ischemic stroke. *Curr Cardiol Rev.* 2010;6:175-83.
- Dion F, Saudeau D, Bonnaud I, Friocourt P, Bonneau A, Poret P, et al. Unexpected low prevalence of atrial fibrillation in cryptogenic ischemic stroke: a prospective study. *J Interv Card Electrophysiol.* 2010;28:101-7.

<http://dx.doi.org/10.1016/j.rec.2013.02.001>

Direct Transfemoral Aortic Valve Implantation in a Patient With a Mechanical Mitral Prosthesis

Implantación transfemoral directa de válvula aórtica en paciente con prótesis mitral previa

To the Editor,

Transfemoral aortic valve implantation (TAVI) in patients with a mechanical mitral prosthesis is a challenging procedure, due to the potential for prosthesis underexpansion, the risk of embolization, and interference due to the mitral prosthesis poppets.

Balloon predilation of the stenotic valve has been considered an essential step for valve preparation in TAVI procedures. However, recent publications have shown the safety and efficacy of direct implantation without previous valvuloplasty, which would simplify the procedure and could help ensure greater prosthetic stability during deployment and a lower incidence of cerebral embolic complications.^{1,2}

We describe the clinical case of an 81-year-old patient with severe aortic stenosis and an Edwards-Mira 27 mechanical mitral prosthesis who underwent direct TAVI with an Edwards-SAPIEN XT valve at our hospital, following admission to our hospital for dyspnea. On admission, transesophageal echocardiography showed a moderately calcified tricuspid aortic valve, with

symmetric opening and valvular area of 0.7 cm². A computed tomography scan showed an iliofemoral axis of good diameter, with a distance >7 mm between the aortic annulus and the mitral valve (Figs. 1A and B). Coronary angiography revealed severe disease in the anterior descending artery, treated with two overlapping stents; aortography ruled out significant aortic regurgitation (Fig. 2A, video 1).

A decision was made to implant a 23-mm Edwards-SAPIEN XT valve with no previous valvuloplasty. Good valve expansion was confirmed by fluoroscopy guidance (Fig. 2B, video 2) and transesophageal echocardiography, and no perivalvular regurgitation (Fig. 2C, video 3) or prosthetic mitral valve interference (Fig. 2D) was observed after implantation. A predischarge computed tomography scan confirmed that both prostheses were in the correct position (Figs. 1C and D).

The presence of a mitral prosthesis was originally considered a formal contraindication for transcatheter aortic valve implantation, and these patients were excluded from the PARTNER (Placement of AORTic TraNscatheter valves) study. It was considered that the mitral annulus rigidity and the tighter space in the mitral-aortic plane could prevent adequate valve deployment, favor embolization, and increase the risk of underexpansion and malfunction due to mitral valve poppets interference. Rodés-Cabau et al.³ were the first to report transapical implant of an Edwards-SAPIEN valve in the presence of a mechanical mitral

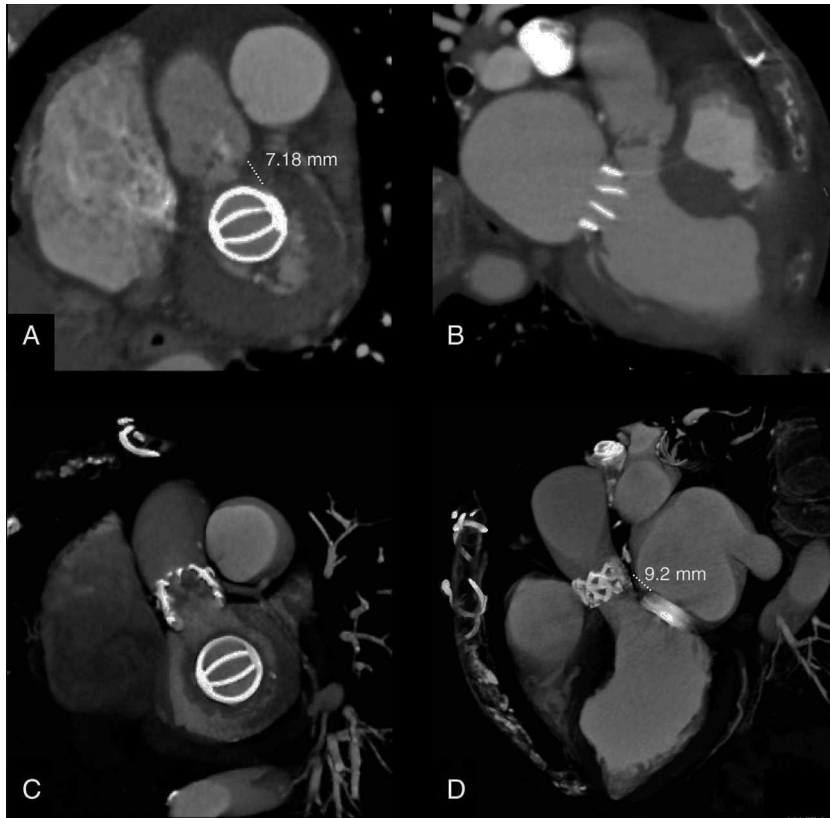


Figure 1. Computed tomography images before (A and B) and after (C and D) implantation.

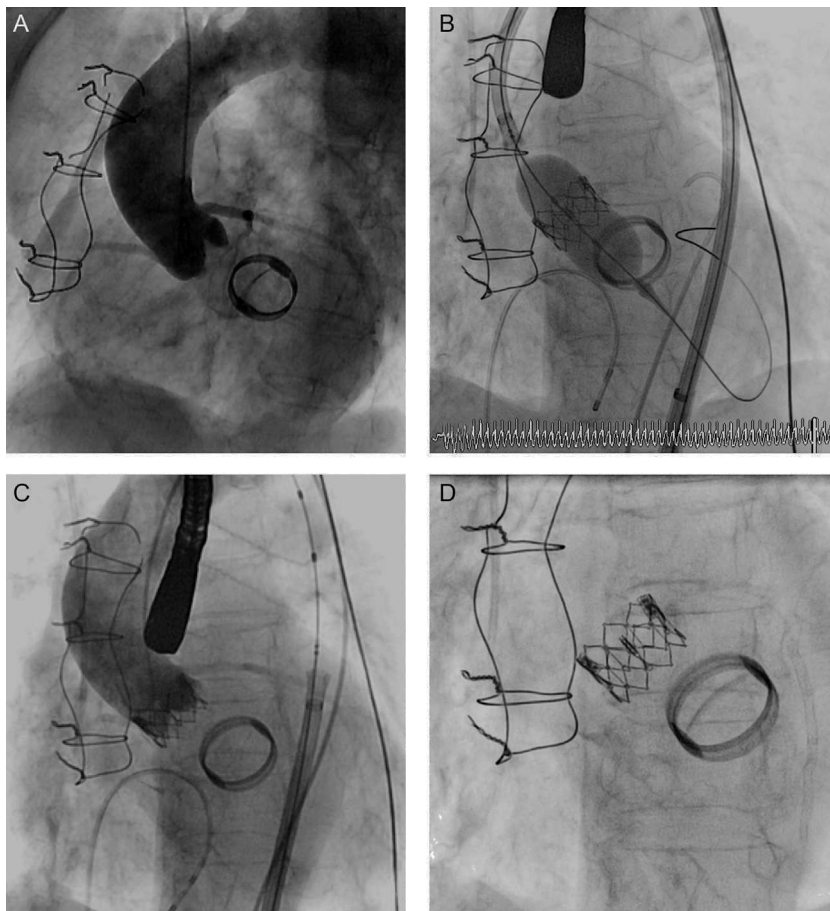


Figure 2. A: Preimplantation aortography. B: Valve deployment. C: Final aortography. D: Anatomic relationship between the prostheses.

prosthesis. Several cases have since been published; most were transapical, as it was considered that this approach provided greater stability in valve deployment.⁴ Early cases of TAVI in patients with a mitral prosthesis were performed using a CoreValve prosthesis, and it was confirmed that there was no deformation of the nitinol tubing of the valve or interference due to the poppets of the mitral prosthesis.⁵ García et al.⁶ published the first 3 cases of TAVI with an Edwards-SAPIEN XT valve, in 3 women with ATS 29 and St. Jude mechanical mitral prostheses. The authors recommended a thorough study of patients before the procedure, with particular emphasis on the characteristics and profile of the mitral valve prosthesis, as they considered that there should be sufficient distance between the lower edge of the annulus and the upper edge of the mitral valve prosthesis. This distance was not specified, although it was considered advisable that the distance be at least 3 mm in transapical implants and 7 mm in transfemoral implants.⁶

Furthermore, it appears that direct TAVI without prior valvuloplasty offers several advantages, such as a lower risk of stroke, greater stability in valve deployment, and lower perivalvular aortic regurgitation; however, no randomized studies have compared the 2 techniques.^{1,2} To our knowledge, this is the first published case of direct TAVI in the presence of mechanical mitral prosthesis.

To ensure success in this type of procedure, patients should be carefully selected and direct implantation considered if the valve opens correctly and symmetrically, with no significant calcification of the leaflets or excessive commissural fusion. In addition, rapid valve placement at the annulus is recommended to shorten flow obstruction time and to obtain greater hemodynamic stability; inflation should be started slowly such that any undesirable movement of the prosthesis can be corrected, if necessary.

This case shows that a TAVI implant without predilation in the presence of a mitral mechanical prosthesis is feasible and safe and can offer advantages over the conventional method. Future studies are needed to compare the 2 implant techniques with the various models of percutaneous valve prostheses.

Dronedaron: An Option in the Treatment of Ventricular Arrhythmias

Dronedaron: una opción en el tratamiento de las arritmias ventriculares

To the Editor,

The management of ventricular arrhythmias is complex and often requires the implantation of an implantable cardioverter-defibrillator (ICD). However, antiarrhythmic agents (AAA) continue to be relevant as a primary indication and as a way to reduce device-based therapies in patients with ICDs. However, patients often present contraindications that restrict AAA therapy to just a few options, such as amiodarone. Dronedaron is an AAA that has been proven effective in the control of atrial arrhythmias and may help patients with recurrent ventricular arrhythmias when other drugs cannot; however, information on its effectiveness in this clinical setting is scarce. We describe the use of dronedaron in 3 patients with ventricular arrhythmias who were unresponsive or intolerant to other AAAs.

The first patient, a 53-year-old man with hypertension but without structural heart disease, had experienced frequent monomorphic premature ventricular beats since 2007. Treatment with atenolol and sotalol had failed. In February 2010, he was admitted after presenting with syncope and documented a

SUPPLEMENTARY MATERIAL



Supplementary material associated with this article can be found in the online version available at <http://dx.doi.org/10.1016/j.rec.2013.02.009>.

Leire Unzué,* Eulogio García, Leticia Fernández-Friera, Ana Alegría-Barrero, Juan Medina-Peralta, and F. José Rodríguez-Rodrigo

Unidad de Hemodinámica y Cardiología Intervencionista, Hospital Universitario Montepríncipe, Madrid, Spain

*Corresponding author:

E-mail address: leireunzue@yahoo.es (L. Unzué).

Available online 25 May 2013

REFERENCES

- García E, Hernández-Antolín R, Martín P, Rodríguez JC, Almería C, Cuadrado AM. Implantación de prótesis aórtica Edwards-SAPIEN XT transfemoral sin valvuloplastia previa. *Rev Esp Cardiol.* 2013;66:150-1.
- Grube E, Naber C, Abizaid A, Sousa E, Mendiz O, Lemos P, et al. Feasibility of transcatheter aortic valve implantation without balloon pre-dilation: a pilot study. *JACC Cardiovasc Interv.* 2011;4:751-7.
- Rodes-Cabau J, Dumont E, Miro S. Apical aortic valve implantation in a patient with a mechanical valve prosthesis in mitral position. *Cir Cardiovasc Intervent.* 2008;1:233.
- Soon JL, Ye J, Lichtenstein SV, Wood D, Webb JG, Cheung A. Transapical transcatheter aortic valve implantation in the presence of a mitral prosthesis. *J Am Coll Cardiol.* 2011;58:715-21.
- Bruschi G, De Marco F, Oreglia J, Colombo P, Fratto P, Lullo F, et al. Percutaneous implantation of CoreValve aortic prostheses in patients with a mechanical mitral valve. *Ann Thorac Surg.* 2009;88:e50-2.
- García E, Albarrán A, Heredia-Mantrana J, Guerrero-Pinedo F, Rodríguez J, Hernández-Antolín R, et al. Implantación transfemoral de prótesis valvular aórtica en pacientes portadores de prótesis mitral mecánica. *Rev Esp Cardiol.* 2011;64:1052-5.

<http://dx.doi.org/10.1016/j.rec.2013.02.009>

nonsustained monomorphic ventricular tachycardia. An electrophysiology study was conducted and a sustained monomorphic ventricular tachycardia (SMVT) similar to the clinical arrhythmia was induced, as well as 2 other morphologies. Endocardial and epicardial mapping located the arrhythmogenic substrate in the superolateral aspect of the mitral annulus. The application of RF energy was not effective and thus intramyocardial reentry was suspected. Cardiac magnetic resonance imaging showed a scar in the anterolateral aspect of the left ventricle. An ICD was implanted and treatment with flecainide was initiated. Subsequent follow-ups showed that he had experienced numerous episodes of SMVT and received ICD shocks (Figs. 1 and 2). We decided to replace flecainide for dronedaron 400 mg every 12 h and to avoid the use of amiodarone due to its adverse effects. From that time on, and up to his final check-up 14 months later, there was a reduction in arrhythmia burden and the patient did not undergo ICD shocks or experience SMVT episodes, with the exception of 2 episodes that were suppressed by the initial antitachycardia pacing therapy.

The second patient, a 64-year-old man with hypertension but without apparent structural heart disease, had been followed up in another hospital since 2006 for ventricular tachycardia. Three ablation procedures had failed and an ICD was implanted in 2007. Initially, he was treated with metoprolol and subsequently with sotalol and multiple ICD shocks. In 2009, treatment with amiodarone and atenolol was initiated, which reduced the number of episodes. On 2 occasions in December 2011, he was admitted for