

Our data suggest that percutaneous closure of baffles is a safe procedure and the medium-term follow-up demonstrates no recurrences of the leaks and good clinical status.

Andreu Porta-Sánchez,<sup>a,\*</sup> Gerard Martí-Aguasca,<sup>b</sup>  
 Maria Antònia Pijuan-Doménech,<sup>c</sup> Laura Dos-Subirà,<sup>c</sup>  
 Maria-Teresa Subirana-Doménech,<sup>d</sup> and Jaume Casaldàliga-Ferrer<sup>c</sup>

<sup>a</sup>*Servei de Cardiologia, Hospital Universitari de la Vall d'Hebron, Vall d'Hebron Institute of Research (VHIR), Barcelona, Spain*

<sup>b</sup>*Servei de Cardiologia, Hospital Universitari de la Vall d'Hebron, Barcelona, Spain*

<sup>c</sup>*Unitat de Cardiopaties Congènites de l'Adolescent i de l'Adult (UCCAA), Hospital Universitari de la Vall d'Hebron, Barcelona, Spain*

<sup>d</sup>*Unitat de Cardiopaties Congènites de l'Adolescent i de l'Adult (UCCAA), Hospital Universitari de la Santa Creu i Sant Pau, Barcelona, Spain*

\* Corresponding author:

E-mail address: [anporta@vhebron.net](mailto:anporta@vhebron.net) (A. Porta-Sánchez).

Available online 23 June 2014

## REFERENCES

1. Gelatt M, Hamilton RM, McCrindle BW, Connelly M, Davis A, Harris L, et al. Arrhythmia and mortality after the mustard procedure: A 30-year single-center experience. *J Am Coll Cardiol.* 1997;29:194-201.
2. Dos L, Teruel L, Ferreira IJ, Rodriguez-Larrea J, Miro L, Girona J, et al. Late outcome of senning and mustard procedures for correction of transposition of the great arteries. *Heart.* 2005;91:652-6.
3. Tobler D, Williams WG, Jegatheeswaran A, Van Arsdell GS, McCrindle BW, Greutmann M, et al. Cardiac outcomes in young adult survivors of the arterial switch operation for transposition of the great arteries. *J Am Coll Cardiol.* 2010;56:58-64.
4. Horer J, Karl E, Theodoratou G, Schreiber C, Cleuziou J, Prodan Z, et al. Incidence and results of reoperations following the Senning operation: 27 years of follow-up in 314 patients at a single center. *Eur J Cardiothorac Surg.* 2008;33:1061-7. discussion 1067-8.
5. Hill KD, Fleming G, Curt Fudge J, Albers EL, Doyle TP, Rhodes JF. Percutaneous interventions in high-risk patients following mustard repair of transposition of the great arteries. *Catheter Cardiovasc Interv.* 2012;80:905-14.
6. Daehnert I, Hennig B, Wiener M, Rotzsch C. Interventions in leaks and obstructions of the interatrial baffle late after mustard and senning correction for transposition of the great arteries. *Catheter Cardiovasc Interv.* 2005;66:400-7.

<http://dx.doi.org/10.1016/j.rec.2014.03.015>

## Delayed Positive Response to a Flecainide Test in a Patient With Suspected Brugada Syndrome: a Worrisome Finding



### Respuesta positiva diferida al test de flecainida en paciente con sospecha de síndrome de Brugada: un hallazgo preocupante

#### To the Editor,

Drug challenge tests used to elicit a Brugada electrocardiographic pattern (B-ECG) are fundamental in the diagnosis of this syndrome. Sodium channel blockers used in the treatment of cardiac arrhythmias, mainly ajmaline and flecainide, are the agents most widely employed because of their demonstrated efficacy and safety in unmasking the B-ECG. The results of the test are considered positive if, during infusion of the drug, a nondiagnostic B-ECG (type 2 or 3) becomes a diagnostic B-ECG (type 1 or coved type), which is characterized by ST segment elevation  $\geq 2$  mm followed by a negative T wave in more than 1 precordial lead ( $V_1$ - $V_3$ ). These tests are usually performed in an outpatient setting and, once the electrocardiogram has become normalized, the patient is discharged after a short monitoring period. There is no information in the literature concerning the incidence and implications of late positive responses following an initially negative flecainide test (FT).

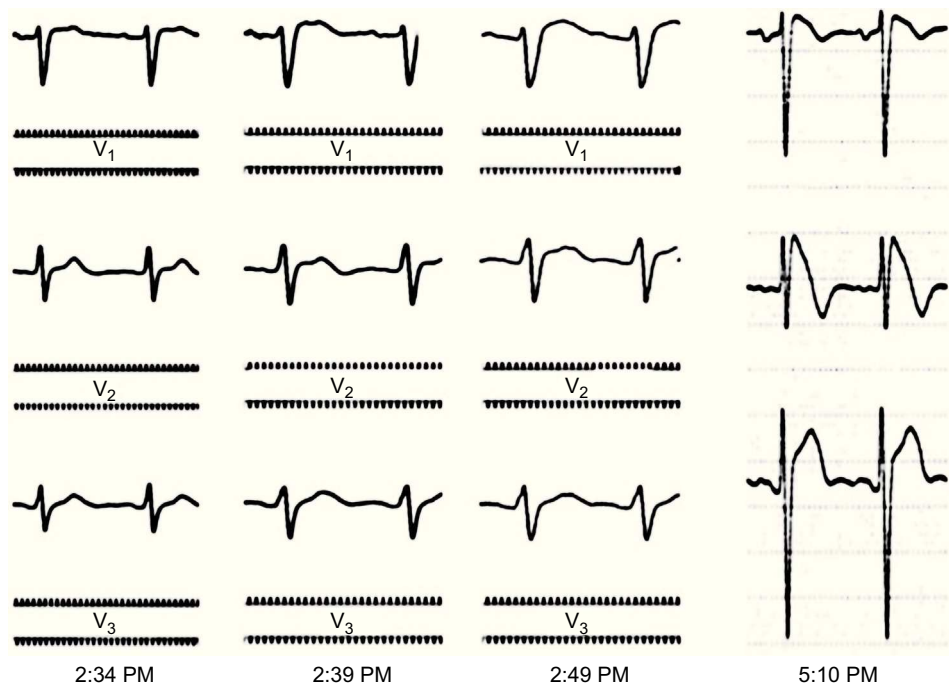
We report the case of a 32-year-old man who was asymptomatic and had no family history of sudden cardiac death. He was referred to our hospital to undergo a FT when he was found to have a type 3 B-ECG in a routine electrocardiogram. The results of a physical examination and a battery of analyses were normal. The existence of structural heart disease was ruled out by echocardiography. A baseline electrocardiogram performed prior to the FT revealed no abnormalities. Following flecainide infusion (2 mg/kg body weight for 10 minutes), the patient had a significantly prolonged QRS interval, but met none of the diagnostic criteria for B-ECG (with precordial leads  $V_1$  and  $V_2$  placed both in the fourth and in

the third intercostal space). Although the widening of the QRS complex did not meet the criteria for interrupting the test (QRS  $> 130\%$  of baseline value), he was admitted to the hospital for electrocardiographic monitoring until the intraventricular conduction disturbance had been corrected. Two hours after completing the administration of flecainide, we detected coved ST-segment elevation in the right precordial leads, a finding that met the criteria for type 1 B-ECG (Figure). Twenty-four hours later, the electrocardiogram had returned to normal and the patient was discharged home.

This report describes a case of a late positive response to FT after an initial negative result. It was discovered incidentally because the patient underwent a longer than usual period of electrocardiographic monitoring.

Among the antiarrhythmic sodium channel blockers currently available, ajmaline has been found to exhibit the greatest efficacy in unmasking B-ECG. Hong et al<sup>1</sup> evaluated ajmaline in a cohort of 147 carriers of mutations in the *SCN5A* gene. They reported a diagnostic sensitivity and specificity of 80% and 94%, respectively, as well as a positive predictive value of 93% and negative predictive value of 83% for the syndrome. Meregalli et al<sup>2</sup> analyzed the effect of flecainide in 110 carriers of the same gene; they obtained a sensitivity of 77%, specificity of 80%, positive predictive value of 96%, and negative predictive value of 36%. The 2 drugs were compared in a study by Wolpert et al<sup>3</sup> involving 22 probands with a genetic diagnosis of Brugada syndrome; ajmaline had a higher detection capacity (22 of 22) than flecainide (15 of 22) and a more marked ST-segment elevation. The reproducibility of FT has also been controversial. Gasparini et al<sup>4</sup> found a reproducibility of 100%. However, there are reports of cases in which the test was negative, although the initial response had been positive.<sup>5</sup>

Despite the superiority of ajmaline, the fact that in many countries it is not available has made flecainide the drug of choice in most electrophysiology laboratories. The differences between the 2 drugs have been related to flecainide's greater inhibition of the transient outward potassium current<sup>3</sup> ( $I_{to}$ ). This reduces the ionic imbalance between the positive inward and outward



**Figure.** Right precordial leads ( $V_1$ - $V_3$ ) at 25 mm/s and 10 mV/mm. The tracings in the first 3 panels were obtained in the electrophysiology laboratory with an EP-WorkMate polygraph (St. Jude Medical). The fourth panel is a standard digital electrocardiogram obtained in the cardiology department.

currents at the end of phase 1 of the action potential that enables the unmasking of the B-ECG.

The case of a delayed positive response to flecainide reported here might indicate that results considered to be negative at the time of the challenge test may be false negatives, since the electrocardiographic monitoring time is usually 30 minutes or less.

Studies involving a larger number of patients should be carried out to examine whether the systematic prolongation of the monitoring period following a FT could contribute to reducing the number of false negatives.

Marta de-Riva-Silva,\* José M. Montero-Cabezas, Adolfo Fontenla-Cerezuola, Rafael Salguero-Bodes, María López-Gil, and Fernando Arribas-Ynsaurriaga

Unidad de Arritmias y Electrofisiología, Servicio de Cardiología, Hospital 12 de Octubre, Madrid, Spain

\* Corresponding author:

E-mail address: [martaderiva@gmail.com](mailto:martaderiva@gmail.com) (M. de-Riva-Silva).

Available online 14 June 2014

## REFERENCES

- Hong K, Brugada J, Oliva A, Berruezo-Sánchez A, Potenza D, Pollevick GD, et al. Value of electrocardiographic parameters and ajmaline test in the diagnosis of Brugada syndrome caused by SCN5A mutations. *Circulation*. 2004;110:3023–7.
- Meregalli G, Ruijter J, Hofman N, Bezzina C, Wilde A, Tan H. Diagnostic value of flecainide testing in unmasking SCN5A-related Brugada syndrome. *J Cardiovasc Electrophysiol*. 2006;17:857–64.
- Wolpert C, Echternach C, Veltmann C, Antzelevitch C, Thomas GP, Spehl S, et al. Intravenous drug challenge using flecainide and ajmaline in patients with Brugada syndrome. *Heart Rhythm*. 2005;2:254–60.
- Gasparini M, Priori SG, Mantica M, Napolitano C, Galimberti P, Cerlotti C, et al. Flecainide test in Brugada syndrome: a reproducible but risky tool. *Pacing Clin Electrophysiol*. 2003;26:338–41.
- Abello M, Merino JL, Peinado R, Gnoatto M. Negative flecainide test in Brugada syndrome patients with previous positive response. *Europace*. 2006;8:899–900.

<http://dx.doi.org/10.1016/j.rec.2014.03.007>

## Infranodal Atrioventricular Block as a Possible Cause of Exercise-induced Cardiac Arrest



### Bloqueo auriculoventricular infranodular como posible causa de parada cardíaca inducida por ejercicio

To the Editor,

Cardiac arrest that occurs during long-distance running races is most commonly attributed to hypertrophic cardiomyopathy or atherosclerotic coronary disease. Conduction system disease is an extremely rare cause of sudden death in athletes and the final

cause remains unknown in a small proportion of cases.<sup>1</sup> We present a case of malignant bradyarrhythmia in a long distance runner.

A 46-year-old healthy man, with no previous cardiovascular history, had a cardiac arrest immediately after completing a half marathon. At the finish line, he fainted and was attended by the emergency medical services, which initiated advanced life support in the presence of severe bradycardia (23 bpm) and hypotension. A first electrocardiogram showed complete atrioventricular block (AVB) with slow wide QRS complex escape (Figure 1A). Intravenous atropine only increased sinus rate without improving the degree of AVB (Figure 1B) and therefore a transcatheter