

## Coronary Endarterectomy and Bypass Grafting without Cardiopulmonary Bypass

Guillermo Careaga Reyna, David Salazar Garrido, Sergio Téllez Luna and Rubén Argüero Sánchez

División de Cirugía Cardiorábrica, Hospital de Cardiología, Centro Médico Nacional Siglo XXI, IMSS, Mexico D.F., Mexico

We prospectively analyzed patients who underwent simultaneous off-pump coronary artery bypass grafting and endarterectomy between March 1, 1997 and February 28, 2002. The incidence of perioperative myocardial infarction, need for inotropic support, morbidity, long-time functional class, and mortality were evaluated.

Nine endarterectomies were performed in eight patients, more frequently in the right coronary artery. Dopamine was used in four patients. One perioperative myocardial infarction (12.5%) occurred. No deaths occurred and all patients are now functional class I. Tests for ischemia have been negative in all patients.

Coronary endarterectomy is an alternative procedure that has little morbidity and enables complete myocardial revascularization without cardiopulmonary bypass.

**Key words:** *Endarterectomy. Myocardial revascularization. Cardiopulmonary bypass. Perioperative myocardial infarction.*

Full English text available at: [www.revespcardiol.org](http://www.revespcardiol.org)

### INTRODUCTION

Coronary endarterectomy was one of the first surgical procedures used for ischemic heart disease,<sup>1,2</sup> although technical limitations led to discouraging results.<sup>2</sup> When combined with aortocoronary bypass and extracorporeal circulation, long-term bypass patency was 64% versus over 90% for bypasses in vessels without endarterectomy.<sup>3</sup>

Correspondence: Dr. G. Careaga Reyna  
División de Cirugía. Hospital de Cardiología,  
Centro Médico Nacional Siglo XXI,  
Avda. Cuauhtémoc, 330, Col Doctores, 06725 Mexico DF, Mexico  
E-mail: [gcareaga3@aol.com](mailto:gcareaga3@aol.com)

Received 7 May 2002.

Accepted for publication 10 December 2002.

### Endarterectomía coronaria y revascularización miocárdica sin derivación cardiopulmonar

Presentamos en forma prospectiva la experiencia con la endarterectomía coronaria combinada con la revascularización miocárdica sin derivación cardiopulmonar entre el 1 de marzo de 1997 y el 28 de febrero de 2002. Se evaluaron la necesidad de administrar fármacos inotrópicos, la presencia de infarto perioperatorio, la morbilidad, la clase funcional a largo plazo y la mortalidad.

En 8 pacientes se efectuaron 9 endarterectomías. Predominó el procedimiento en la arteria coronaria derecha. Un total de 4 pacientes requirió dopamina a dosis bajas. Hubo un infarto perioperatorio (12,5%). No hubo mortalidad y en el momento actual todos los pacientes se encuentran en clase funcional I, con pruebas de esfuerzo negativas.

Concluimos que la endarterectomía coronaria es una opción complementaria que permite una revascularización miocárdica más completa, aun sin utilizar la derivación cardiopulmonar.

**Palabras clave:** *Endarterectomía. Revascularización miocárdica. Circulación extracorpórea. Infarto perioperatorio.*

Coronary artery bypass grafting without cardiopulmonary bypass was first described by Kolessov<sup>4</sup> and is now a common procedure at most cardiac hospitals, as it has several advantages.<sup>5</sup>

With the advent of percutaneous transluminal coronary angioplasty, the patients now referred for surgery present diffuse, complex lesions<sup>6</sup> which, along with the condition of the vessel wall at the time of the arteriotomy,<sup>7</sup> influence the surgical outcome. Therefore, coronary endarterectomy is an option that can be used in combination with anastomosis of aortocoronary bypasses.<sup>8</sup> We present our experience with simultaneous off-pump coronary artery bypass grafting and endarterectomy.

### PATIENTS AND METHODS

Patients who underwent simultaneous off-pump co-

TABLE 1. Patient characteristics, aortocoronary bypass site, and endarterectomized vessels

Case	Sex	Age, years	History	Vessels with aortocoronary bypass	Vessels with endarterectomy	Current status
1	F	57	Diabetes/HT	LAD	LAD	Alive/Class I Cath: patent
2	M	62	Smoker	LAD, PDA	LAD, PDA	Alive/Class Y
3	F	78	Diabetes/dyslipidemia	LAD, PDA	PDA	Alive/Class Y Cath: occluded PDA <sup>a</sup>
4	M	41	Failed PTCA in LAD and PDA	LAD, PDA	PDA	Alive/Class Y
5	M	54	Diabetes	LAD, PDA	PDA	Alive/Class II <sup>b</sup>
6	M	45	HT/smoker	LAD, PDA, D1	PDA	Alive/Class Y
7	M	55	HT/smoker	LAD, PDA, D2	D2	Alive/Class Y
8	M	57	–	LAD, PDA, D1, D2	PDA	Alive/Class I

<sup>a</sup>The patient presented a perioperative inferior infarction.

<sup>b</sup>Patient with ischemic cardiomyopathy.

PTCA indicates percutaneous transluminal coronary angioplasty; HT, hypertension; LAD, left anterior descending artery; PDA, posterior descending artery; D1, first diagonal; D2: second diagonal; Cath: catheterization.

ronary artery bypass grafting and endarterectomy between 1 March 1997 and 28 February 2002 were prospectively included in the study.

Off-pump coronary artery bypass grafting was indicated in patients with more than 70% obstruction and adequate distal anatomy, in whom manipulation of the myocardium did not cause hemodynamic alterations or serious arrhythmias refractory to treatment.

After standard preoperative preparation and immobilization of the myocardial segment selected, arteriotomy was performed. When plaque was found, we evaluated its fragility, thickness, patency, apparent extension, and adherence to the endothelium of the coronary vessel.

If the vessel was not appropriate for anastomosis, we performed endarterectomy by everting and dissecting the plaque from the arterial wall, applying gentle traction and countertraction from the ends of the arteriotomy, then withdrawing the entire plaque from the proximal end (Figure 1). We checked that the entire plaque had been removed by verifying that the tapered end of the plaque had been withdrawn, and confirming proximal and distal blood flow. The same procedure was used in all cases and was followed by standard revascularization.

We did not perform endarterectomy in vessels with a diameter under 2 mm, coronary dilation, or plaque in vessels that fed nonviable myocardium.

We investigated arrhythmia, use of inotropic agents, CK-MB levels, other postoperative complications or mortality, plus stress tests and New York Heart Association (NYHA) functional class in the follow-up, considering perioperative infarction to have occurred when the following appeared: Q-waves not visualized in the preoperative electrocardiogram, electrocardiographic changes suggestive of lesion persisting for

more than seven days, echocardiographic abnormalities in segmental contractility, as well as CK levels above 400 U/L or CK-MB of 40 U/L.<sup>9,10</sup>

## RESULTS

During the study period, nine endarterectomies were performed in eight patients (6.2% of off-pump bypass grafts). Table 1 contains a summary of patient characteristics.

Mean patient age was 56 years (range 41-78 years). The mean age of patients who underwent bypass grafting at our hospital was 60.9 years. A mean of 2.3 bypasses were performed per patient (Table 1). The internal mammary artery was routinely used for the left anterior descending artery.

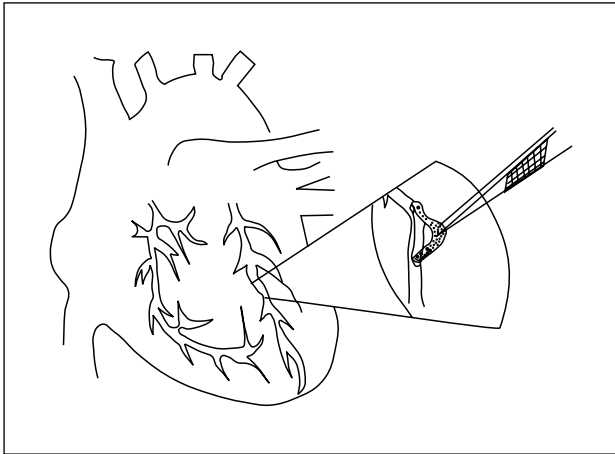
Three of the eight patients required 2 µg/kg/min of dopamine during the surgery. One patient with ischemic cardiomyopathy and ejection fraction of 18% required 5 µg/kg/min of dopamine.

We did not use intraoperative bradycardia.

One patient presented transient ventricular premature beats with no hemodynamic repercussions 12-24 h after surgery. He was treated with lidocaine.

One patient experienced a perioperative inferior infarction with electrocardiographic abnormalities and elevated CK values above 800 U/L and CK-MB at 50 U/L. Two years later we performed catheterization, which showed occlusion of the saphenous vein bypass graft in the right coronary.

Prior to the endarterectomy, one patient had undergone a single internal mammary bypass graft to the left anterior descending artery; catheterization at 36 months verified the patency of the anastomosis (Figure 2) and the absence of new lesions.



**Fig. 1.** Diagram of the procedure. Atheromatous plaque is visualized through the arteriotomy of the left anterior descending artery and excised.

No deaths occurred.

All patients are now asymptomatic and have resumed their activities. In addition, stress tests have been negative for ischemia (Table 1).

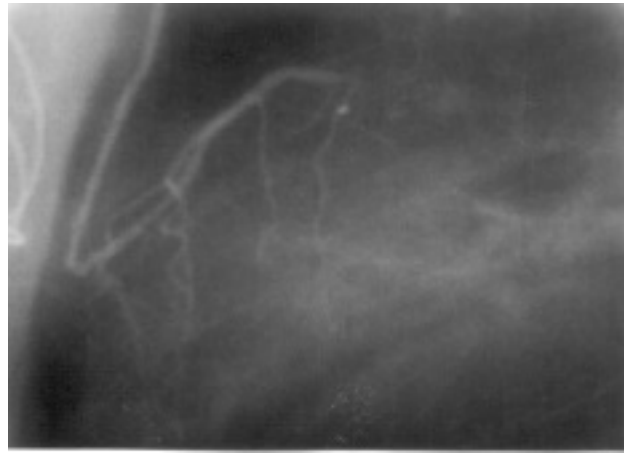
The patient with ischemic cardiomyopathy required hospitalization on two occasions during the postoperative period for dose-adjustment of the heart failure medication.

Follow-up lasted from 9 to 64 months.

## DISCUSSION

Coronary endarterectomy with aortocoronary bypass grafting is controversial, with rates for mortality of 0%-10%, perioperative infarction of 5%-30%, and anastomosis patency of 38%-100%.<sup>9,11</sup> This variability in outcome, clinical improvement and disappearance of symptoms in 74-95% of endarterectomy patients, makes it impossible to clearly identify the limit between precise indication and excess practice of the procedure. Therefore, surgery should be personalized according to the perioperative findings<sup>7</sup> and be performed carefully,<sup>8</sup> since increased troponin-T and CK-MB levels have been reported with coronary endarterectomy.<sup>12</sup>

On-pump or off-pump endarterectomy helps achieve effective revascularization of vessels that otherwise appear to be inoperable. However, we should consider the various techniques, apparent increase in myocardial infarction rates, vessel rupture due to inadequate traction, long-term patency rates below those of vessels without endarterectomy, and mortality rates, in order to offer optimal revascularization in patients who cannot receive percutaneous angioplasty and to provide a surgical option for patients who would otherwise be inoperable.<sup>13</sup> Since only patients whose symptoms recur are normally catheterized and more



**Fig. 2.** Patency of the anastomosis between the internal mammary artery and the left anterior descending artery in which endarterectomy was performed.

than 80% of patients exhibit no long-term symptoms,<sup>14,15</sup> with patency rates above 85%,<sup>8</sup> it should be remembered that bias does exist.

When endarterectomy is needed during off-pump coronary artery bypass grafting, the procedure can be converted to on-pump surgery and then be completed. However, it is still necessary to evaluate whether or not this conversion would modify the technique. If no change is needed, the surgery should be continued without adding the potential morbidity associated with an on-pump procedure, even in complex cases.<sup>16</sup>

## CONCLUSION

Simultaneous off-pump coronary artery bypass grafting and endarterectomy is a viable alternative when there is no other option for adequate revascularization, and can achieve effective medium- and long-term clinical improvement in these patients, when performed as recommended herein.

## REFERENCES

1. Bailey CP, May A, Lewman WM. Survival with coronary endarterectomy in man. *JAMA* 1957;164:641-56.
2. Effler DB, Groves KL, Sones FM, Shirey EK. Endarterectomy in the treatment of coronary artery disease. *J Thorac Cardiovasc Surg* 1964;47:98-108.
3. Yeh TJ, Heidary D, Shelton L. Y-grafts and sequential grafts in coronary bypass surgery: a critical evaluation of patency rates. *Ann Thorac Surg* 1979;27:409-12.
4. Mueller RL, Rosengart TK, Ison OW. The history of surgery for ischemic heart disease. *Ann Thorac Surg* 1997;63:869-78.
5. Careaga G, Santaella M, Esparza J, Argüero R. Revascularización miocárdica sin circulación extracorpórea. *Cir Ciruj* 1998;66: 85-8.
6. Eagle KA, Guyton RA, Davidoff R, Ewy GA, Fonger J, Gardner TJ, et al. ACC/AHA guidelines for coronary artery bypass graft surgery: executive summary and recommendations. A report of

- the American College of Cardiology/American Heart Association task force on practice guidelines (committee to revise the 1991 guidelines for coronary artery bypass graft surgery). *Circulation* 1999;100:1464-80.
7. Eschenbruch EM, Schmuziger M, Tollenaere P, Gornandt L, Hahn C. Endarterectomy of the left coronary artery (LCA) as a supplementary surgical means of myocardial revascularization with aortocoronary bypass procedure. *Thorac Cardiovasc Surg* 1980;28:280-4.
  8. Wallsh E, Franzone AJ, Clauss RH, Armellini C, Steichen F, Stertz SH. Manual coronary endarterectomy with saphenous bypass. Experience with 263 patients. *Ann Thorac Surg* 1981;32:451-7.
  9. Jain U, Lafflame JA, Aggarwal A, Ramsay JG, Comunale ME, Ghoshal S, et al. Electrocardiographic and hemodynamic changes and their association with myocardial infarction during coronary artery bypass surgery. *Anesthesiology* 1997;86:76-91.
  10. De Castro J, Vázquez-Rivaldos S, Velejos-Amo C, Herranz J, Almeria-Varela C, I Lloro-Mora M. Troponina I cardíaca en el infarto de miocardio perioperatorio tras cirugía de revascularización coronaria. *Rev Esp Cardiol* 2002;55:245-50.
  11. Keon WJ, Masters RG, Roshal A, Hendry P, Farrel EM. Coronary endarterectomy: an adjunct to coronary artery bypass grafting. *Surg Clin North Am* 1988;68:669-78.
  12. Taggart DP. Biochemical assessment of myocardial injury after cardiac surgery: effects of a platelet activating factor antagonist, bilateral internal thoracic artery grafts and coronary endarterectomy. *J Thorac Cardiovasc Surg* 2000;120:651-9.
  13. Fundaro P, Santoli C. Coronary endarterectomy: state of the art. *G Ital Cardiol* 1986;16:835-44.
  14. Qureshi SA, Halim MA, Pillai R, Smith P, Yacoub MH. Endarterectomy of the left coronary system. Analysis of a 10-year experience. *J Thorac Cardiovasc Surg* 1985;89:852-9.
  15. De Gaspers C. Myocardial revascularization combined with endarterectomy. *G Ital Cardiol* 1979;9:557-61.
  16. Tania M, Redial N, Demirkilic U, Tatar U. Double coronary endarterectomy on the beating heart in two patients with porcelain aorta. *Ann Thorac Surg* 2001;72:620-1.