

Coronary Angiography: Beyond Coronary Anatomy

Armando Pérez de Prado,^a Felipe Fernández-Vázquez,^a J. Carlos Cuellas-Ramón,^a and C. Michael Gibson^b

^aSección de Cardiología Intervencionista, Servicio de Cardiología, Hospital de León, León, Spain.

^bTIMI (Thrombolysis In Myocardial Infarction) Study Group, Harvard Medical School, Boston, Massachusetts, USA.

Although technical advances enable normal epicardial coronary artery blood flow to be restored in most patients suffering myocardial infarction, restoration of blood flow is not always followed by improved myocardial perfusion. Recently, therefore, interest in the assessment of myocardial perfusion has grown, and a number of different assessment methods are available. The aim of this article was to provide an evaluation of the additional information that can be obtained from the widely used technique of conventional coronary angiography. We present a review of the data on epicardial coronary artery blood flow (both semiquantitative and quantitative) and on microvascular blood flow that can be obtained using coronary angiography and discuss their prognostic significance.

Key words: *Coronary angiography. Coronary blood flow. Myocardial perfusion.*

Coronariografía: más allá de la anatomía coronaria

Aunque los avances tecnológicos permiten restaurar el flujo coronario normal en la arteria epicárdica en la mayoría de los pacientes con infarto de miocardio, no en todos los casos se traduce en la mejoría de la perfusión miocárdica; por ello, el interés clínico en la evaluación de ésta ha crecido recientemente. Son varios los métodos que permiten valorar este parámetro, pero el objetivo de esta revisión es analizar la información adicional que ofrece una técnica ampliamente usada, la simple coronariografía. Se revisan los datos de flujo epicárdico (tanto de forma semicuantitativa como cuantitativa) y microvascular que se pueden obtener con la coronariografía y su implicación pronóstica.

Palabras clave: *Angiografía coronaria. Flujo coronario. Perfusión miocárdica.*

INTRODUCTION

The main aim in treating acute myocardial infarction (AMI) is to restore patency in the epicardial coronary artery. The theory of the “open artery” is based on two fundamental factors: time (as soon as possible) and size (as much flow as possible). Whatever the reperfusion method used, as demonstrated in many studies,¹⁻⁶ the final aim is that the angiographic parameter, epicardial blood flow, is normal. Given that the latest developments make it possible to restore “normal” epicardial flow in more than 90% of the patients and that, given this is achieved, a significant number of patients still have unresolved ST segment and their myocardial perfusion is not restored under myocardial contrast echocardiography (MCE), interest has shifted from the

epicardial arteries towards myocardial perfusion. There are several methods to assess the state of coronary microcirculation and myocardial perfusion, from the simplest—analyzing a previously resolved ST-segment elevation in the electrocardiogram (ECG),⁷⁻¹⁹ to the more complex—positron emission tomography (PET).²⁰⁻²² The aim of this article is to review the findings obtained with coronary angiography^{18,23-29} to assess the quality of both epicardial and microvascular reperfusion.

RELEVANCE AND LIMITATIONS OF ASSESSING EPICARDIAL FLOW

Open Epicardial Artery: TIMI Flow Grading

The evaluation of blood flow in the epicardial coronary artery was formalized 20 years ago by the TIMI research group (Thrombolysis In Myocardial Infarction) with the so-called TIMI flow grades.¹ Table 1 shows the characteristics of each grade.

Many studies have demonstrated the correlation between this parameter and later events such as:

Correspondence: Dr. A. Pérez de Prado.
Sección de Cardiología Intervencionista. Servicio de Cardiología.
Hospital de León.
Altos de Nava, s/n. 24008 León. España.
E-mail: aperez@secardiologia.es

ABBREVIATIONS

cTFC: corrected TIMI frame count.
 MCE: myocardial contrast echocardiography.
 AMI: acute myocardial infarction.
 PCI: percutaneous coronary intervention.
 MBG: myocardial blush grade.
 NSTEMACS: non-ST segment elevation acute coronary syndrome.
 TIMI: Thrombolysis In Myocardial Infarction.
 TMPG: TIMI myocardial perfusion grade.

reinfarction,³⁰⁻³² mortality,^{2-6,33,34} free wall rupture,³⁵ development of ventricular aneurysm³⁶ or the appearance of arrhythmias.³⁷⁻⁴⁰ This correlation with prognosis, which was initially described for thrombolytic treatment in acute myocardial infarction (AMI), has also been extended to percutaneous coronary intervention therapy (PCI).³⁹⁻⁴⁴ This relationship has been shown to be so strong that TIMI 3 flow is normally used as a parameter to evaluate the

efficacy of different treatments instead of the relevant clinical events.⁴³⁻⁵²

This classification allows us to establish the superiority of TIMI 3 flow over other parameters, even over TIMI grade 2: 2 meta-analyses^{33,34} report that early mortality was significantly lower among patients with TIMI 3 flow at 90 min after fibrinolysis than in the group with TIMI 2 flow (3.7% vs 6.6%; odds ratio [OR] =0.55; 95% confidence interval [CI], 0.4-0.76) or than in group with TIMI 0 or TIMI 1 flows (9.2%; OR=0.38; 95% CI, 0.29-0.5). With the development of reperency therapy using PCI, the use of these predictors has continued to prove their validity,⁴¹ although some studies point out that the difference in mortality between TIMI 2 and 3 grades might not be so marked nowadays with the use of invasive therapies that combine fibrinolytic drugs and PCI.²³ On the other hand, technical developments in the intervention field (e.g. stenting,^{53,54} thrombectomy devices,^{55,56} distal protection systems⁵⁷⁻⁶⁰) have not been associated universally with an improvement in TIMI flow.

Nevertheless, this grading system has some limitations:

1. The most relevant limitation is its subjectivity, which leads to important discrepancies,⁶¹ even when

TABLE 1. Epicardial Flow and Myocardial Perfusion Grading Systems

Grade	Definition
Epicardial blood flow: TIMI flow grades (TFG)	
0	Absence of anterograde flow after the occlusion point
1	The contrast agent passes through the occluded area, without opacifying the entire length of the artery by the end of the injection
2	The contrast agent opacifies the entire artery, but is remarkably slower in the non-culprit arteries or in the area proximal to the occluded section of the artery. A later subclassification distinguishes between grade 2a (slow filling, within 5 heart beats), grade 2b (slow filling in more than 5 heart beats) and grade 2c (normal filling, slow washout)
3	Normal anterograde flow and contrast clearance, similar to those in non-culprit arteries or proximal to the occluded section of the artery
4	Anterograde flow and clearance of contrast is faster than in non-culprit arteries
Microvascular flow: TIMI myocardial perfusion grades (TMPG)	
0	Absence or minimum blush of the myocardium in the distribution section of the culprit artery
1	Persistent myocardial blush; the contrast agent enters the microvasculature, but it does not normally pass to the venous phase: "persistent stain" is detected at the beginning of the next injection (≥ 30 s)
2	Delayed blush and washout of the myocardium: the myocardial stain is evident (maximum level or minimum decline in intensity) by the end of the injection (3 heart beats for washout)
3	Normal blush: entry and exit of the contrast agent from the microvasculature at normal speed (total or high washout of the dye within 3 heart beats)
Microvascular flow: myocardial blush grades (MBG)	
0	Absence of myocardial blush or "persistent stain," indicative of the contrast exiting the extravascular space
1	Minimal myocardial blush
2	Moderate myocardial blush, of smaller intensity than in the reference area supplied by the non-culprit ipsilateral or contralateral artery
3	"Normal" myocardial blush, similar to the reference area

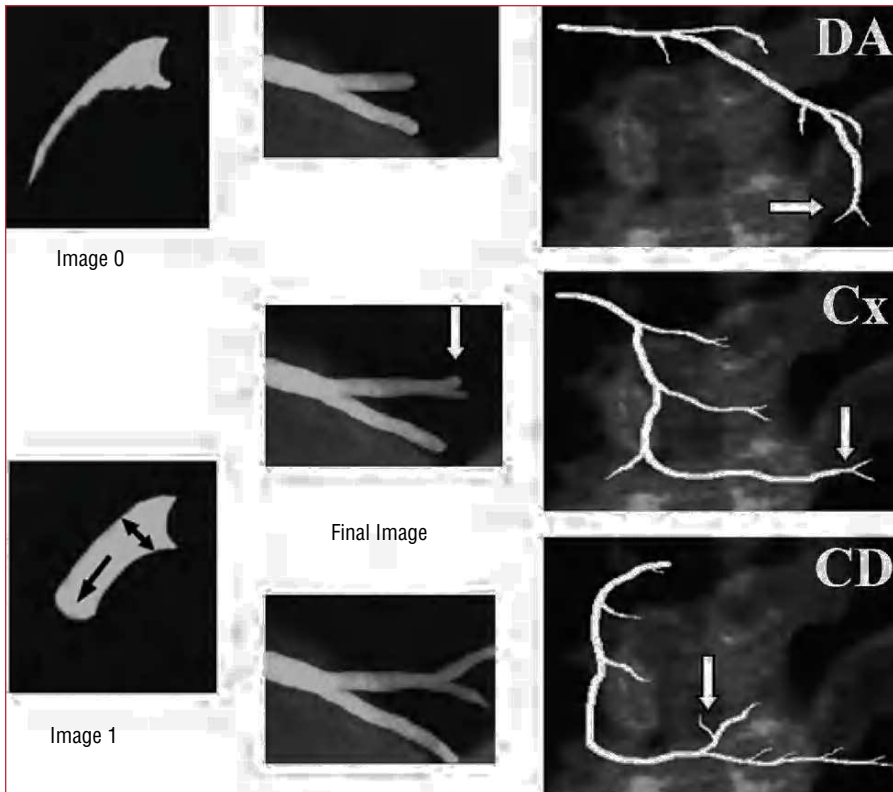


Figure 1. Calculating TIMI frame counts. The first counting frame (frame 1) is the image where the contrast advances and fills at least 70% of the diameter of the arterial ostium. The last frame (final frame) is the image where the contrast begins to fill the final landmark. Distal bifurcations of the 3 epicardial arteries are shown. CD indicates right coronary artery; Cx, circumflex artery; DA, left anterior descending coronary artery.

the analyzes assessment is performed by core laboratories with wide experience.^{62,63}

2. The filling time of the left anterior descending coronary artery (LAD) is higher than in other arteries, because this is normally the longest artery. Given that the filling of this artery can be simultaneously compared with the filling of the circumflex artery, the tendency to assign a TIMI grade 2 flow is much greater than with the right coronary artery (RCA).⁶⁴

3. The TIMI group itself has modified (without much acceptance) the grading system to distinguish up to 3 different subgroups in TIMI 2⁶⁵ (Table 1). These changes include factors such as washout speed that will be later discussed.

4. Finally, we cannot discard the presence of factors that could significantly modify grading, such as the pressure and phase within the cardiac cycle at which the contrast injection is administered, the heart rate and blood pressure of the patient, the use of vasodilators, etc. The impact of these factors is discussed in the next section.

Open Epicardial Artery: Quantification. Corrected TIMI Frame Count

In the light of the potential limitations of the TIMI flow grading system, new evaluation systems have been developed that more deeply characterize flow and improve the reproducibility of results: the

corrected TIMI frame count (cTFC) system developed by Gibson et al⁶⁴ is the most widely validated. Basically, it quantifies the TIMI flow grade by measuring the time it takes the contrast agent to fill the entire length of the epicardial artery. In order to standardize the criteria, several distal bifurcations were defined to serve as “final landmarks”: the “whale’s tail” at the apex of the LAD, the longest total distance along which dye travels in the circumflex system and yet passes through the culprit lesion, and the first branch of the posterolateral artery in the right coronary artery (Figure 1). The difference in the number of frames between the last one and the first (where the contrast agent fills at least 70% of the arterial ostium and starts to move in an anterograde direction) constitutes the TIMI frame count.

Some of the methodological aspects of this system are outlined as follows:

1. As described,⁶⁴ the length of the LAD is 1.7 times greater than the circumflex and the right coronary arteries. Thus, a correction factor was introduced in the TFC system when analyzing the LAD: the corrected TIMI frame count (cTFC) is the result of the absolute difference divided by the correction factor, 1.7.

2. All the values initially published as “frame counts” referred to the video format standard in the United States, NTSC: 30 frames per second. In order

TABLE 2. Values of the Corrected TIMI Frame Count (by Number of Frames)

Recording Speed	Normal Values (Healthy Volunteers)	TIMI 3 ⁶⁴ Flow (After Infarction)	TIMI 4 ⁶⁶ Flow (After Infarction)
30 frames/s	<21	<40	<14
25 frames/s	<18	<33	<12
12.5 frames/s	<9	<17	<6
Seconds	<0.7	<1.3	<0.5

to adapt these values to the European system (PAL), they have to be converted or else use a standard measuring unit: time in seconds. Table 2 shows the most relevant values and their equivalence.

3. The original definition of this parameter includes defining the cTFC value =100 when the coronary artery is totally occluded. This leads to a distribution of values that does not follow a normal distribution, which entails using nonparametric statistical tests to analyze the results.

4. Implementing this method in practice is more complex than simple subjective assessment of flow because it takes longer, which is a very significant restriction in the context of acute patients.

This parameter has been correlated with the onset of major events, such as early mortality after fibrinolysis.^{23,66,67} This relationship is kept even when the analysis is restricted to patients with TIMI 3 flow: the patients with cTFC values less than 14 frames (which was defined as “TIMI 4 flow”^{64,66}) presented a hospital mortality of 0%, compared to 2.7% in the group with cTFC between 14 and 40 frames (TIMI 3 flow) or to 6.4% in those with > 40 frames ($P=.003$).⁶⁶ The relationship of cTFC to later prognosis has been demonstrated in other contexts, such as in primary angioplasty after infarction⁶⁸⁻⁷² and in non-ST-segment elevation acute coronary syndrome (NSTEMI).⁷³

The correlation with independent methods of coronary functioning assessment (e.g. coronary flow reserve assessed by Doppler guidewire^{74,75} or fractional flow reserve [FFR]⁷⁶) has also been demonstrated. In complete contrast, some studies report no correlation between cTFC and coronary flow reserve parameters as measured by Doppler guidewire^{77,78} or even with early mortality.⁷⁹ However, these studies assessed the flow in a limited number of patients after PCI and not at baseline. Thus, it is reasonable not to find a correlation between the baseline flow assessed by this method and the hyperemic flow analyzed via Doppler guidewire.

This method has obvious advantages over the qualitative assessment of epicardial flow:

1. Given the quantitative character of the parameter, high reproducibility has been demonstrated.^{62,63,80}

2. This is an easy method that does not require special equipment and can be performed immediately after capturing angiographic images.

3. The cut-off points shown in Table 2 allow us to classify unclear epicardial flows.

Nevertheless, the method presents certain limitations as it has been found that some factors can significantly change the values calculated:

1. Heart rate. An increase of 20 heart beats/min shortens the count by 5 frames.⁸⁰

2. Using nitrates increases the count by 6 frames.⁸⁰

3. Injecting during the protodiastolic period reduces the count by 3-6 frames.⁸⁰

4. When the LAD is the culprit artery of the infarction: in such cases the count is higher than in the other arteries by 8 frames, even after correcting for length and adjusting for other variables.⁸¹

It has not been demonstrated whether the calculation is affected by patient-dependent factors (e.g. age, sex, body size, blood pressure, or cardiovascular risk factors⁸²) or by procedure-dependent factors (injection pressure⁸³ or type of contrast agent⁸⁴).

Taking this method as a basis, another assessment system has been developed, not only for the epicardial blood flow, but also for microcirculation flow—the assessment of the coronary blood flow reserve by analyzing the relationship of cTFC at baseline and cTFC after the administration of intracoronary^{74,85} or intravenous⁸⁶ adenosine. This parameter has been correlated with Doppler guidewire analysis,^{74,86} although other studies have not confirmed this.⁷⁷

ASSESSMENT OF MYOCARDIAL PERFUSION AND MICROCIRCULATION

Open Microvasculature: Assessment. Myocardial Blush

Since the classic descriptions of reperfusion injury and no reflow events were presented,⁸⁷ the attempts to assess the state of myocardial perfusion after an infarction have increased. The resolution of the ST-segment⁷⁻¹⁹ is the simplest and most reproducible analysis. Another method widely used is the MCE,⁸⁸⁻⁹³ which, apart from being a non-invasive method, can be quantified. In both cases, the results have been correlated with the appearance of subsequent events.^{7-10,14,16,26,88-90,93-98}

With the increasing implementation of PCI as the treatment of choice for AMI, the availability of an early angiography is quite frequent and this has permitted the development of the myocardial blush

TABLE 3. Treatment of Suboptimal Myocardial Reperfusion

Drug/Method	Result	Study
Verapamil	Positive	Small studies ^{109,110}
Nicorandil	Positive	Small studies ^{111,112}
Cariporide (Na ⁺ /H ⁺ pump inhibitor)	Negative	GUARDIAN Study ¹¹³
Intracoronary adenosine	Positive (subgroup)	AMISTAD II Study ¹¹⁴
Abciximab (glycoprotein IIb/IIIa inhibitors)	Positive	Several studies ^{52,57,115-120,136,140}
Pexelizumab (complement inhibitor)	Pending	APEX AMI Study ¹²¹
Hu23F2G (antibody anti-CD18)	Negative	HALT-MI Study ¹²²
Caldaret (Ca ⁺⁺ overload inhibitor)	Pending	EVOLVE Study ^{123,124}
Hypothermia	Non-conclusive	Preliminary studies ^{125,126}
Aqueous hyperoxygenation	Non-conclusive	Preliminary studies ¹²⁷
Thrombectomy devices	Positive	Small studies ^{55,56,128-132}
Distal protection devices	Negative	EMERALD Study ⁶⁰

concept: the penetration of iodized contrast medium into the capillaries yields a “ground-glass” angiographic image in the irrigated myocardial territory. Two different systems to assess myocardial blush have been suggested. The first one is a videodensitometric system proposed by van’t Hof et al²⁵ which analyzes the intensity of regional contrast (myocardial blush grade [MBG]) compared to the unaffected contralateral or ipsilateral territories. The other is a dynamic analysis system that assesses the intensity of myocardial contrast as well as the speed of entry and clearance of the contrast medium (TIMI myocardial perfusion grade [TMPG]). This was developed by Gibson et al.²⁴ Table 1 shows the four grades within each classification. Normal perfusion is identically graded in both systems: grade 3. Worse myocardial perfusion is shown by grades 0 in both systems; and major reperfusion injury (hemorrhagic transformation or persistent extravasation) are included in TMPG 1 and MBG 0, respectively. Cases of MBG 1 and 2 cannot really be extrapolated to the TMPG system, and so a subclassification has been proposed for these cases: the TMPG 0.5.⁹⁹ Thus, the 2 systems are not as different as they might initially appear. Figure 2 shows some examples of myocardial perfusion analysis.

Although the existence of these 2 systems may bring into question the validity of the method, the fact is that TMPG^{23,24} and MBG^{25,100,101} correlate with mortality (Figure 3), even when only TIMI grade 3 flow patients are included. The influence of these parameters has also been shown in the percentage of myocardium salvaged in respect to the risk area¹⁰² and the mortality in patients in shock¹⁰³ or on the relationship between mortality and the evolution time of AMI.¹⁰⁴⁻¹⁰⁶ On the other hand, a correlation has been found between these systems and other parameters independently related with prognosis after infarction, such as the analysis of coronary flow reserve with Doppler guidewire,^{107,108} MCE,^{26,95,96} analysis of

infarction size by single photon emission computed tomography (SPECT)¹⁸ or resolution of ST-segment elevation.^{18,28,101,108}

The assessment of myocardial blush has its own limitations:

1. The qualitative character of this parameter makes it inherently subjective. Thus, intra- and inter-observer consistency is limited, as described by one of the groups with the greatest experience.²⁵ In most studies, the analysis of MBG or TMPG is performed in central laboratories, and thus, the consistency with the assessments carried out by other observers might not be suitable.

2. Many of the studies carried out tend to group patients with MBG 2 and 3 or TMPG 2 and 3 into a single group with suitable perfusion. Given that it has been demonstrated that the prognosis of patients with TIMI 2 and TIMI 3 flow is not equivalent, this simplification of the system is most probably wrong.

3. Nevertheless, the fundamental limitation is not methodological, but refers to the unsolved challenge of treating suboptimal myocardial perfusion after coronary reperfusion. Table 3 sums up evidence published in this domain.

The correlation between the analysis of ST-segment resolution and myocardial blush is controversial because, although both have been related to clinical events, they do not always seem to match in every patient. What could be interpreted as a limitation tends to be assessed as another “anomalous” event, which are not uncommon in cardiology: the “electrical recovery” shown in the ECG is not always associated with integrity of the microvascular endothelium and recovery of perfusion, and vice versa. In fact, the 2 methods are complementary when the size of the infarction,¹⁸ or the angiography are analyzed. Their complementarity is also shown by the fact that the

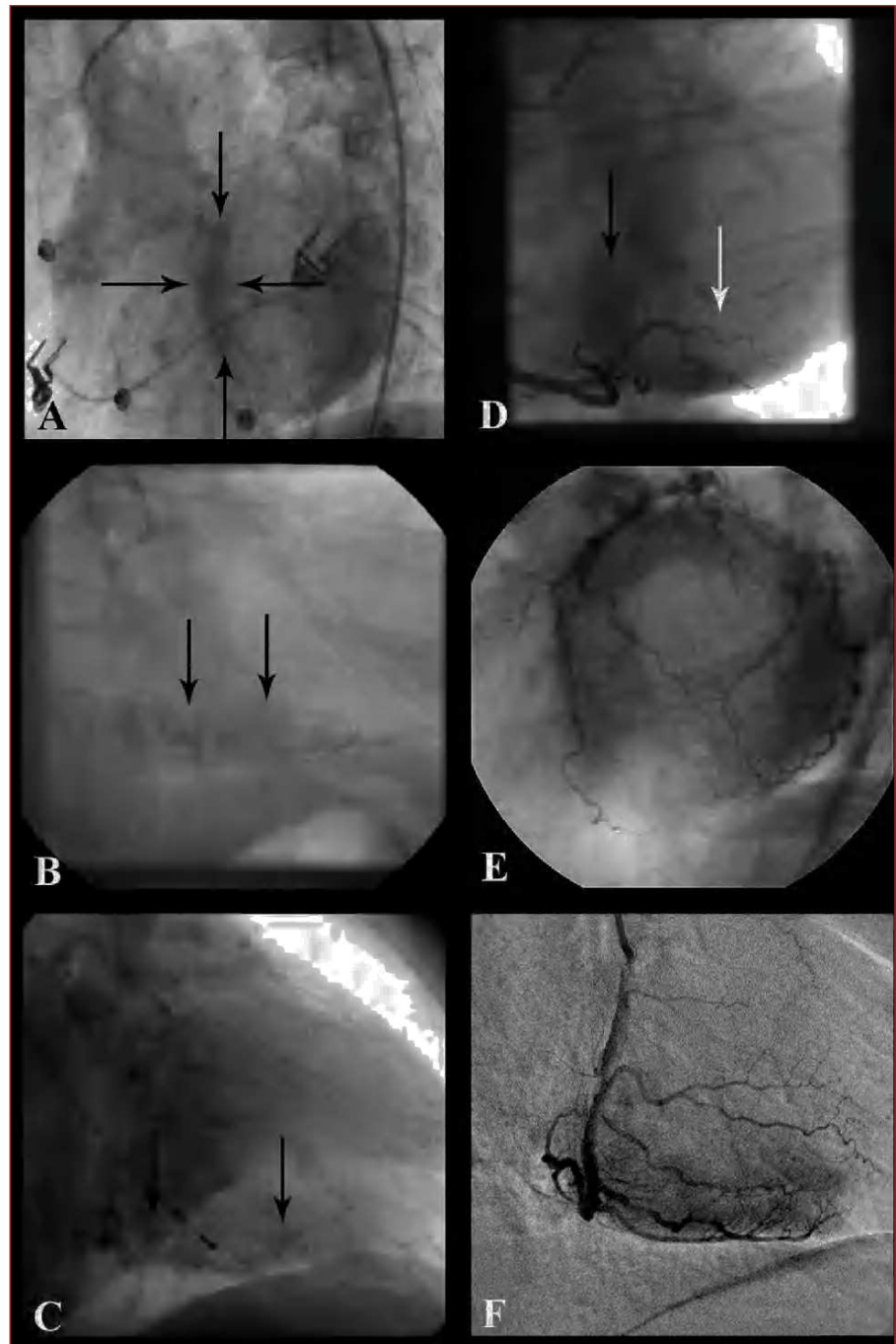


Figure 2. Examples of myocardial perfusion analysis. A: persistent stain of the septum (delimited by the arrows): grade 1 myocardial perfusion (TMPG), grade 0 myocardial blush (MBG) in LAD. B: persistent myocardial stain in the diaphragm territory: TMPG 1, MBG 0 grades in RCA. C: persistent capillary stain (small vessels are visualized) in RCA. D: lower intensity stain than in left coronary artery in the diaphragmatic territory (black arrow, TMPG 2 and MBG 2 grades) and barely present in posterolateral (white arrow, TMPG 0.5 and MBG 1 grades). E: normal myocardial stain (TMPG grade 3 and MBG grade 3) of left coronary artery: A donut-like image in LAO cranial projection. F: normal myocardial stain (TMPG 3 and MBG 3 grades) of RCA; example of digital subtraction (DSA).

group with a better prognosis after an infarction is the one where patients have both markers positive.¹³³⁻¹³⁵ There is ample literature available on the correlation between MCE and angiography,^{26,95-98,136} although a perfect correlation is not always found, even though both methods, at least theoretically, analyze myocardial perfusion. Bearing in mind that this is a dynamic event (some days after the infarction, many patients that initially did not show suitable myocardial blush may show a much better grade¹³⁵), the discrepancies may be due to the behavior of the

different contrast agent used—echographic contrast agents (microbubbles) always remain in the intravascular space, whereas radiological contrast media (and paramagnetic contrast used in magnetic resonance) often present extravascular passage, subsequently returning to the bloodstream. Thus, some authors¹³⁷ argue that angiography or magnetic resonance do not actually assess myocardial perfusion, but rather capillary patency, the state of the endothelium, and the edema and interstitial hemorrhage i.e. reperfusion injury.

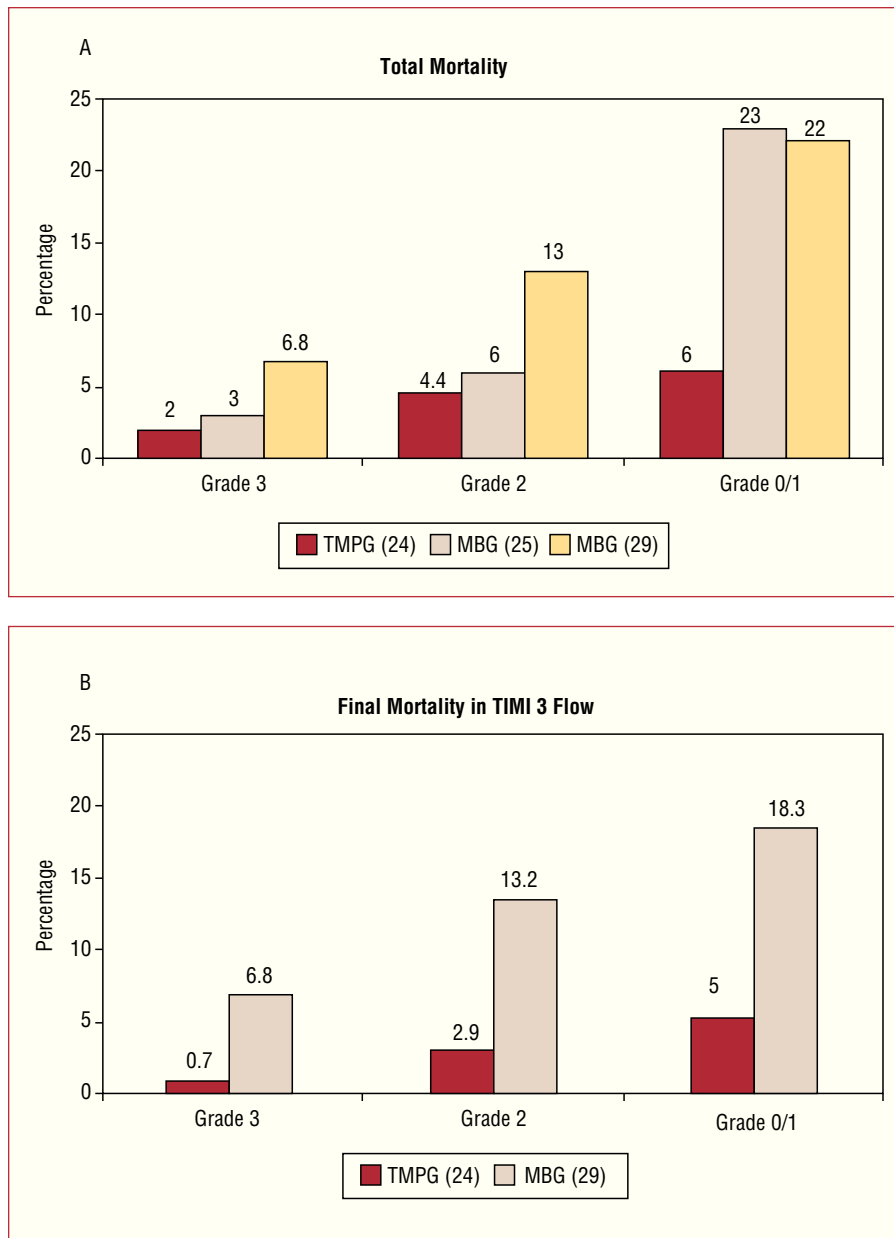


Figure 3. Mortality after AMI and myocardial blush grades. A: mortality rate in relation to the myocardial blush grade: at 1 month (Gibson et al²⁴), in the longer term (follow-up 1.9±1.7 years [van't Hof et al²⁵] and after 1 year [Stone et al²⁹]). B: mortality in relation to the myocardial blush grade in the patients with TIMI 3 flow in the culprit artery: at 1 month (Gibson et al²⁴) and after 1 year (Stone et al²⁹). TMPG: TIMI myocardial perfusion grade; MBG: myocardial blush grade.

Open Microvasculature: Quantification. Future Development

Myocardial perfusion assessed by angiography is analyzed by using several quantitative methods:

1. Methods based on digital subtraction angiography (DSA),^{85,138,139} widely used in vascular radiology, but little used in coronary angiography, may facilitate the quantification of the opacified area (in theory, this is “equivalent” to areas quantified in MCE), blush intensity (“MBG quantification”)^{107,140} or the speed at which the blush appears or disappears (“TMPG quantification”).¹³⁸ For DSA to be more applicable, several studies are working on the development of

techniques, such as moving mask, to attempt to neutralize the movements inherent to the heart.

2. A quantification system, based on cTFC has been suggested. This quantifies the number of frames between the entrance of the contrast agent into the myocardium and the peak blush intensity: the TIMI myocardial frame count. This count is significantly greater in patients with AMI with ST-segment elevation than in patients with NSTEMI/ACS¹⁴¹.

3. Our group has developed a quantification system known as the Coronary Clearance Frame Count (CCFC) with good correlation with TMPG¹⁴² grades. Defined as “the inverse of cTFC,” it counts the difference in frames between the moment in which the

contrast disappears from the arterial ostium and when it begins to disappear from the distal bifurcation described in the cTFC system. Although its potential clinical relevance has not been established yet, it shows correlation with myocardial perfusion TMPG grade 2 or 3, creating a cut-off point (45 images) that makes it possible to differentiate the better perfusion grades.

cTFC Analysis and Myocardial Blush. Practical Considerations

Both the quantitative analysis of epicardial blood flow (cTFC) and microvasculature flow can be carried out online with current digital equipment, or offline with software for image review. Nevertheless, if the imaging conditions are not optimal, the interpretation and later analysis may be biased. Thus, some standard recommendations are made:

1. Imaging field: 23 cm. Not magnifying the image enables recording the whole length of the artery without the need for panning. This is particularly important for the correct analysis of myocardial blush, especially when DSA is used. The quality of current DSA images (fixed mask) is also highly dependant on maintaining apnea during the recording.

2. Imaging speed: ideally, 25 frames/s. Nevertheless, cTFC can be calculated at any recording speed, and subsequently it can be expressed in seconds or adjusted to the recommended speed.

3. Recording time: up to the appearance of contrast in the venous phase. This is very relevant for the TMPG analysis system. In this case, it is also particularly important to leave at least 30 s between one injection and the following one, and not to record immediately after contrast tests (it may incorrectly assign TMPG 1 values).

4. Selective projections:

a) Analysis of cTFC. Recording images in PA or RAO projection (0°-30°) is recommended with caudal angulation (20°-30°) for the left coronary artery and in LAO projection (45°-60°) for the right coronary artery.

b) Blush analysis: the recommended projections differ from the previous ones, especially in the left coronary artery, where perfusion territories may be seen as overlapping. Thus, LAO projection (45°-60°) is recommended with cranial angulation (20°-30°), which makes it possible to see a donut-like image, or a left lateral projection (90°) in the case of the left coronary artery; for the right coronary artery, an LAO projection is recommended (45°-60°) with or without cranial angulation or RAO (30°).

From a practical point of view, in our center we systematically analyze myocardial perfusion data from

angiographies (according to both the TMPG and the MBG system) in all cases of angioplasty within the context of AMI and in other cases of intervention with no reflow events or slow final blood flow, reserving cTFC and CCFC for cases with difficult-to-classify epicardial blood flow or perfusion. In all these cases, the information obtained is always complemented by electrocardiographic analysis of ST-segment resolution.

CONCLUSIONS

Coronary angiography offers relevant but simple and easy to interpret information, not only on the state of the epicardial coronary circulation (TIMI flow in the epicardial artery and its quantification, TIMI frame count), but also on the state of microvascular circulation (myocardial blush grades: TIMI myocardial perfusion and myocardial blush grades). These data allow us to reliably assess the patient's prognosis. The development of a quantitative variant of these techniques could improve their predictive power.

REFERENCES

1. The Thrombolysis in Myocardial Infarction (TIMI) trial. Phase I findings. TIMI Study Group. *N Engl J Med.* 1985;312:932-6.
2. The effects of tissue plasminogen activator, streptokinase, or both on coronary-artery patency, ventricular function, and survival after acute myocardial infarction. The GUSTO Angiographic Investigators. *N Engl J Med.* 1993;329:1615-22.
3. Anderson JL, Karagounis LA, Becker LC, Sorensen SG, Menlove RL. TIMI perfusion grade 3 but not grade 2 results in improved outcome after thrombolysis for myocardial infarction. Ventriculographic, enzymatic, and electrocardiographic evidence from the TEAM-3 Study. *Circulation.* 1993;87:1829-39.
4. Karagounis L, Sorensen SG, Menlove RL, Moreno F, Anderson JL. Does thrombolysis in myocardial infarction (TIMI) perfusion grade 2 represent a mostly patent artery or a mostly occluded artery? Enzymatic and electrocardiographic evidence from the TEAM-2 study. Second Multicenter Thrombolysis Trial of Eminase in Acute Myocardial Infarction. *J Am Coll Cardiol.* 1992;19:1-10.
5. Simes RJ, Topol EJ, Holmes DR Jr, White HD, Rutsch WR, Vahanian A, et al. Link between the angiographic substudy and mortality outcomes in a large randomized trial of myocardial reperfusion. Importance of early and complete infarct artery reperfusion. GUSTO-I Investigators. *Circulation.* 1995;91:1923-8.
6. Vogt A, Von Essen R, Tebbe U, Feuerer W, Appel KF, Neuhaus KL. Impact of early perfusion status of the infarct-related artery on short-term mortality after thrombolysis for acute myocardial infarction: retrospective analysis of four German multicenter studies. *J Am Coll Cardiol.* 1993;21:1391-5.
7. Clemmensen P, Ohman EM, Sevilla DC, Peck S, Wagner NB, Quigley PS, et al. Changes in standard electrocardiographic ST-segment elevation predictive of successful reperfusion in acute myocardial infarction. *Am J Cardiol.* 1990;66:1407-11.
8. Saran RK, Been M, Furniss SS, Hawkins T, Reid DS. Reduction in ST segment elevation after thrombolysis predicts either coronary reperfusion or preservation of left ventricular function. *Br Heart J.* 1990;64:113-7.

9. Hohnloser SH, Zabel M, Kasper W, Meinertz T, Just H. Assessment of coronary artery patency after thrombolytic therapy: accurate prediction utilizing the combined analysis of three noninvasive markers. *J Am Coll Cardiol.* 1991;18:44-9.
10. Kondo M, Tamura K, Tanio H, Shimono Y. Is ST segment re-elevation associated with reperfusion an indicator of marked myocardial damage after thrombolysis? *J Am Coll Cardiol.* 1993;21:62-7.
11. Krucoff MW, Croll MA, Pope JE, Granger CB, O'Connor CM, Sigmon KN, et al. Continuous 12-lead ST-segment recovery analysis in the TAMI 7 study. Performance of a noninvasive method for real-time detection of failed myocardial reperfusion. *Circulation.* 1993;88:437-46.
12. Shah PK, Cercek B, Lew AS, Ganz W. Angiographic validation of bedside markers of reperfusion. *J Am Coll Cardiol.* 1993;21:55-61.
13. Clemmensen P, Ohman EM, Sevilla DC, Skelton T, Wagner NB, Quigley PS, et al. Impact of infarct artery patency on the relationship between electrocardiographic and ventriculographic evidence of acute myocardial ischaemia. *Eur Heart J.* 1994;15:1356-61.
14. Buszman P, Szafranek A, Kalarus Z, Gasior M. Use of changes in ST segment elevation for prediction of infarct artery recanalization in acute myocardial infarction. *Eur Heart J.* 1995;16:1207-14.
15. Klootwijk P, Langer A, Meij S, Green C, Veldkamp RF, Ross AM, et al. Non-invasive prediction of reperfusion and coronary artery patency by continuous ST segment monitoring in the GUSTO-I trial. *Eur Heart J.* 1996;17:689-98.
16. de Lemos JA. ST-segment resolution as a marker of epicardial and myocardial reperfusion after thrombolysis: insights from the TIMI 14 and in TIME-II trials. *J Electrocardiol.* 2000;33 Suppl:67-72.
17. Ophuis AJ, Bar FW, Vermeer F, Janssen W, Doevendans PA, Haest RJ, et al. Angiographic assessment of prospectively determined non-invasive reperfusion indices in acute myocardial infarction. *Heart.* 2000;84:164-70.
18. Angeja BG, Gunda M, Murphy SA, Sobel BE, Rundle AC, Syed M, et al. TIMI myocardial perfusion grade and ST segment resolution: association with infarct size as assessed by single photon emission computed tomography imaging. *Circulation.* 2002;105:282-5.
19. García Barsotti MA, Corbalan Herreros R, Nazzari Nazal C, Marchant Diaz E, Castro Galvez P, Pérez Pérez O, et al. Valor pronóstico de marcadores no invasivos de reperfusión coronaria frente a flujo TIMI 3 en pacientes tratados con angioplastia primaria. *Rev Esp Cardiol.* 2004;57:524-30.
20. Koszegi Z, Maes A, Piessens J, van de Werf F, Mortelmans L. Segmental comparison between coronary angiography and positron emission tomography reveals low predictive value of epicardial flow for viability. *Eur Heart J.* 1998;19:959-67.
21. Maes A, Mortelmans L, Nuyts J, Bormans G, Herregods MC, Bijnens B, et al. Importance of flow/metabolism studies in predicting late recovery of function following reperfusion in patients with acute myocardial infarction. *Eur Heart J.* 1997;18:954-62.
22. Maes A, van de Werf F, Nuyts J, Bormans G, Desmet W, Mortelmans L. Impaired myocardial tissue perfusion early after successful thrombolysis. Impact on myocardial flow, metabolism, and function at late follow-up. *Circulation.* 1995;92:2072-8.
23. Gibson CM, Cannon CP, Murphy SA, Marble SJ, Barron HV, Braunwald E. Relationship of the TIMI myocardial perfusion grades, flow grades, frame count, and percutaneous coronary intervention to long-term outcomes after thrombolytic administration in acute myocardial infarction. *Circulation.* 2002;105:1909-13.
24. Gibson CM, Cannon CP, Murphy SA, Ryan KA, Mesley R, Marble SJ, et al. Relationship of TIMI myocardial perfusion grade to mortality after administration of thrombolytic drugs. *Circulation.* 2000;101:125-30.
25. van't Hof AW, Liem A, Suryapranata H, Hoorntje JC, de Boer MJ, Zijlstra F. Angiographic assessment of myocardial reperfusion in patients treated with primary angioplasty for acute myocardial infarction: myocardial blush grade. *Zwolle Myocardial Infarction Study Group. Circulation.* 1998;97:2302-6.
26. Lepper W, Sieswerda GT, Vanoverschelde JL, Franke A, de Cock CC, Kamp O, et al. Predictive value of markers of myocardial reperfusion in acute myocardial infarction for follow-up left ventricular function. *Am J Cardiol.* 2001;88:1358-63.
27. Henriques JP, Zijlstra F, Ottervanger JP, de Boer MJ, van't Hof AW, Hoorntje JC, et al. Incidence and clinical significance of distal embolization during primary angioplasty for acute myocardial infarction. *Eur Heart J.* 2002;23:1112-7.
28. Poli A, Fetiveau R, Vandoni P, del Rosso G, d'Urbano M, Seveso G, et al. Integrated analysis of myocardial blush and ST-segment elevation recovery after successful primary angioplasty: real-time grading of microvascular reperfusion and prediction of early and late recovery of left ventricular function. *Circulation.* 2002;106:313-8.
29. Stone GW, Peterson MA, Lansky AJ, Dangas G, Mehran R, Leon MB. Impact of normalized myocardial perfusion after successful angioplasty in acute myocardial infarction. *J Am Coll Cardiol.* 2002;39:591-7.
30. Relik-van Wely L, Visser RF, van der Pol JM, Bartholomeus I, Couvee JE, Drost H, et al. Angiographically assessed coronary arterial patency and reocclusion in patients with acute myocardial infarction treated with anistreplase: results of the anistreplase reocclusion multicenter study (ARMS). *Am J Cardiol.* 1991;68:296-300.
31. Gibson CM, Cannon CP, Piana RN, Breall JA, Sharaf B, Flatley M, et al. Angiographic predictors of reocclusion after thrombolysis: results from the Thrombolysis in Myocardial Infarction (TIMI) 4 trial. *J Am Coll Cardiol.* 1995;25:582-9.
32. Hudson MP, Granger CB, Topol EJ, Pieper KS, Armstrong PW, Barbash GI, et al. Early reinfarction after fibrinolysis: experience from the global utilization of streptokinase and tissue plasminogen activator (alteplase) for occluded coronary arteries (GUSTO I) and global use of strategies to open occluded coronary arteries (GUSTO III) trials. *Circulation.* 2001;104:1229-35.
33. Anderson JL, Karagounis LA, Califf RM. Metaanalysis of five reported studies on the relation of early coronary patency grades with mortality and outcomes after acute myocardial infarction. *Am J Cardiol.* 1996;78:1-8.
34. Fath-Ordoubadi F, Huehns TY, Al-Mohammad A, Beatt KJ. Significance of the Thrombolysis in Myocardial Infarction scoring system in assessing infarct-related artery reperfusion and mortality rates after acute myocardial infarction. *Am Heart J.* 1997;134:62-8.
35. Sugiura T, Nagahama Y, Nakamura S, Kudo Y, Yamasaki F, Iwasaka T. Left ventricular free wall rupture after reperfusion therapy for acute myocardial infarction. *Am J Cardiol.* 2003;92:282-4.
36. Tikiz H, Balbay Y, Atak R, Terzi T, Genc Y, Kutuk E. The effect of thrombolytic therapy on left ventricular aneurysm formation in acute myocardial infarction: relationship to successful reperfusion and vessel patency. *Clin Cardiol.* 2001;24:656-62.
37. Crenshaw BS, Ward SR, Granger CB, Stebbins AL, Topol EJ, Califf RM. Atrial fibrillation in the setting of acute myocardial infarction: the GUSTO-I experience. *Global Utilization of Streptokinase and TPA for Occluded Coronary Arteries. J Am Coll Cardiol.* 1997;30:406-13.
38. Ehara S, Naruko T, Itoh A, Otsuka M, Yamashita H, Haze K. Does reperfusion therapy reduce complications in acute inferior myocardial infarction? *J Cardiol.* 2000;35:113-9.
39. Yang HS, Lee CW, Hong MK, Lee JH, Nam GB, Choi KJ, et al. Residual flow to the infarct zone against lethal ventricular tachyarrhythmias during the acute phase of myocardial infarction. *Clin Cardiol.* 2003;26:373-6.
40. Mehta RH, Harjai KJ, Grines L, Stone GW, Boura J, Cox D, et al. Sustained ventricular tachycardia or fibrillation in the cardiac catheterization laboratory among patients receiving primary per-

- cutaneous coronary intervention: incidence, predictors, and outcomes. *J Am Coll Cardiol.* 2004;43:1765-72.
41. Laster SB, O'Keefe JH Jr, Gibbons RJ. Incidence and importance of thrombolysis in myocardial infarction grade 3 flow after primary percutaneous transluminal coronary angioplasty for acute myocardial infarction. *Am J Cardiol.* 1996;78:623-6.
 42. López-Palop R, Carrillo P, Lozano I, Pinar E, Cortes R, Saura D, et al. Intervalos de tiempo transcurridos en la realización de la angioplastia primaria: desde el inicio de los síntomas hasta la restauración del flujo. *Rev Esp Cardiol.* 2002;55:597-606.
 43. Weaver WD, Simes RJ, Betriu A, Grines CL, Zijlstra F, García E, et al. Comparison of primary coronary angioplasty and intravenous thrombolytic therapy for acute myocardial infarction: a quantitative review. *JAMA.* 1997;278:2093-8.
 44. Keeley EC, Boura JA, Grines CL. Primary angioplasty versus intravenous thrombolytic therapy for acute myocardial infarction: a quantitative review of 23 randomised trials. *Lancet.* 2003;361:13-20.
 45. Cannon CP. Importance of TIMI 3 flow. *Circulation.* 2001;104:624-6.
 46. Trial of abciximab with and without low-dose reteplase for acute myocardial infarction. Strategies for Patency Enhancement in the Emergency Department (SPEED) Group. *Circulation.* 2000;101:2788-94.
 47. Gibson CM, Jennings LK, Murphy SA, Lorenz DP, Giugliano RP, Harrington RA, et al. Association between platelet receptor occupancy after eptifibatid (integrilin) therapy and patency, myocardial perfusion, and ST-segment resolution among patients with ST-segment-elevation myocardial infarction: an INTEGRITI (Integrilin and Tenecteplase in Acute Myocardial Infarction) Substudy. *Circulation.* 2004;110:679-84.
 48. Antman EM, Louwerenburg HW, Baars HF, Westdorp JC, Hamer B, Bassand JP, et al. Enoxaparin as adjunctive antithrombin therapy for ST-elevation myocardial infarction: results of the ENTIRE-Thrombolysis in Myocardial Infarction (TIMI) 23 Trial. *Circulation.* 2002;105:1642-9.
 49. Brener SJ, Zeymer U, Adgey AA, Vrobel TR, Ellis SG, Neuhaus KL, et al. Eptifibatid and low-dose tissue plasminogen activator in acute myocardial infarction: the integrilin and low-dose thrombolysis in acute myocardial infarction (INTRO AMI) trial. *J Am Coll Cardiol.* 2002;39:377-86.
 50. Antman EM, Giugliano RP, Gibson CM, McCabe CH, Coussement P, Kleiman NS, et al. Abciximab facilitates the rate and extent of thrombolysis: results of the thrombolysis in myocardial infarction (TIMI) 14 trial. The TIMI 14 Investigators. *Circulation.* 1999;99:2720-32.
 51. Antman EM, Gibson CM, De Lemos JA, Giugliano RP, McCabe CH, Coussement P, et al. Combination reperfusion therapy with abciximab and reduced dose reteplase: results from TIMI 14. The Thrombolysis in Myocardial Infarction (TIMI) 14 Investigators. *Eur Heart J.* 2000;21:1944-53.
 52. de Lemos JA, Antman EM, Gibson CM, McCabe CH, Giugliano RP, Murphy SA, et al. Abciximab improves both epicardial flow and myocardial reperfusion in ST-elevation myocardial infarction. Observations from the TIMI 14 trial. *Circulation.* 2000;101:239-43.
 53. Stone GW, Brodie BR, Griffin JJ, Morice MC, Costantini C, St Goar FG, et al. Prospective, multicenter study of the safety and feasibility of primary stenting in acute myocardial infarction: in-hospital and 30-day results of the PAMI stent pilot trial. Primary Angioplasty in Myocardial Infarction Stent Pilot Trial Investigators. *J Am Coll Cardiol.* 1998;31:23-30.
 54. Grines CL, Cox DA, Stone GW, García E, Mattos LA, Giambartolomei A, et al. Coronary angioplasty with or without stent implantation for acute myocardial infarction. Stent Primary Angioplasty in Myocardial Infarction Study Group. *N Engl J Med.* 1999;341:1949-56.
 55. Napodano M, Pasquetto G, Sacca S, Cernetti C, Scarabeo V, Pascotto P, et al. Intracoronary thrombectomy improves myocardial reperfusion in patients undergoing direct angioplasty for acute myocardial infarction. *J Am Coll Cardiol.* 2003;42:1395-402.
 56. Beran G, Lang I, Schreiber W, Denk S, Stefanelli T, Syeda B, et al. Intracoronary thrombectomy with the X-sizer catheter system improves epicardial flow and accelerates ST-segment resolution in patients with acute coronary syndrome: a prospective, randomized, controlled study. *Circulation.* 2002;105:2355-60.
 57. Mak KH, Phay C, Wong A, Kwok V, Tan KS, Lau KW, et al. Comparison between glycoprotein IIb/IIIa blockade and distal protection device for the restoration of myocardial perfusion during percutaneous coronary intervention for acute myocardial infarction. *J Invasive Cardiol.* 2004;16:694-8.
 58. Nakamura T, Kubo N, Seki Y, Ikeda N, Ishida T, Funayama H, et al. Effects of a distal protection device during primary stenting in patients with acute anterior myocardial infarction. *Circ J.* 2004;68:763-8.
 59. Taguchi I, Kanaya T, Toi T, Abe S, Sugimura H, Hoshi T, et al. Comparison of the effects of a distal embolic protection device and an aspiration catheter during percutaneous coronary intervention in patients with acute myocardial infarction. *Circ J.* 2005;69:49-54.
 60. Stone GW, Webb J, Cox DA, Brodie BR, Qureshi M, Kalynych A, et al. Distal microcirculatory protection during percutaneous coronary intervention in acute ST-segment elevation myocardial infarction: a randomized controlled trial. *JAMA.* 2005;293:1063-72.
 61. Hackworthy RA, Sorensen SG, Fitzpatrick PG, Barry WH, Menlove RL, Rothbard RL, et al. Dependence of assessment of coronary artery reperfusion during acute myocardial infarction on angiographic criteria and interobserver variability. *Am J Cardiol.* 1988;62:538-42.
 62. Gibson CM, Ryan KA, Kelley M, Rizzo MJ, Mesley R, Murphy S, et al. Methodologic drift in the assessment of TIMI grade 3 flow and its implications with respect to the reporting of angiographic trial results. The TIMI Study Group. *Am Heart J.* 1999;137:1179-84.
 63. Moliterno DJ, Antman EM, Ohman EM, Miller J, Marble SJ, Murphy SA, et al. Concordance between core labs in trial results using TIMI flow grades and frame counts. *Circulation.* 2000;102 Suppl II:II-590.
 64. Gibson CM, Cannon CP, Daley WL, Dodge JT Jr, Alexander B Jr, Marble SJ, et al. TIMI frame count: a quantitative method of assessing coronary artery flow. *Circulation.* 1996;93:879-88.
 65. Ellis SG, Topol EJ, George BS, Kereiakes DJ, Debowey D, Sigmon KN, et al. Recurrent ischemia without warning. Analysis of risk factors for in-hospital ischemic events following successful thrombolysis with intravenous tissue plasminogen activator. *Circulation.* 1989;80:1159-65.
 66. Gibson CM, Murphy SA, Rizzo MJ, Ryan KA, Marble SJ, McCabe CH, et al. Relationship between TIMI frame count and clinical outcomes after thrombolytic administration. *Circulation.* 1999;99:1945-50.
 67. French JK, Hyde TA, Straznicki IT, Andrews J, Lund M, Amos DJ, et al. Relationship between corrected TIMI frame counts at three weeks and late survival after myocardial infarction. *J Am Coll Cardiol.* 2000;35:1516-24.
 68. Edep ME, Guarneri EM, Teirstein PS, Phillips PS, Brown DL. Differences in TIMI frame count following successful reperfusion with stenting or percutaneous transluminal coronary angioplasty for acute myocardial infarction. *Am J Cardiol.* 1999;83:1326-9.
 69. Hamada S, Nishiue T, Nakamura S, Sugiura T, Kamihata H, Miyoshi H, et al. TIMI frame count immediately after primary coronary angioplasty as a predictor of functional recovery in patients with TIMI 3 reperfused acute myocardial infarction. *J Am Coll Cardiol.* 2001;38:666-71.
 70. Vrachatis AD, Alpert MA, Georgoulas VP, Nikas DJ, Petropoulou EN, Lazaros GI, et al. Comparative efficacy of primary angioplasty with stent implantation and thrombolysis in restoring

- basal coronary artery flow in acute ST segment elevation myocardial infarction: quantitative assessment using the corrected TIMI frame count. *Angiology*. 2001;52:161-6.
71. Bickel C, Rupprecht HJ, Maimaitiming A, Welk I, Blankenberg S, Krummenauer F, et al. The superiority of TIMI frame count in detecting coronary flow changes after coronary stenting compared to TIMI Flow Classification. *J Invasive Cardiol*. 2002;14:590-6.
 72. Capozzolo C, Piscione F, de Luca G, Cioppa A, Mazzarotto P, Leosco D, et al. Direct coronary stenting: effect on coronary blood flow, immediate and late clinical results. *Catheter Cardiovasc Interv*. 2001;53:464-73.
 73. Gibson CM, Dotani MI, Murphy SA, Marble SJ, Dauterman KW, Michaels AD, et al. Correlates of coronary blood flow before and after percutaneous coronary intervention and their relationship to angiographic and clinical outcomes in the RESTORE trial. Randomized Efficacy Study of Tirofiban for Outcomes and REstenosis. *Am Heart J*. 2002;144:130-5.
 74. Manginas A, Gatzov P, Chasikidis C, Voudris V, Pavlides G, Cokkinos DV. Estimation of coronary flow reserve using the Thrombolysis In Myocardial Infarction (TIMI) frame count method. *Am J Cardiol*. 1999;83:1562-5, A7.
 75. Barcin C, Denktas AE, Garratt KN, Higano ST, Holmes DR Jr, Lerman A. Relation of Thrombolysis in Myocardial Infarction (TIMI) frame count to coronary flow parameters. *Am J Cardiol*. 2003;91:466-9.
 76. Umman B, Nisanci Y, Sezer M, Umman S, Yilmaz E, Oflaz H, et al. The relationship between corrected TIMI frame count and myocardial fractional flow reserve. *J Invasive Cardiol*. 2002;14:125-8.
 77. Chugh SK, Koppel J, Scott M, Shewchuk L, Goodhart D, Bonan R, et al. Coronary flow velocity reserve does not correlate with TIMI frame count in patients undergoing non-emergency percutaneous coronary intervention. *J Am Coll Cardiol*. 2004;44:778-82.
 78. Ohara Y, Hiasa Y, Takahashi T, Yamaguchi K, Ogura R, Ogata T, et al. Relation between the TIMI frame count and the degree of microvascular injury after primary coronary angioplasty in patients with acute anterior myocardial infarction. *Heart*. 2005;91:64-7.
 79. Bhatt DL, Ellis SG, Ivanc TB, Crowe T, Balazs E, Debowey D, et al. Corrected TIMI frame count does not predict 30-day adverse outcomes after reperfusion therapy for acute myocardial infarction. *Am Heart J*. 1999;138:785-90.
 80. Abaci A, Oguzhan A, Eryol NK, Ergin A. Effect of potential confounding factors on the thrombolysis in myocardial infarction (TIMI) trial frame count and its reproducibility. *Circulation*. 1999;100:2219-23.
 81. Gibson CM, Murphy S, Menown IB, Sequeira RF, Greene R, van de Werf F, et al. Determinants of coronary blood flow after thrombolytic administration. TIMI Study Group. *Thrombolysis in Myocardial Infarction*. *J Am Coll Cardiol*. 1999;34:1403-12.
 82. Faile BA, Guzzo JA, Tate DA, Nichols TC, Smith SC, Dehmer GJ. Effect of sex, hemodynamics, body size, and other clinical variables on the corrected thrombolysis in myocardial infarction frame count used as an assessment of coronary blood flow. *Am Heart J*. 2000;140:308-14.
 83. Dodge JT Jr, Rizzo M, Nykiel M, Altmann J, Hobkirk K, Brennan M, et al. Impact of injection rate on the Thrombolysis in Myocardial Infarction (TIMI) trial frame count. *Am J Cardiol*. 1998;81:1268-70.
 84. Gibson CM, Kirtane AJ, Murphy SA, Marble SJ, de Lemos JA, Antman EM, et al. Impact of contrast agent type (ionic versus nonionic) used for coronary angiography on angiographic, electrocardiographic, and clinical outcomes following thrombolytic administration in acute myocardial infarction. *Catheter Cardiovasc Interv*. 2001;53:6-11.
 85. Gibson CM, Cohen DJ, Cohen EA, Lui HK, Murphy SA, Marble SJ, et al. Effect of eptifibatide on coronary flow reserve following coronary stent implantation (an ESPRIT substudy). Enhanced Suppression of the Platelet IIb/IIIa Receptor with Integrilin Therapy. *Am J Cardiol*. 2001;87:1293-5.
 86. Stoel MG, Zijlstra F, Visser CA. Frame count reserve. *Circulation*. 2003;107:3034-9.
 87. Kloner RA, Rude RE, Carlson N, Maroko PR, DeBoer LW, Braunwald E. Ultrastructural evidence of microvascular damage and myocardial cell injury after coronary artery occlusion: which comes first? *Circulation*. 1980;62:945-52.
 88. Ito H, Tomooka T, Sakai N, Yu H, Higashino Y, Fujii K, et al. Lack of myocardial perfusion immediately after successful thrombolysis. A predictor of poor recovery of left ventricular function in anterior myocardial infarction. *Circulation*. 1992;85:1699-705.
 89. Ito H, Iwakura K, Oh H, Masuyama T, Hori M, Higashino Y, et al. Temporal changes in myocardial perfusion patterns in patients with reperfused anterior wall myocardial infarction: their relation to myocardial viability. *Circulation*. 1995;91:656-62.
 90. Ito H, Maruyama A, Iwakura K, Takiuchi S, Masuyama T, Hori M, et al. Clinical implications of the «no reflow» phenomenon. A predictor of complications and left ventricular remodeling in reperfused anterior wall myocardial infarction. *Circulation*. 1996;93:223-8.
 91. Ito H, Okamura A, Iwakura K, Masuyama T, Hori M, Takiuchi S, et al. Myocardial perfusion patterns related to thrombolysis in myocardial infarction perfusion grades after coronary angioplasty in patients with acute anterior wall myocardial infarction. *Circulation*. 1996;93:1993-9.
 92. Asanuma T, Tanabe K, Ochiai K, Yoshitomi H, Nakamura K, Murakami Y, et al. Relationship between progressive microvascular damage and intramyocardial hemorrhage in patients with reperfused anterior myocardial infarction: myocardial contrast echocardiographic study. *Circulation*. 1997;96:448-53.
 93. Ito H, Iwakura K. Assessing the relation between coronary reflow and myocardial reflow. *Am J Cardiol*. 1998;81:G8-12.
 94. Ragosta M, Camarano G, Kaul S, Powers ER, Sarembock IJ, Gimble LW. Microvascular integrity indicates myocardial viability in patients with recent myocardial infarction. New insights using myocardial contrast echocardiography. *Circulation*. 1994;89:2562-9.
 95. Greaves K, Dixon SR, Fejka M, O'Neill WW, Redwood SR, Marber MS, et al. Myocardial contrast echocardiography is superior to other known modalities for assessing myocardial reperfusion after acute myocardial infarction. *Heart*. 2003;89:139-44.
 96. Bodi V, Sanchis J, López-Lereu MP, Llacer A, Pellicer M, Losada A, et al. Estudio de perfusión en pacientes postinfarto mediante ecografía miocárdica con inyección de contraste intracoronario. Implicaciones y relación con la angiografía y la resonancia magnética. *Rev Esp Cardiol*. 2004;57:20-8.
 97. Bolognese L, Ducci K, Angioli P, Falsini G, Liistro F, Baldassarre S, et al. Elevations in troponin I after percutaneous coronary interventions are associated with abnormal tissue-level perfusion in high-risk patients with non-ST-segment-elevation acute coronary syndromes. *Circulation*. 2004;110:1592-7.
 98. Olszowska M, Tracz W, Przewlocki T, Kostkiewicz M, Podolec P, Zalewski J, et al. The value of myocardial contrast echocardiography compared with SPECT in detecting myocardial perfusion abnormalities in patients with anterior acute myocardial infarction. *Kardiol Pol*. 2004;60:27-38.
 99. Gibson CM, Schomig A. Coronary and myocardial angiography: angiographic assessment of both epicardial and myocardial perfusion. *Circulation*. 2004;109:3096-105.
 100. Henriques JP, Zijlstra F, van't Hof AW, de Boer MJ, Dambrink JH, Gosselink M, et al. Angiographic assessment of reperfusion in acute myocardial infarction by myocardial blush grade. *Circulation*. 2003;107:2115-9.
 101. Haager PK, Christott P, Heussen N, Lepper W, Hanrath P, Hoffmann R. Prediction of clinical outcome after mechanical revascularization in acute myocardial infarction by markers of myocardial reperfusion. *J Am Coll Cardiol*. 2003;41:532-8.

102. Dibra A, Mehilli J, Dirschinger J, Pache J, Neverve J, Schwaiger M, et al. Thrombolysis in myocardial infarction myocardial perfusion grade in angiography correlates with myocardial salvage in patients with acute myocardial infarction treated with stenting or thrombolysis. *J Am Coll Cardiol.* 2003;41:925-9.
103. Tarantini G, Ramondo A, Isabella G, Favero L, Maddalena F, Razzolini R, et al. Pressure response to vasopressors and mortality after direct angioplasty for cardiogenic shock. *Int J Cardiol.* 2004;94:197-202.
104. de Luca G, van't Hof AW, De Boer MJ, Ottervanger JP, Hoorntje JC, Gosselink AT, et al. Time-to-treatment significantly affects the extent of ST-segment resolution and myocardial blush in patients with acute myocardial infarction treated by primary angioplasty. *Eur Heart J.* 2004;25:1009-13.
105. de Luca G, Suryapranata H, Zijlstra F, van't Hof AW, Hoorntje JC, Gosselink AT, et al. Symptom-onset-to-balloon time and mortality in patients with acute myocardial infarction treated by primary angioplasty. *J Am Coll Cardiol.* 2003;42:991-7.
106. Gibson CM, Murphy SA, Kirtane AJ, Giugliano RP, Cannon CP, Antman EM, et al. Association of duration of symptoms at presentation with angiographic and clinical outcomes after fibrinolytic therapy in patients with ST-segment elevation myocardial infarction. *J Am Coll Cardiol.* 2004;44:980-7.
107. Destro G, Marino P, Barbieri E, Zorzi A, Brighetti G, Maines M, et al. Postinfarctional remodeling: increased dye intensity in the myocardial risk area after angioplasty of infarct-related coronary artery is associated with reduction of ventricular volumes. *J Am Coll Cardiol.* 2001;37:1239-45.
108. Hoffmann R, Haager P, Lepper W, Franke A, Hanrath P. Relation of coronary flow pattern to myocardial blush grade in patients with first acute myocardial infarction. *Heart.* 2003;89:1147-51.
109. Taniyama Y, Ito H, Iwakura K, Masuyama T, Hori M, Takiuchi S, et al. Beneficial effect of intracoronary verapamil on microvascular and myocardial salvage in patients with acute myocardial infarction. *J Am Coll Cardiol.* 1997;30:1193-9.
110. Werner GS, Lang K, Kuehnert H, Figulla HR. Intracoronary verapamil for reversal of no-reflow during coronary angioplasty for acute myocardial infarction. *Catheter Cardiovasc Interv.* 2002;57:444-51.
111. Lim SY, Bae EH, Jeong MH, Kang DG, Lee YS, Kim KH, et al. Effect of combined intracoronary adenosine and nicorandil on no-reflow phenomenon during percutaneous coronary intervention. *Circ J.* 2004;68:928-32.
112. Ikeda N, Yasu T, Kubo N, Hashimoto S, Tsuruya Y, Fujii M, et al. Nicorandil versus isosorbide dinitrate as adjunctive treatment to direct balloon angioplasty in acute myocardial infarction. *Heart.* 2004;90:181-5.
113. Theroux P, Chaitman BR, Danchin N, Erhardt L, Meinertz T, Schroeder JS, et al. Inhibition of the sodium-hydrogen exchanger with cariporida to prevent myocardial infarction in high-risk ischemic situations. Main results of the GUARDIAN trial. Guard during ischemia against necrosis (GUARDIAN) Investigators. *Circulation.* 2000;102:3032-8.
114. Ross AM, Gibbons RJ, Stone GW, Kloner RA, Alexander RW. A randomized, double-blinded, placebo-controlled multicenter trial of adenosine as an adjunct to reperfusion in the treatment of acute myocardial infarction (AMISTAD-II). *J Am Coll Cardiol.* 2005;45:1775-80.
115. Dudek D, Bartus S, Zmudka K, Kuta M, Legutko J, Wizimirski M, et al. Assessment of myocardial reperfusion in patients with acute myocardial infarction treated with combination of fibrinolysis and IIb/IIIa platelet inhibitor. *Przegl Lek.* 2002;59:1-6.
116. Kaul U, Gupta RK, Haridas KK, Ramesh SS, Sethi KK, Singh B, et al. Platelet glycoprotein IIb/IIIa inhibition using eptifibatide with primary coronary stenting for acute myocardial infarction: a 30-day follow-up study. *Catheter Cardiovasc Interv.* 2002;57:497-503.
117. Stoupakis G, Orlando J, Kalia H, Skurnick J, Saric M, Arora R. Preservation of myocardial microcirculation during mechanical reperfusion for myocardial ischemia with either abciximab or eptifibatide. *J Invasive Cardiol.* 2003;15:476-80.
118. Bellandi F, Maioli M, Gallopin M, Toso A, Dabizzi RP. Increase of myocardial salvage and left ventricular function recovery with intracoronary abciximab downstream of the coronary occlusion in patients with acute myocardial infarction treated with primary coronary intervention. *Catheter Cardiovasc Interv.* 2004;62:186-92.
119. Costantini CO, Stone GW, Mehran R, Aymong E, Grines CL, Cox DA, et al. Frequency, correlates, and clinical implications of myocardial perfusion after primary angioplasty and stenting, with and without glycoprotein IIb/IIIa inhibition, in acute myocardial infarction. *J Am Coll Cardiol.* 2004;44:305-12.
120. Pérez de Prado A, Fernández-Vázquez F, Cuellas JC, Alonso-Orcajo N, Carbonell R, Pascual C, et al. Association between level of platelet inhibition after early use of abciximab and myocardial reperfusion in ST elevation acute myocardial infarction treated by primary percutaneous coronary intervention. *Am J Cardiol.* En prensa 2006.
121. Armstrong PW, Adams PX, Al-Khalidi HR, Hamm C, Holmes D, O'Neill W, et al. Assessment of Pexelizumab in Acute Myocardial Infarction (APEX AMI): a multicenter, randomized, double-blind, parallel-group, placebo-controlled study of pexelizumab in patients with acute myocardial infarction undergoing primary percutaneous coronary intervention. *Am Heart J.* 2005;149:402-7.
122. Faxon DP, Gibbons RJ, Chronos NA, Gurbel PA, Sheehan F. The effect of blockade of the CD11/CD18 integrin receptor on infarct size in patients with acute myocardial infarction treated with direct angioplasty: the results of the HALT-MI study. *J Am Coll Cardiol.* 2002;40:1199-204.
123. Satoh N, Kitada Y. Cardioprotective effect of MCC-135 is associated with inhibition of Ca²⁺ overload in ischemic/reperfused hearts. *Eur J Pharmacol.* 2004;499:179-87.
124. Jang IK, Pettigrew V, Picard MH, Kowey PR, Demmel V, Zile MR, et al. A randomized, double-blind, placebo-controlled study of the safety and efficacy of intravenous MCC-135 as an adjunct to primary percutaneous coronary intervention in patients with acute myocardial infarction: rationale and design of the evaluation of MCC-135 for left ventricular salvage in acute MI (EVOLVE) study. *J Thromb Thrombolysis.* 2005;20:147-53.
125. Dixon SR, Whitbourn RJ, Dae MW, Grube E, Sherman W, Schaer GL, et al. Induction of mild systemic hypothermia with endovascular cooling during primary percutaneous coronary intervention for acute myocardial infarction. *J Am Coll Cardiol.* 2002;40:1928-34.
126. Ly HQ, Denault A, Dupuis J, Vadeboncoeur A, Harel F, Arsenault A, et al. A pilot study: the Noninvasive Surface Cooling Thermoregulatory System for Mild Hypothermia Induction in Acute Myocardial Infarction (the NICAMI Study). *Am Heart J.* 2005;150:933.
127. Dixon SR, Bartorelli AL, Marcovitz PA, Spears R, David S, Grinberg I, et al. Initial experience with hyperoxemic reperfusion after primary angioplasty for acute myocardial infarction: results of a pilot study utilizing intracoronary aqueous oxygen therapy. *J Am Coll Cardiol.* 2002;39:387-92.
128. Kawaguchi R, Hoshizaki H, Oshima S, Hirathuji T, Adachi H, Toyama T, et al. Effectiveness of thrombectomy before stent implantation in acute myocardial infarction. *Circ J.* 2003;67:951-4.
129. Antonucci D, Valenti R, Migliorini A, Parodi G, Memisha G, Santoro GM, et al. Comparison of rheolytic thrombectomy before direct infarct artery stenting versus direct stenting alone in patients undergoing percutaneous coronary intervention for acute myocardial infarction. *Am J Cardiol.* 2004;93:1033-5.
130. Kondo H, Suzuki T, Fukutomi T, Suzuki S, Hayase M, Ito S, et al. Effects of percutaneous coronary arterial thrombectomy during acute myocardial infarction on left ventricular remodeling. *Am J Cardiol.* 2004;93:527-31.

131. Lefevre T, García E, Reimers B, Lang I, Di Mario C, Colombo A, et al. X-sizer for thrombectomy in acute myocardial infarction improves ST-segment resolution: results of the X-sizer in AMI for negligible embolization and optimal ST resolution (X AMINE ST) trial. *J Am Coll Cardiol.* 2005;46:246-52.
132. Lee MS, Singh V, Wilentz JR, Makkar RR. AngioJet thrombectomy. *J Invasive Cardiol.* 2004;16:587-91.
133. Angeja BG, Kermgard S, Chen MS, McKay M, Murphy SA, Antman EM, et al. The smoker's paradox: insights from the angiographic substudies of the TIMI trials. *J Thromb Thrombolysis.* 2002;13:133-9.
134. Sorajja P, Gersh BJ, Costantini C, McLaughlin MG, Zimetbaum P, Cox DA, et al. Combined prognostic utility of ST-segment recovery and myocardial blush after primary percutaneous coronary intervention in acute myocardial infarction. *Eur Heart J.* 2005;26:667-74.
135. Hoffmann R, Haager P, Arning J, Christott P, Radke P, Blindt R, et al. Usefulness of myocardial blush grade early and late after primary coronary angioplasty for acute myocardial infarction in predicting left ventricular function. *Am J Cardiol.* 2003;92:1015-9.
136. Petronio AS, Rovai D, Musumeci G, Baglini R, Nardi C, Limbruno U, et al. Effects of abciximab on microvascular integrity and left ventricular functional recovery in patients with acute infarction treated by primary coronary angioplasty. *Eur Heart J.* 2003;24:67-76.
137. Kaul S. Coronary angiography cannot be used to assess myocardial perfusion in patients undergoing reperfusion for acute myocardial infarction. *Heart.* 2001;86:483-4.
138. Gibson CM, de Lemos JA, Murphy SA, Marble SJ, Dauterman KW, Michaels A, et al. Methodologic and clinical validation of the TIMI myocardial perfusion grade in acute myocardial infarction. *J Thromb Thrombolysis.* 2002;14:233-7.
139. Murphy SA, Chen C, Gourlay SG, Gibbons RJ, Barron HV, Gibson CM. Impairment of myocardial perfusion in both culprit and nonculprit arteries in acute myocardial infarction: a LIMIT AMI substudy. *Am J Cardiol.* 2003;91:325-8.
140. Gyongyosi M, Domanovits H, Benzer W, Haugk M, Heinisch B, Sodeck G, et al. Use of abciximab prior to primary angioplasty in STEMI results in early recanalization of the infarct-related artery and improved myocardial tissue reperfusion - results of the Austrian multi-centre randomized ReoPro-BRIDGING Study. *Eur Heart J.* 2004;25:2125-33.
141. Wong GC, Frisch D, Murphy SA, Sabatine MS, Pai R, James D, et al. Time for contrast material to traverse the epicardial artery and the myocardium in ST-segment elevation acute myocardial infarction versus unstable angina pectoris/non-ST-elevation acute myocardial infarction. *Am J Cardiol.* 2003;91:1163-7.
142. de Prado AP, Fernández-Vázquez F, Carlos Cuellas-Ramon J, Iglesias-Garriz I. Coronary clearance frame count: a new index of microvascular perfusion. *J Thromb Thrombolysis.* 2005;19:97-100.