

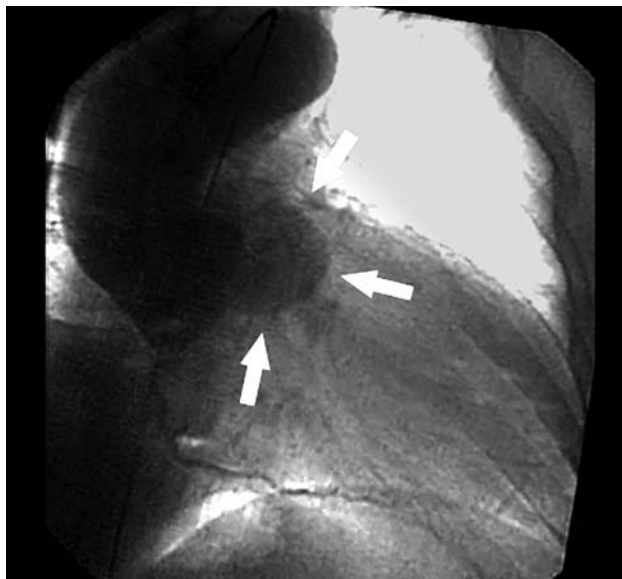

Figure 1.

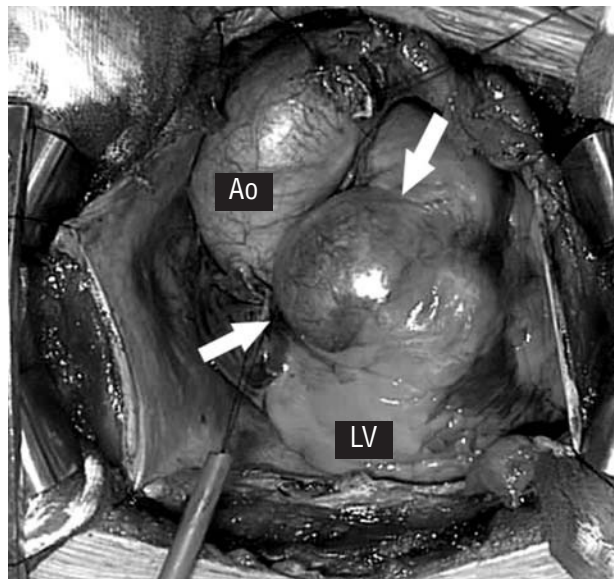


Figure 2.

Congenital Subaortic Diverticulum

A 52-year-old man with nonspecific precordial discomfort of 4-months' evolution underwent chest radiography, stress testing, and coronary angiography, with normal results on all tests. The aortogram showed a large diverticular cavity and severe aortic regurgitation (Figure 1). Echocardiography showed a weakly pulsatile cavity with no systolic contraction. No significant flow was detected toward the cavity. A sternotomy was performed and the diverticulum was visualized (Figure 2). The aorta was opened and a structurally anomalous bicuspid aortic valve was observed, as well as a small orifice in communication with the diverticular cavity between the 2 commissures and below the insertion point of the valves. The native aortic valve was extracted and the diverticulum was resected. The neck was obliterated with continuous sutures. The small hole that led to the cavity was closed with an autologous patch of pericardial tissue. A mechanical prosthesis was implanted at the aortic valve position. Pathological study demonstrated a diverticulum with fibrous tissue; no muscle tissue was observed.

Subannular aortic diverticulum is a congenital anomaly that can present as an isolated condition, but is usually associated with structural alterations of the aortic valve (eg, bicuspid valve, multiple perforations, or prolapse) that can cause regurgitation. On aortography, the differential diagnosis must be made with nonperforated congenital sinus of Valsalva aneurysm. Ventriculography is recommended when there is no aortic regurgitation. Noninvasive imaging techniques, such as transthoracic or transesophageal echocardiography, magnetic resonance, and multislice computed tomography can be useful for the differential diagnosis. Surgical resection is recommended because of the risk of common trunk compression, arrhythmias, spontaneous perforation, and endocarditis.

Josep M. Caralps,^a Vicens Martí,^b
and José Montiel^b

^aClínica Quirón, Barcelona, Spain

^bDepartamento de Cirugía Cardíaca y Cardiología,
Hospital de la Santa Creu i de Sant Pau, Barcelona, Spain