

**Table**  
Pericardial Synovial Sarcomas Reported

Publication date	1998–2016 (n = 38 cases)
Age	
Mean (range)	37 (13–70)
Sex	
Male	27 (72.9%)
Histology	
Monophasic spindle cell	17 (44.73%)
Monophasic epithelial	1 (2.63%)
Biphasic	9 (23.68%)
Poorly differentiated	2 (5.26%)
Not available	9 (23.68%)
Molecular analysis	
Available	23
Translocation (X;18)	22 (95.6%)
In remission for 12 mo	12 (31%)

To the authors' knowledge, few cases of pericardial synovial sarcomas have been reported in the English-language literature. A PubMed search of the term "pericardial synovial sarcoma" yielded only 54 hits in August, 2016. Checking these articles, as well as the articles cited within them, we found only 38 cases of synovial sarcoma originating in the pericardium (Table). We reviewed them for the epidemiology, clinical picture, therapeutic conduct, and prognosis of this neoplasm. There was male predominance, and a higher incidence in the fourth decade of life. Most of the sarcomas were monophasic (spindle cell) type and had a cytogenetic translocation. As is our case, the immunohistochemistry was predominately positive for vimentin, epithelial membrane antigen, and cytokeratin. All of them were treated with surgical excision when possible, with neoadjuvant treatment (chemotherapy and radiation) to reduce local recurrence rates, similar to the management in the case reported here. Complete or near total excision of the tumor was performed in a minority of the reported cases, so most patients had local recurrence or short survival times.

In conclusion, this report describes a case of synovial sarcoma of pericardial origin and an updated review of the literature. This sarcoma has poor prognosis, and a systematic approach to diagnosis and multidisciplinary management are crucial. The

histological characteristics of the tumor, the clinical course of the patient, and treatment response should be carefully analyzed in order to establish the optimal therapeutic strategies for treating such extremely rare conditions in the future.

Berta Vega Hernández,<sup>a,\*</sup> Roi Bangueses Quintana,<sup>a</sup>  
Rocío Díaz Méndez,<sup>b</sup> Íñigo Lozano Martínez-Luengas,<sup>a</sup>  
M. Victoria Folgueras Sánchez,<sup>c</sup> and Jacobo Silva Guisasaola<sup>b</sup>

<sup>a</sup>Servicio de Cardiología, Hospital Universitario de Cabueñes, Gijón, Asturias, Spain

<sup>b</sup>Servicio de Cirugía Cardíaca, Hospital Universitario Central de Asturias, Oviedo, Asturias, Spain

<sup>c</sup>Servicio de Anatomía Patológica, Hospital Universitario Central de Asturias, Oviedo, Asturias, Spain\* Corresponding author:

E-mail address: bertavegahernandez@gmail.com  
(B. Vega Hernández).

Available online 15 May 2017

## REFERENCES

- Patel J, Sheppard MN. Pathological study of primary cardiac and pericardial tumours in a specialist UK Centre: surgical and autopsy series. *Cardiovasc Pathol*. 2010;19:343–352.
- Burke AP, Virmani R. Tumors of the heart and great vessels. In: Rosai J, Sobin LH, eds. *Atlas of Tumor Pathology. Third series, fascicle 16*. Washington, DC: Armed Forces Institute of Pathology; 1996:1–91.
- Clark J, Rocques PJ, Crew AJ, et al. Identification of novel genes, SYT and SSX, involved in the t(X;18)(p11.2;q11.2) translocation found in human synovial sarcoma. *Nat Genet*. 1994;7:502–508.
- Sun B, Sun Y, Wang J, et al. The diagnostic value of SYT-SSX detected by reverse transcriptase-polymerase chain reaction (RT-PCR) and fluorescence in situ hybridization (FISH) for synovial sarcoma: a review and prospective study of 255 cases. *Cancer Sci*. 2008;99:1355–1361.
- O'Sullivan PJ, Harris AC, Munk PL. Radiological features of synovial cell sarcoma. *Br J Radiol*. 2008;81:346–356.
- Spurrell ELC, Fisher JM, Thomas IR, Judson IR. Prognostic factors in advanced synovial sarcoma: an analysis of 104 patients treated at the Royal Marsden Hospital. *Ann Oncol*. 2005;16:437–444.

<http://dx.doi.org/10.1016/j.rec.2017.04.014>  
1885-5857/

© 2017 Sociedad Española de Cardiología. Published by Elsevier España, S.L.U. All rights reserved.

## Comparison of the PI3K-AKT-mTOR Pathway Expression Profile in Tumoral Versus Nontumoral Tissue Samples From Heart Transplant Recipients



### Comparación del perfil de expresión de la vía PI3K-AKT-mTOR en muestras de tejido tumoral y no tumoral de pacientes sometidos a trasplante cardíaco

#### To the Editor,

In heart transplantation (HTx), one of the long-term limitations is the development of neoplasia; the main causal factors of this are viral infections and immunosuppressive therapy.<sup>1</sup> The proliferation signal inhibitors (PSIs) sirolimus and everolimus have been demonstrated to reduce the risk of cancer after transplant,<sup>2</sup> although the immunosuppression protocols used were associated with an increase in graft rejection. It is not currently known which tumors will respond to the antineoplastic action of PSIs and

therefore in which patients the benefits will outweigh the risks of rejection. One of the molecular pathways that is dysregulated in various tumor types is PI3K-AKT-mTOR, and this pathway is also one of the targets of PSIs.<sup>3</sup>

We compared the expression profile of several genes involved in the PI3K-AKT-mTOR pathway in tumor tissue and nontumor tissue from patients who had received a HTx, with the aim of identifying the genes with different expression that could be used as predictors of response to PSIs. We used samples of tumor and nontumor tissue from 16 patients who developed a neoplasm following HTx. These samples were taken from excess tissue obtained for clinical purposes, which was stored in the biobank of our hospital. The healthy tissue samples were taken from an unaffected area of the organ affected by the tumor. The RNA was acquired using a High Pure FFPET RNA Isolation Kit (Roche Diagnostics; Mannheim, Germany). DNA was obtained from the RNA via reverse transcription polymerase chain reaction using the RT<sup>2</sup> First Strand Kit (Qiagen; Maryland, USA). After an initial analysis of samples from 3 patients, evaluating 84 genes

**Table**  
Baseline Patient Characteristics

Patients, n	16
Age, y	68 [59-73]
Male sex	15 (93.8)
Type of heart disease prior to HTx	
Ischemic heart disease	10 (62.5)
Idiopathic DCM	3 (18.8)
Valvular heart disease	2 (12.5)
Other	1 (6.3)
Tumor site	
Prostate	5 (31.3)
Skin	3 (18.6)
Stomach	2 (12.5)
Bladder	2 (12.5)
Lung	2 (12.5)
Colon	1 (6.3)
Kidney	1 (6.3)
Treatment switched to PSI	10 (62.5)

DCM, dilated cardiomyopathy; HTx, heart transplant; PSI, proliferation signal inhibitor.

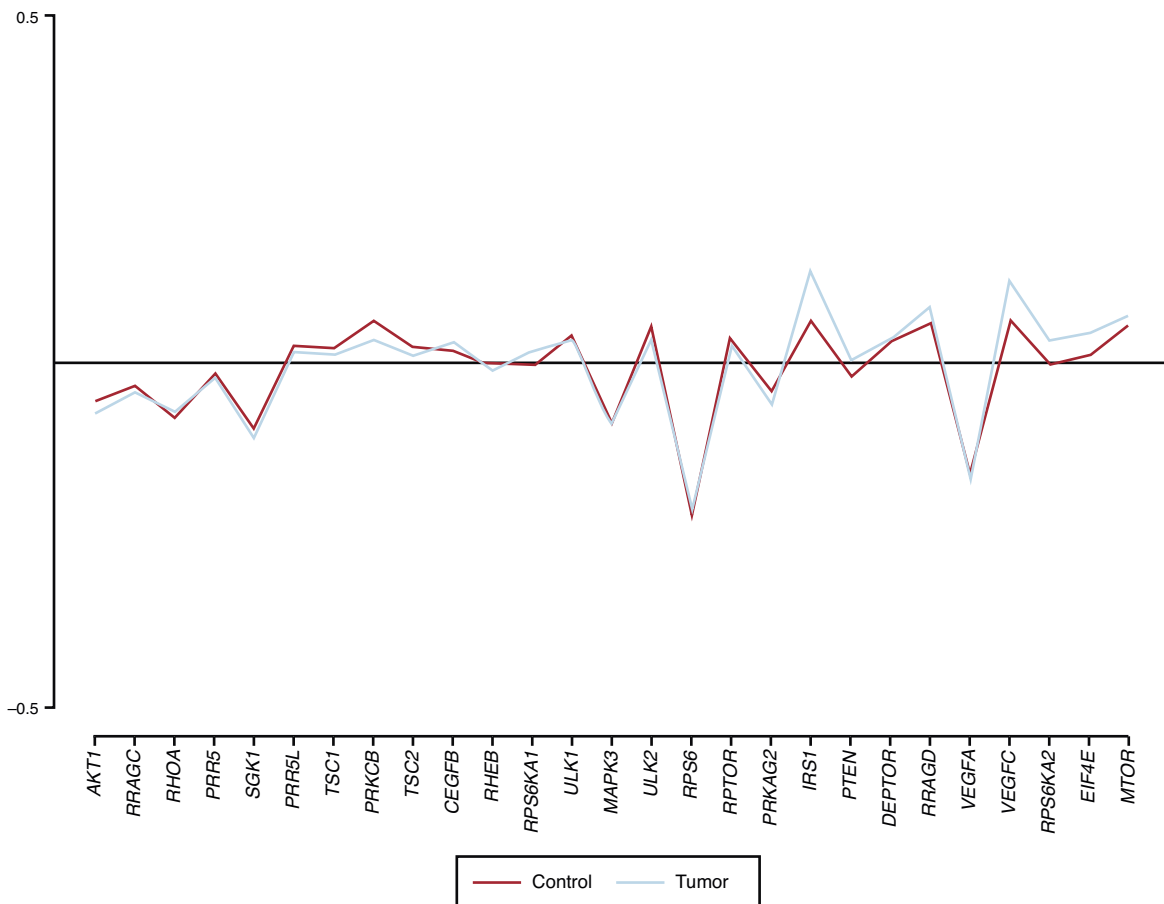
Unless otherwise indicated, data are expressed as median [interquartile grange] or no. (%).

involved in the PI3K-AKT-mTOR pathway, differential expression was detected in 34 genes. A systematic review of the available literature allowed us to conclude that only 27 had been demonstrated to be relevant, and these were therefore included

in our final analysis. The variable analyzed was the mean value of DNA for each gene, adjusted for the constitutive gene *HRPT1* (characterized by maintaining a constant level of expression in all the tissues of the same organism, according to the formula [mean value of tested gene-mean value of constitutive gene]/mean value of constitutive gene), expressed in tumor tissue compared with nontumor tissue. For this comparison, given the small sample size, the nonparametric Wilcoxon signed-rank test was used.

Sixteen patients were included in the study. The median age was 68 years [interquartile range, 59-73 years], and 93.8% were male. The most frequent reason for HTx was ischemic heart disease (62.5%) and the most prevalent tumor site was the prostate (31.3%). No patients were on treatment with a PSI before tumor diagnosis, but 10 patients (62.5%) were subsequently switched to receive one (Table). Only 1 gene (*VEGFC*) was observed to have an adjusted mean DNA value that was significantly higher in tumor tissue than in nontumor tissue ( $0.110 \pm 0.066$  vs  $0.066 \pm 0.087$ ;  $P = .01$ ). Two other genes had a tendency to increased expression in the tumor tissue, but this difference did not reach statistical significance (*IRS1*,  $P = .056$ ; *EIF4E*,  $P = .063$ ) (Figure).

This study, involving 16 patients who developed cancer after HTx, evaluated the hypothesis of a potential differential expression in tumor tissue but not in nontumor tissue of 27 genes involved in the PI3K-AKT-mTOR pathway. Only 1 of them (*VEGFC*) was statistically significantly overexpressed in the tumor tissue samples. The results of previous studies in nontransplant populations concur with this finding, and an increased expression of this gene has been found in various tumor types.<sup>4</sup> The protein coded by this gene has a key role in angiogenesis, a process essential for



**Figure.** Adjusted mean value of DNA for each gene expressed in tumor tissue but not in nontumor tissue. A statistically significant ( $P = .01$ ) overexpression of the *VEGFC* gene was observed in the tumor tissue.

tumor growth and metastasis.<sup>5</sup> One of the mechanisms by which PSIs exert their antineoplastic effect is by reducing VEGFC expression and reducing endothelial cell sensitivity to this factor.<sup>6</sup> The results of this study indicate that determination of the level of VEGFC gene expression in tumor tissue from patients who have developed cancer after HTx could help identify those with a potentially better response to the antineoplastic effects of PSIs, which would facilitate decision-making on the choice of immunosuppressive regimen to prescribe. More studies are needed to corroborate these findings.

#### Acknowledgments

The authors thank Zulaika Grille-Cancela, Paula Blanco-Canosa, and Lucía Moreda-Santamaría for their help on this project.

#### FUNDING

This study was performed with the help of a grant awarded by the Spanish Society of Cardiology in its 2013 annual call for basic research projects in cardiology. It was cofunded by the European Regional Development Fund (ERDF).

Natalia Suárez-Fuentetaja,<sup>a</sup> Gonzalo Barge-Caballero,<sup>a,b,c,\*</sup> Eduardo Barge-Caballero,<sup>a,b,c</sup> Jorge Pombo-Otero,<sup>d</sup> Nieves Domenech-García,<sup>a,e</sup> and María G. Crespo-Leiro<sup>a,b,c</sup>

<sup>a</sup>Instituto de Investigación Biomédica de A Coruña (INIBIC), A Coruña, Spain

<sup>b</sup>Unidad de Insuficiencia Cardíaca Avanzada y Trasplante Cardíaco, Servicio de Cardiología, Complejo Hospitalario Universitario A Coruña, A Coruña, Spain

<sup>c</sup>Centro de Investigación Biomédica en Red (CIBERCV), Instituto de Salud Carlos III, Madrid, Spain

<sup>d</sup>Servicio de Anatomía Patológica, Complejo Hospitalario Universitario A Coruña, A Coruña, Spain

<sup>e</sup>Bio BANCO, Complejo Hospitalario Universitario A Coruña, A Coruña, Spain

\*Corresponding author:

E-mail address: [gonzalo.barge.caballero@sergas.es](mailto:gonzalo.barge.caballero@sergas.es)

(G. Barge-Caballero).

Available online 21 June 2017

#### REFERENCES

1. Crespo-Leiro MG, Alonso-Pulpon L, Vazquez de Prada JA, et al. Malignancy after heart transplantation: incidence, prognosis and risk factors. *Am J Transplant.* 2008;8:1031–1039.
2. Kauffman HM, Cherikh WS, Cheng Y, et al. Maintenance immunosuppression with target-of-rapamycin inhibitors is associated with a reduced incidence of de novo malignancies. *Transplantation.* 2005;80:883–889.
3. Populo H, Lopes JM, Soares P. The mTOR signalling pathway in human cancer. *Int J Mol Sci.* 2012;13:1886–1918.
4. Meadows KL, Hurwitz HI. Anti-VEGF therapies in the clinic. *Cold Spring Harb Perspect Med.* 2012;2:1–27.
5. Granata S, Dalla Gassa A, Carraro A, et al. Siroliimus and everolimus pathway: reviewing candidate genes influencing their intracellular effects. *Int J Mol Sci.* 2016;17:1–26.
6. Trinh XB, Tjalma WA, Vermeulen PB, et al. The VEGF pathway and the AKT/mTOR/p70S6K1 signalling pathway in human epithelial ovarian cancer. *Br J Cancer.* 2009;100:971–978.

<http://dx.doi.org/10.1016/j.rec.2017.05.025>  
1885-5857/

© 2017 Sociedad Española de Cardiología. Published by Elsevier España, S.L.U. All rights reserved.

### Concomitant or Staged Transcatheter Treatment for Severe Combined Aortic and Mitral Valve Disease



#### Tratamiento percutáneo simultáneo o secuencial de la valvulopatía aórtica y mitral grave combinada

#### To the Editor,

Aortic stenosis (AS) and mitral regurgitation (MR) are the most prevalent valvular heart diseases in Western countries.<sup>1</sup> The rate of concomitant significant MR in patients with severe AS ranges between 2% and 33%.<sup>2</sup> Double-valve surgery has been associated with higher morbidity and mortality compared with isolated surgical aortic valve surgery, especially in elderly patients.<sup>3</sup> However, this approach remains the standard of care for patients with combined mitral-aortic valve disease.

Transcatheter aortic valve replacement (TAVR) and transcatheter mitral valve repair, particularly edge-to-edge repair with the MitraClip device (Abbott Vascular, Inc. Santa Clara, CA, United States) have emerged as a treatment option for patients deemed inoperable or at high surgical risk. The combination of the 2 transcatheter therapies would appear to be a viable approach for managing high-risk patients with concomitant AS and MR. This systematic review seeks to analyze the safety and feasibility of combined transcatheter mitral-aortic valve treatment.

A comprehensive, systematic review was performed of published data in the English language describing double-valve

(aortic and mitral) transcatheter therapy. A computerized search was conducted to identify all relevant studies from the PubMed, EMBASE, and Google Scholar databases using the following terms: “TAVR”, “TAVI”, “transcatheter/percutaneous aortic valve”, “transcatheter/percutaneous aortic valve replacement/implantation”, “transcatheter/percutaneous mitral valve repair”, “MitraClip”, and “transcatheter/percutaneous double-valve treatment/intervention”.

A total of 10 articles ([Table of the supplementary material](#)) describing 33 patients (mean age 79 ± 3 years, 69.7% male) were included. Baseline clinical characteristics and echocardiographic data are summarized in the [Table](#). All patients were considered to be inoperable or at high risk for surgery. The indication for transcatheter aortic valve replacement was predominantly severe native AS, whereas 4 (12.1%) patients underwent TAVR to treat a degenerated surgical bioprosthesis. Moderate-to-severe MR was present before TAVR in all but 1 patient, who had an iatrogenic mitral chord rupture during TAVR, resulting in severe MR.

The procedural details and in-hospital outcomes are described in [Table](#). Transcatheter mitral valve repair was performed using the MitraClip system in all patients. Transcatheter aortic valve replacement was performed before the MitraClip procedure in 29 patients (87.9%); 27 of them were discharged after TAVR and had the MitraClip procedure at a mean of 172 ± 344 days post-TAVR. In 3 patients (9.0%), both valves were treated during the same intervention. Only 1 patient (3.0%) underwent MitraClip implantation before the TAVR procedure. Mitral regurgitation was significantly